

Relationship of the Optic Nerve to the Posterior Paranasal Sinuses: A CT Anatomic Study

Mark C. DeLano, F. Y. Fun, and S. James Zinreich

PURPOSE: To delineate the relationship between the optic nerves and the posterior paranasal sinuses using CT data. **METHODS:** Direct coronal sinus CT scans of 150 consecutive patients with chronic inflammatory sinus disease were reviewed by two radiologists. Axial oblique reconstructions along the course of the optic nerve were obtained for the first 100 patients. The direct relationship between the optic nerve and the posterior ethmoid and sphenoidal sinuses was recorded, as were indentations into the sinus wall, course of the nerve through the sinus region, pneumatization of the anterior clinoid process, and bone dehiscence. **RESULTS:** The relationship of the optic nerve to the posterior paranasal sinus fell into one of four discrete categories, type 1 through type 4. All 300 nerves were intimately related to the sphenoidal sinus. A small minority (3%) were in contact with the posterior ethmoidal sinus. Only type 4 nerves had contact with the posterior ethmoid air cell. Type 1 nerves course adjacent to the sphenoid sinus without indentation of the wall (228 nerves, 76%). Type 2 nerves course adjacent to the sphenoidal sinus, causing indentation of the sinus wall (44 nerves, 15%). Type 3 nerves course through the sphenoid sinus (19 nerves, 6%). Type 4 nerves course immediately adjacent to the sphenoidal sinus and the posterior ethmoidal air cell (9 nerves, 3%). Bone dehiscence over the optic nerve was found in 24% of the nerves; 4% of the optic nerves in our study had an associated pneumatized anterior clinoid process and 77% of these had an associated dehiscence over the optic canal. **CONCLUSIONS:** In all our cases the course of the optic nerve was adjacent to the sphenoidal sinus. Only 3% were in contact with the posterior ethmoidal sinus. Anatomic configurations that predispose the optic nerve to injury include type 2 or 3 optic nerves, bone dehiscence over the nerve, and pneumatization of the anterior clinoid process. These configurations are common and should be routinely sought out so that devastating complications from sinus surgery can be avoided.

Index terms: Nerves, anatomy; Nerves, optic (II); Paranasal sinuses, computed tomography

AJNR Am J Neuroradiol 17:669-675, April 1996

The use of functional endoscopic sinus surgical procedures has increased steadily since their introduction in 1984. An estimated 171 000 endoscopic sinus surgeries were performed to treat chronic inflammation of the nasal cavity and paranasal sinus disease in 1990, and approximately 250 000 such procedures were performed in 1994. Concurrently, an increase in the frequency of serious complica-

tions, including death and intracranial and orbital injuries, was noted. Of these, the most common are injuries of the orbit and optic nerve. Thus, a clear understanding of the relationship between the paranasal sinuses and the course of the optic nerve is critical in planning and performing surgery involving the posterior ethmoidal and sphenoidal sinuses.

The enormous variability in the anatomy of the sphenoidal and posterior ethmoidal sinuses is well documented (1-7). Accurate evaluation of these structures is possible with preoperative computed tomography (CT) of the sinuses. With the introduction of the nasal endoscope and expanded surgical procedures, knowledge of this anatomy takes on added significance.

In our radiologic evaluation of the paranasal sinuses of patients with chronic inflammatory

Received February 8, 1995; accepted after revision October 3.

From the Department of Radiology and Radiologic Science, Johns Hopkins Medical Institutions, Baltimore, Md.

Address reprint requests to S. James Zinreich, MD, Department of Radiology, Division of Neuroradiology, The Johns Hopkins Medical Institutions, 600 N Wolfe St, Baltimore, MD 21287.

AJNR 17:669-675, Apr 1996 0195-6108/96/1704-0669

© American Society of Neuroradiology

disease, we found that the coronal plane shows a distinct relationship between the medial rectus and the posterior ethmoidal sinus. Our experience has shown that the optic nerve is always immediately adjacent to the lateral wall of the sphenoidal sinus and is usually not contiguous with the posterior ethmoidal sinus. The objective of this study was to delineate the precise relationship between the optic nerves and the posterior paranasal sinuses using CT imaging data, and to determine the relative frequency of variations in this relationship. It is hoped that this information will provide a more accurate understanding of the regional anatomy in order to decrease the possibility of surgical complications associated with functional endoscopic sinus surgery of the posterior paranasal sinuses.

Materials and Methods

We reviewed the findings on 150 consecutive CT scans of the paranasal sinuses of patients examined for chronic inflammatory disease of the nasal cavity and paranasal sinuses. The patient population included 97 female and 53 male subjects. Direct coronal CT scans were obtained with 4-mm section thickness, 4-mm table incrementation, 2-second scan time, 120 mA·s, and 120 kV(p) on a Siemens (Iselin, NJ) Somatom-Plus CT scanner. Both bone (window, 2500 Hounsfield units (HU); level, 500 HU) and soft-tissue (window, 1700 HU; level, -300 HU) scans were available for interpretation.

Because direct axial sinus CT is not performed routinely at our institution, an axial oblique reconstruction along the course of the optic nerve through the optic canal was obtained and evaluated for the first 100 patients to add to the validity of our observations on the coronal examination.

The direct relationship between the optic nerve and the posterior ethmoidal and sphenoidal sinuses was recorded separately for the left and right sides. Furthermore, indentations into the sinus wall, the coursing of the nerve through the sinus, and the presence of bone dehiscence along the optic nerve were also recorded. Pneumatization of the anterior clinoid process was also noted. Bone dehiscence was defined as the absence of visible bone density separating the sinus from the course of the nerve.

As the aim of the study was to evaluate the normal, fully developed sphenoidal sinus, patients younger than 13 years old were excluded from the study (8), as were patients with bone disease.

Results

A total of 300 optic nerves were evaluated in 150 patients. In all cases the optic nerves coursed in close relationship to the sphenoidal sinus. We found the optic nerve to be contigu-

TABLE 1: Description and frequency of optic nerve types

Type	Description	R Side	L Side	Total (Percent)
1	Adjacent to sphenoidal sinus	119	109	228 (76)
2	Indentation on sphenoidal sinus	18	26	44 (15)
3	Optic nerve traversing sphenoidal sinus	8	11	19 (6)
4	Adjacent to sphenoidal and posterior ethmoidal air cells	5	4	9 (3)
Total		150	150	300 (100)

ous with the posterior ethmoidal air cell in only 9 (3%) of the 300 cases (Table 1).

The relationship of the optic nerve to the posterior paranasal sinuses was characterized as one of four types. In the most common form, type 1 (76%), the optic nerve is immediately adjacent to the lateral or superior wall of the sphenoidal sinus, without impression on the sinus wall (Fig 1). Type 2 nerves (15%) cause an impression on the lateral sphenoidal sinus wall (Fig 2). Type 3 nerves (6%) course through the sphenoidal sinus rather than simply run adjacent to the sinus (Figs 3 and 4). Type 1 through 3 nerves do not come in contact with the posterior ethmoidal air cells. Type 4 nerves (3%) course immediately lateral to the posterior ethmoidal and sphenoidal sinuses. Contact with the posterior ethmoidal air cell was usually at the sphenoethmoidal junction (Fig 5).

Two hundred twenty-eight nerves were found to be of type 1 configuration, with 119 on the right and 109 on the left. Forty-four nerves were type 2, with 18 on the right and 26 on the left. Nineteen nerves were type 3, with 8 on the right and 11 on the left. Nine nerves were type 4, with 5 on the right and 4 on the left (Table 1).

Dehiscence was present in 7% of type 1 nerves, in 82% of type 2 nerves, and in 100% of type 3 optic nerves. Only one of the nine type 4 nerves was dehiscent. No discernible bone separating the sphenoidal sinus from the optic nerve was seen in 24% of cases (Table 2).

The anterior clinoid process was pneumatized in 13 (4%) of 300 nerves. Ten (77%) of these were associated with dehiscence of the optic nerve. Pneumatization was most frequently associated with a type 2 (31%) or type 3 (54%) nerve configuration, although type 1 and type 4 nerves accounted for 8% each (Fig 6).

There was no significant left-sided or right-sided predominance for dehiscence, with 34 (47%) of 73 dehiscences present on the right

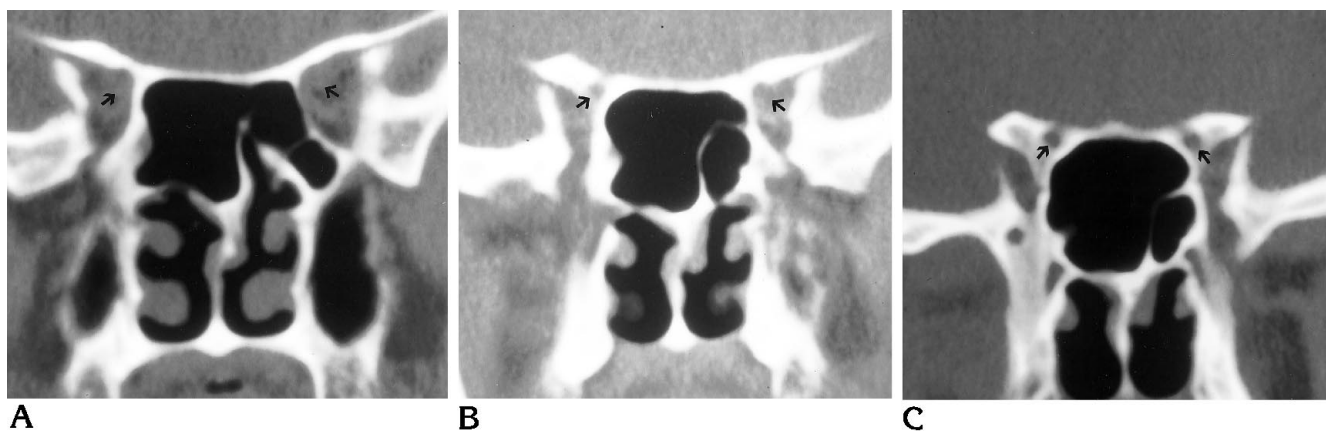


Fig 1. Type 1 optic nerve. Coronal CT scans from anterior (A) to posterior (C) reveal the position of the optic nerve (arrows in A). The optic canal (arrows in B and C) is adjacent to the sphenoidal sinus but does not indent the wall of the sinus.

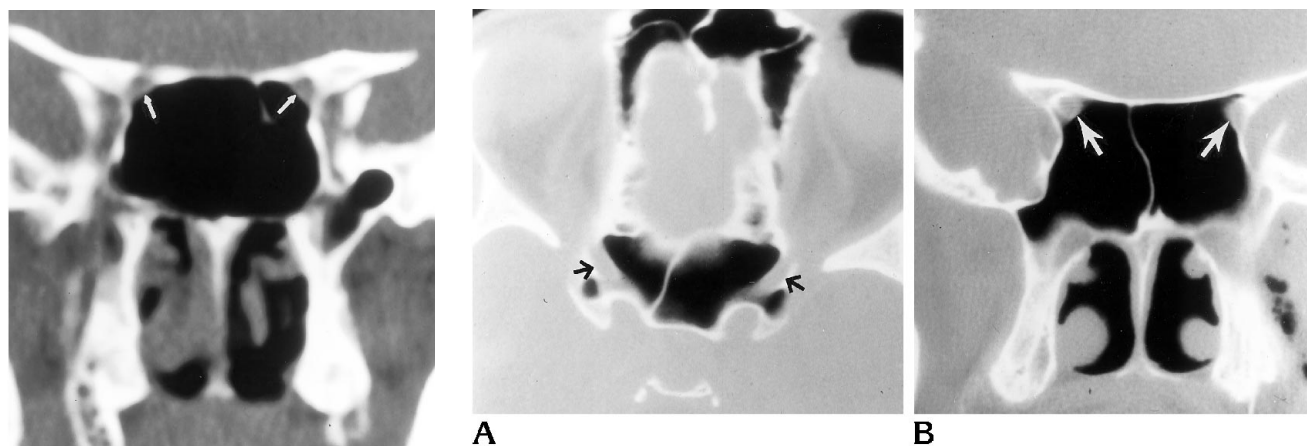


Fig 2. Type 2 optic nerve. Coronal CT scan with bilateral optic nerves (arrows) penetrating the contour of the sphenoidal sinus. There is an absence of bone density along the medial border of the optic canal (dehiscence).

Fig 3. Type 3 optic nerve. Axial (A) and coronal (B) CT scans reveal bilaterally dehiscient optic nerves (arrows) coursing through the sphenoidal sinuses.

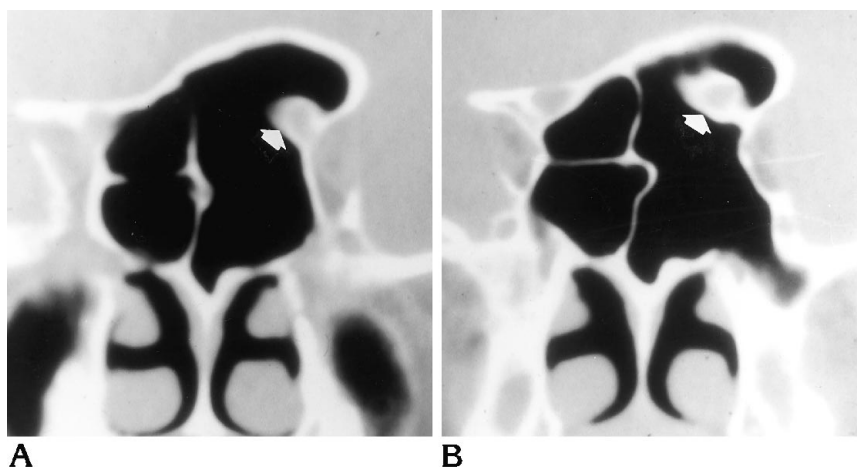


Fig 4. Type 3 optic nerve without dehiscence. Unusual case (not part of our series) of a type 3 nerve with intact bone (arrows) surrounding the nerve throughout its course. The sphenoidal sinus is asymmetrically pneumatized.

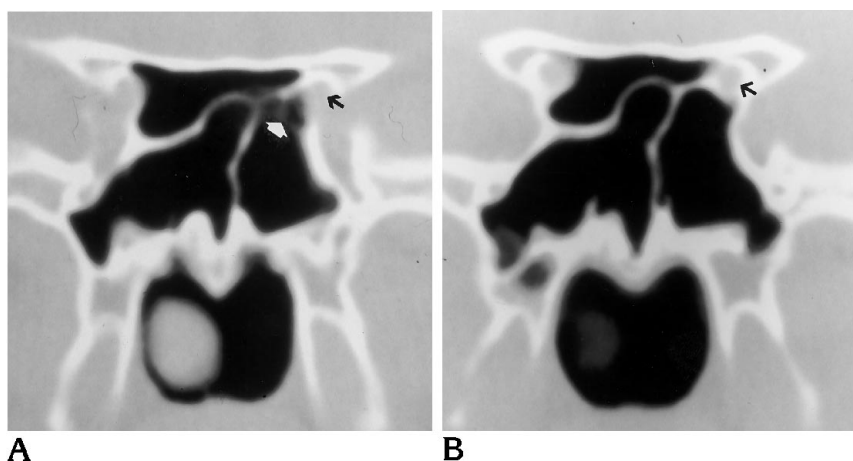


Fig 5. Type 4 optic nerve. Coronal CT scans from anterior (A) to posterior (B) show the optic nerve (black arrows) to be in contact with the posterior ethmoidal sinus at its junction (white arrow) with the sphenoidal sinus.

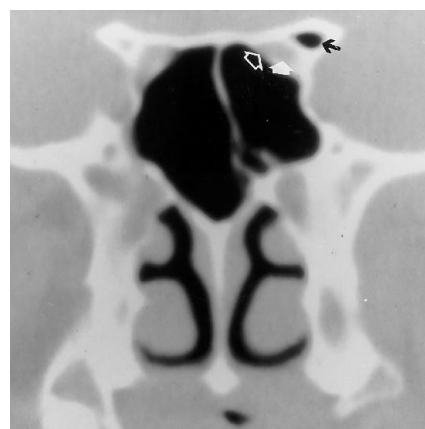
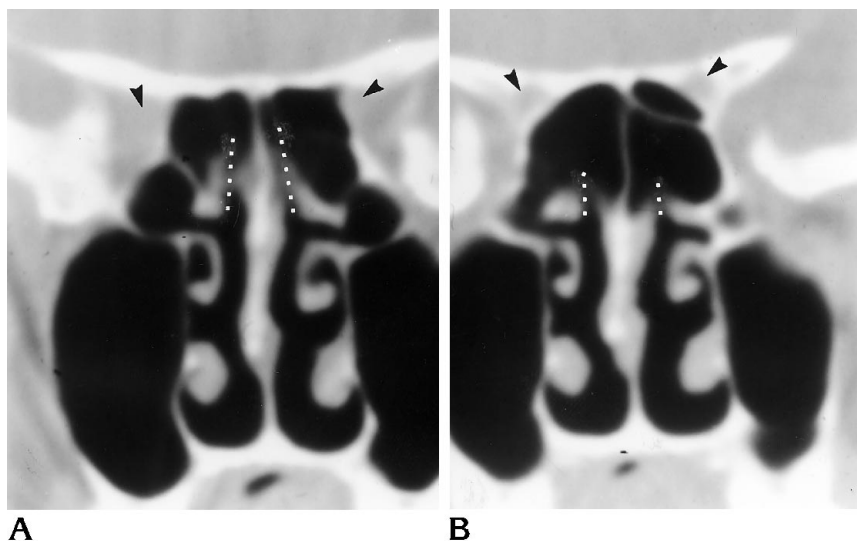


Fig 6. Pneumatized anterior clinoid process. Coronal CT scan shows a pneumatized anterior clinoid process (black arrow) and an adjacent type 2 optic nerve (solid white arrow). Dehiscence (open arrow) is present along the medial border of the optic canal.

Fig 7. Sphenoethmoidal recess. Coronal CT scans from anterior (A) to posterior (B) reveal the sphenoethmoidal recesses (dotted lines). Note the position of the optic nerves (arrowheads) and their relationship to the pneumatized portion of the sphenoidal sinus. In the sagittal plane, the superior segment of the sphenoethmoidal recess is anterior to its inferior segment. These air channels appear segmented because of their obliquity to the coronal scan plane.



and 39 (53%) present on the left. There was also no significant difference in the rates of dehiscence between female and male subjects. Female subjects represented 194 of the total optic nerves evaluated and male 106. Forty-seven (24%) of 194 nerves had dehiscence in female subjects and 26 (25%) of 106 nerves had dehiscence in male subjects. Rates were also similar for unilateral and bilateral dehiscence in both sexes (Table 3).

Axial oblique reconstructions along the course of the nerve were performed on the first 100 scans. These confirmed our impressions of the coronal examination in all cases.

Discussion

The relationship between the optic nerve and the paranasal sinuses has been studied for nearly a century. The author most quoted on this topic is Onodi, who in 1908 described 12 broad groups with 38 various subgroups regarding this morphologic relationship (1). The number of specimens he evaluated and the frequency of the various relationships he found were not reported in his communication. He states in his cadaveric study that "the frequent intimate relation of the optic nerve with the last ethmoid air cell is proved in such a way that it is

TABLE 2: Frequency of bone dehiscence in each optic nerve type

Nerve Type	No. of Nerves Found	No. (%) of Nerves with Dehiscence
1	228	17 (7)
2	44	36 (82)
3	19	19 (100)
4	9	1 (11)
Total	300	73 (24)

about time to drop the almost mechanical assumption of the relation of the optic nerve to the sphenoid sinus" (1). The term *Onodi cell* was subsequently coined in reference to the most posterior ethmoidal air cell, implying that this cell directly abuts the optic nerve. Onodi observed that in those cases in which the optic canal is formed by the last ethmoidal air cell, its wall may be extremely thin and occasionally dehiscent (1). Although he did not emphasize the point, Onodi also documented the occasional occurrence of extremely thin sphenoidal sinus walls.

Shaeffer, in his 1920 paper (2), described the intimate relationship of the optic nerve to the sphenoidal sinus. These structures were separated by only a thin mantle of bone, 0.2 to 2.0 mm thick and averaging 0.5 mm in his series. He also described the somewhat less frequent association of the optic nerve with the posterior ethmoidal sinuses.

Peele (3) emphasized the relationship of the optic nerve to the sphenoidal sinus, pointing out that the optic nerve is one of several important structures indenting the sphenoidal sinus wall. He described the presence but gave no indication of the frequency of dehiscence of the lateral wall of the sphenoidal sinus. Fujii et al (4) performed a cadaveric microsurgical study of the neurovascular relationships of the sphenoidal sinus, in which 49 (98%) of 50 optic canals protruded into the sphenoidal sinus. In that study, 4% of the sinus walls were dehiscent over the optic nerve and 78% were less than 0.5 mm thick. The relative contribution of the posterior ethmoidal air cell to the optic canal was not addressed in either study.

Mafee et al (5) pointed out the close relationship between the sphenoidal and posterior ethmoidal sinuses and the optic nerve in their discussion of the complications of functional endoscopic sinus surgery. These authors cited extensive lateral pneumatization of the posterior ethmoidal air cells as a source of increased

TABLE 3: Sex distribution and sidedness of bone dehiscence over the optic nerve

	Bilateral	Unilateral		No. (%) of Nerves with Dehiscence
		L Side	R Side	
Female (n = 97)	14	11	8	47 (24)
Male (n = 53)	8	6	4	26 (25)
Total	22	17	12	73 (24)

vulnerability of the optic nerve during this type of surgery.

Cheung et al (6) examined the anatomic relationship of the lateral wall of the sphenoidal sinus in the context of transnasal transethmoidal endoscopic surgery. Their assessment of 25 CT scans of the sphenoidal sinus revealed a 32% (8 of 25) frequency of optic nerve visibility due to pneumatization around the optic canal. The frequency with which the optic nerve was found in association with the posterior ethmoidal air cell was not reported. Dehiscence over the optic nerve was not present in their series.

Hudgins (7), in her description of direct optic nerve injury during endoscopic sinus surgery, stated that the optic nerve is usually in proximity to both the ethmoidal and sphenoidal sinuses. Further, she described instances of dehiscence or very thin bone overlying the optic nerve when the posterior ethmoidal or sphenoidal sinuses are extensively pneumatized.

CT can clearly show the relationship between the optic nerve and the paranasal sinuses. It is the imaging technique of choice in the examination of the paranasal sinuses and adjacent structures. Its ability to display bone, soft tissue, and air facilitates accurate depiction of anatomy and extent of disease in and around the paranasal sinuses. In the examination of patients with inflammatory sinus disease, coronal imaging is routinely performed. The coronal plane correlates with the surgical approach used during endoscopic surgery and optimally displays the ostiomeatal unit, the relationship of the brain and ethmoidal roof, the anterior ethmoidal air cells, the course of the optic nerve, and the optic foramen. For these reasons, direct axial imaging is not routinely performed at our institution (9). However, in the presence of disease of the posterior ethmoidal and sphenoidal sinuses, and for optimal display of anatomic and pathologic relationships between the sinuses and the optic nerves and carotid arteries,

we advocate use of axial imaging, especially if functional endoscopic sinus surgery is planned.

We found that the sphenoethmoidal boundary is readily identified on coronal images by following the sphenoethmoidal recess, and on axial images by identifying the anterior wall of the sphenoidal sinus (Fig 7). An improved display of the sphenoethmoidal boundary is provided by axial images and may be particularly helpful to the referring clinician in assessing the regional relationships of the optic nerve and carotid artery to the posterior paranasal sinuses. Axial oblique reconstructions in the plane of the optic nerve confirmed our impressions of the coronal examination in all cases.

Relatively perpendicular to the lamina papyracea, the coronal plane is useful for assessment of the proximity of the obliquely oriented optic nerve to the sinus wall. This plane also provides an accurate display of the orbital fat plane present between the nerve and the sinus. The optic nerve is usually protected by the solid bone of the greater wing of the sphenoid bone without visible surrounding fat at the optic canal. However, pneumatization of the sphenoidal sinus is extremely variable and at times extends into the adjacent bone structures of the sphenoid wing, the anterior and posterior clinoid processes, and the pterygoid process. In general, the greater the aeration of the sinus and surrounding structures, the greater the likelihood of optic nerve or canal indentation on the sphenoidal sinus and of bone dehiscence.

Our study confirms the four categories of relationships between the optic nerve and the posterior paranasal sinuses, as described earlier. All 300 nerves in our series were intimately related to the lateral wall of the sphenoidal sinus. Only nine nerves (3%) were also related to the most posterior ethmoidal air cell.

The optic nerve was dehiscient in all cases in which it traveled through the sphenoidal sinus (type 3), and in nearly 82% of cases in which it impressed upon the sphenoidal sinus wall (type 2). We are aware of cases of nondehiscient type 3 optic nerves (Fig 4), but this configuration did not occur in our sample. Type 4 nerves were least frequent, found in only 3% of our study population. Among this small subset of cases, dehiscence was found in only one of nine patients.

The presence of anterior clinoid pneumatization is indicative of increased optic nerve exposure and dehiscence: 85% of nerves associated

with a pneumatized anterior clinoid process were of type 2 or 3 configuration, and 77% were dehiscient, affording increased exposure.

Indentations on the lateral wall of the sphenoidal sinus are usually caused by the optic nerve, the internal carotid artery, or the trigeminal nerve. The trigeminal nerve is typically covered by a thick mantle of bone (6). The dehiscence of bone over the carotid artery has been described previously (10, 11). Whenever there is an indentation in the lateral sphenoidal sinus wall, the likelihood of dehiscence of bone over a vital structure is significantly elevated and should be searched for.

In our study, sinus wall dehiscence over the optic nerve was detected with a similar frequency as that reported for the cavernous carotid artery at the sphenoidal sinus. Johnson et al (10) reported a 12% frequency of cavernous carotid artery dehiscence in a CT evaluation of 500 patients. Kennedy et al (11) reported a 22% frequency of clinical dehiscence of bone over the cavernous carotid artery in a cadaveric study of 41 sinuses. The usefulness of preoperative CT was highlighted in both studies.

The frequency of dehiscence over the optic nerve in our investigation (24%) is higher than that reported by Fujii et al (4) in their cadaveric study of 50 nerves (4%). However, they reported that in 78% of cases, the bone separating the sinus mucosa from the optic nerve was less than 0.5 mm thick. Differences in the frequencies may be due to differences in sample size, patient population, examination technique, and the inability to discern visually bone thickness less than 0.5 mm on a CT examination. The accuracy of CT in the detection of bone dehiscence has been documented previously in studies of the relationship of the carotid artery to the sphenoidal sinus (10, 11). The ability to detect dehiscence through visual inspection of CT scans has the potential advantage of identifying cases in which extremely thin bone overlies the optic nerve but offers no significant protection from trauma, thus giving a clinically relevant assessment of nerves that are at risk during surgery on the posterior paranasal sinuses.

The impact of the presence of chronic sinusitis on these anatomic relationships is not known. The Onodi study (1) and the studies by Shaeffer (2), Peele (3), and Fujii et al (4) were performed on random cadaveric specimens. Our investigation was specifically targeted to

patients with chronic inflammatory sinus disease, who constitute the population most likely to undergo endoscopic sinus surgery. It points out to surgeons and radiologists the relationships between the optic nerve and paranasal sinuses and highlights the frequency of variations that may be potential "danger zones" during functional endoscopic sinus surgery.

In conclusion, all 300 nerves evaluated in this study were intimately related to the sphenoidal sinus. Only a small minority (3%) were in contact with the posterior ethmoidal sinus. Coronal CT revealed this relationship and axial scans facilitated visualization of the sphenoethmoidal boundary. We found that increased sphenoidal sinus pneumatization is associated with increasing optic nerve exposure. Anatomic configurations that predispose the optic nerve to injury include the type 2 or type 3 optic nerve relationship, bone dehiscence over the nerve, and pneumatization of the anterior clinoid process. A pneumatized anterior clinoid process is an important indicator of optic nerve vulnerability resulting from the frequent association with both dehiscence and the type 2 or type 3 nerve configurations. These configurations are common and should be routinely sought out so that devastating complications from sinus surgery can be avoided.

References

1. Onodi A. The optic nerve and the accessory cavities of the nose. *Ann Otol Rhinol Laryngol* 1908;17:1-61
2. Schaeffer JP. *The Nose, Paranasal Sinuses, Nasolacrimal Passages, and Olfactory Organs in a Man: A Genetic, Developmental, and Anatomico-physiological Consideration*. Philadelphia, Pa: Blakiston's Son & Co, 1920:190-193
3. Peele JC. Unusual anatomical variations of the sphenoid sinuses. *Laryngoscope* 1957;67:208-237
4. Fujii K, Chambers SM, Rhoton AL. Neurovascular relationships of the sphenoid sinus. *J Neurosurg* 1979;50:31-39
5. Mafee MF, Chow JM, Meyers R. Functional endoscopic sinus surgery: anatomy, CT screening, indications, and complications. *AJR Am J Roentgenol* 1993;160:735-744
6. Cheung DK, Attia EL, Kirkpatrick DA, Marcarian B, Wright B. An anatomic and CT scan study of the lateral wall of the sphenoid sinus as related to the transnasal transethmoid endoscopic approach. *J Otolaryngol* 1993;22:63-68
7. Hudgins PA. Complications of endoscopic sinus surgery. *Radiol Clin North Am* 1993;31:21-32
8. Scuderi AJ, Harnsberger HR, Boyer RS. Pneumatization of the paranasal sinuses: normal features of importance to the accurate interpretation of CT scans and MR images. *AJR Am J Roentgenol* 1993;160:1101-1104
9. Zinreich SJ, Kennedy DW, Rosenbaum AE, Gayler BW, Kumar AJ, Stammberger H. Paranasal sinuses: CT imaging requirements for endoscopic surgery. *Radiology* 1987;163:769-775
10. Johnson DW, Hopkins RJ, Hanafee WN, Fisk JD. The unprotected parasphenoidal carotid artery studied by high-resolution computed tomography. *Radiology* 1985;155:137-141
11. Kennedy DW, Zinreich SJ, Hassab MH. The internal carotid artery as it relates to endonasal sphenoethmoidectomy. *Am J Rhinol* 1990;4:7-12