



**Providing Choice & Value**

Generic CT and MRI Contrast Agents



**FRESENIUS  
KABI**

**CONTACT REP**

**AJNR**

This information is current as  
of July 30, 2025.

**ACCESS: ACtive Catheterization for  
EndovaScular TreatmentS—A  
First-in-Human, Single-Center,  
Nonrandomized, Open Clinical Study of the  
G60 Active Device for Endovascular  
Neurointerventions**

Simon Escalard, Amira Al-Raaisi, Jean-Philippe Désilles,  
Hocine Redjem, Stanislas Smajda, Mounir Lahlouh, François  
Delvoye, William Boisseau, Mikaël Mazighi and Michel  
Piotin

*AJNR Am J Neuroradiol* published online 9 August 2024  
<http://www.ajnr.org/content/early/2024/08/08/ajnr.A8345>

# ACCESS: ACtive Catheterization for Endovascular TreatmentS—A First-in-Human, Single-Center, Nonrandomized, Open Clinical Study of the G60 Active Device for Endovascular Neurointerventions

Simon Escalard, Amira Al-Raaisi, Jean-Philippe Désilles, Hocine Redjem, Stanislas Smajda, Mounir Lahlouh, François Delvoye, William Boisseau, Mikael Mazighi, and Michel Pötin



## ABSTRACT

**SUMMARY:** The catheterization of supra-aortic vessels during neuroendovascular interventions may be challenging in the setting of complex aortic arch anatomy. Evaluation of a new mechatronic controllable directional device in conjunction with different sheath and guide catheters to ease the cannulation of the supra-aortic vessels was conducted in the setting of a first-in-human clinical study. The evaluation assessment included access to the aortic arch, the technical success of the device in terms of time to target vessel, target vessel catheterization, adverse events, and clinical outcome. Ten subjects were enrolled at 1 site for treatment. Successful access, target vessel catheterization, and correct positioning of the catheter into the target vessel with the G60 device were achieved for all 10 procedures (7 from femoral access, 3 from radial access). One procedural complication, unrelated to the G60 device, was recorded during the investigation. The G60 is a polyvalent active device that facilitates guide catheter navigation in neuroendovascular interventions.

**ABBREVIATIONS:** DSMB = data and safety monitoring board; FIH = first-in-human; GC = guide catheter; SAV = supra-aortic vessel

The primary access to the intracranial vessels, meaning the placement of a guide catheter (GC) at the cervical level, is the first step of any neuroendovascular procedure.

The success of this first step usually relies on the operator's experience, the patient's arterial anatomy, and the choice of a combination of diagnostic catheter, GC, and guidewire that are suitable for the case.

The G60 (Basecamp Vascular) is a mechatronic, active, controllable device that is intended to support and enable the positioning of a GC in any supra-aortic vessel (SAV), via femoral or radial access, without the need for a guidewire or a diagnostic catheter, whatever the patient's anatomy. The G60 has a length of 1385 mm and an outer diameter of 1.55 mm (0.061") and is inserted into a GC of sufficient inner diameter. The distal part of

the G60 is composed of 2 active parts that can be independently or simultaneously curved to form a "C" or an "S" shape (Figure) to enable the navigation of the GC and selection of a SAV. The activation, meaning the shape of the distal segment of the device, is controlled in real time by the operator during the navigation via miniature shape-memory alloy-based actuators (integrated at the tip of the device)<sup>1</sup> and powered by a generator integrated in a sterile handle that is connected directly to the device. This means that the G60 can be used with a straight distal-tip configuration in straight vessels (such as the thoracoabdominal aorta and radial, brachial, and subclavian arteries) to limit the risk of catheter-induced side-branch selection and injury, then temporarily configured into an "S" for the catheterization of the target SAV, then relaxed to straight shape again for the navigation more distally in the target SAV. Both proximal and distal active parts measure 35 mm (distal active part: 100° < curvature; proximal active part: 70° < curvature < 125°) (Online Supplemental Data).

The objective of this clinical investigation was to evaluate the safety and technical success of the G60 device when used to facilitate endovascular access to the target SAV.

## MATERIALS AND METHODS

This was a prospective, single-center, nonrandomized, open-label, first-in-human (FIH) premarket study. For all cases, the aortic arch was 3D modeled by using the AI framework based on deep learning architectures<sup>2</sup> to allow automatic segmentation, calculate anatomic/geometric features such as tortuosity,

Received February 12, 2024; accepted after revision April 30.

From the Department of Interventional Neuroradiology (S.E., J.-P.D., H.R., S.S., F.D., W.B., A.A.-R., M.M., M.P.), Rothschild Foundation Hospital, Paris, France; and CReSTIC (M.L.), Université de Reims, Reims, France.

Mr. Lahlouh is funded by BCV Systems for a thesis supported by the National Association for Research and Technology (ANRT) (Grant 2020/0638).

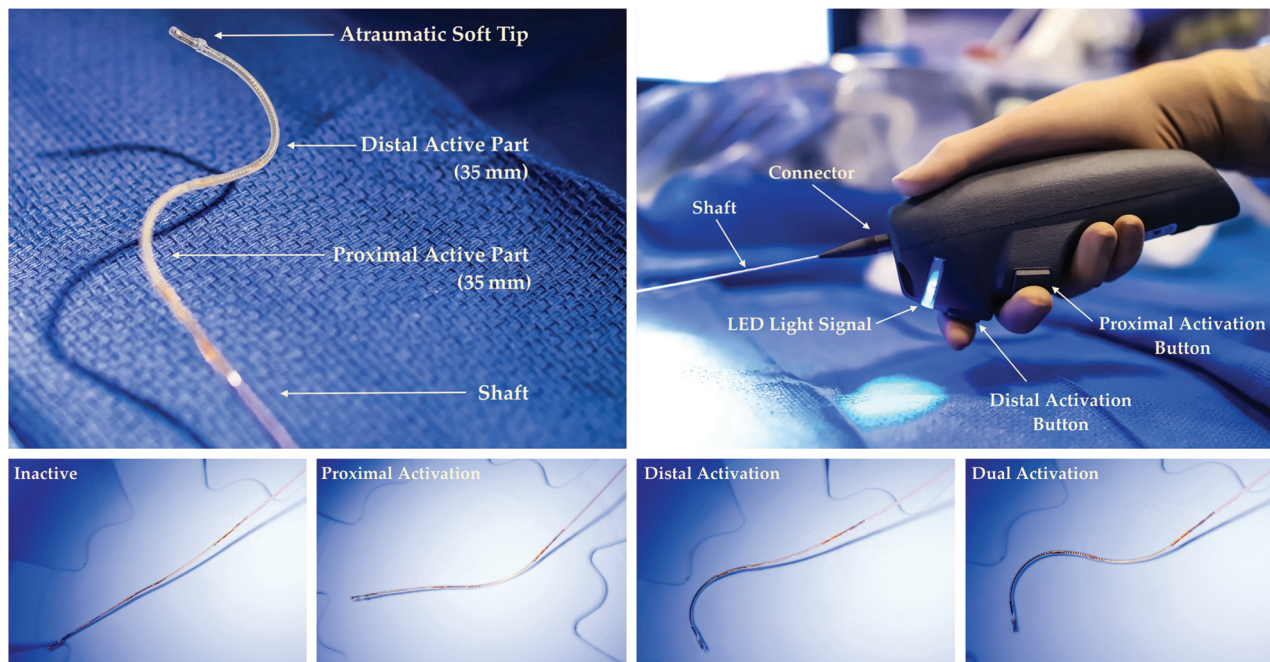
Please address correspondence to Simon Escalard, Department of Interventional Neuroradiology, Rothschild Foundation Hospital, 25 rue Manin, 75019 Paris, France; e-mail: simon.escalard@gmail.com

Indicates open access to non-subscribers at [www.ajnr.org](http://www.ajnr.org)

Indicates article with online supplemental data.

Indicates article with supplemental online video.

<http://dx.doi.org/10.3174/ajnr.A8345>



**FIGURE.** The G60 device (passive and activated shapes).

and obtain the type of aortic arch according to the Madhwal classification.<sup>3</sup> These features had been the core of the G60 ex vivo development.<sup>4</sup>

Ten patients were required for this FIH study. Any patient scheduled for a neurointerventional endovascular treatment in our institution could be included in the study.

Exclusion criteria included patients with a type 3 aortic arch and patients with an indication for emergent treatment such as stroke.

Because of the restricted number of patients for this FIH study, no statistical analysis was performed.

The access site was left to the discretion of the operator.

Technical success was defined as a successful navigation of the GC with the G60 device inside into the target vessel, without the need for a diagnostic catheter or guidewire. Procedural time metrics such as total access time (from puncture to GC final placement), navigation time (from GC insertion with the G60 to final placement in the targeted vessel), and the overall procedure time (from arterial puncture to the end of the procedure) were recorded.

Safety measures consisted of the recording of adverse events (eg, embolus, dissection, stroke, or death) within 30 days of the intervention.

## RESULTS

All 10 patients were included between June 27, 2022, and July 7, 2022. As of July 7, 2022, 17 subjects had been screened consecutively: 1 patient was rejected because of a type 3 aortic arch (an exclusion criterion); 2 patients refused to participate, and 4 patients were eligible but not included because the required 10 patients had been already included. The indication was unruptured intracranial aneurysm for 7 patients (70%), brain arteriovenous malformation for 1 patient (10%), dural arteriovenous

fistula for 1 patient (10%), and ICA cervical stenosis for 1 (10%). The mean target vessel diameter was  $4.2 \pm 0.6$  mm (range 4–6 mm). Five patients (50%) had an aortic arch type 1, 3 patients (30%) had a type 2, and 2 patients (20%) had a bovine arch.

Baseline characteristics of the patients included are summarized in the Online Supplemental Data.

## G60 Performance Evaluation

The G60 was used with 2 different GCs (Neuron Max 088 and Benchmark 071, Penumbra; CE Mark and FDA Cleared). The G60 device was used as both a diagnostic catheter and a guidewire, meaning it was navigated up to the point where the GC was meant to be positioned: the common carotid artery, the cervical segment of the ICA, or the V2 segment of the vertebral artery. Successful catheterization of the target SAV was achieved in all cases; via femoral access in 7 cases and via radial access in 3 cases (Online Supplemental Data). No malfunction occurred during the procedures. No adjunctive or alternative device such as a guidewire or diagnostic catheter was required.

## Procedural Duration

The total access time was 22.5 minutes (range, 13–45). The navigation time was 8 minutes (range, 4–17). The overall procedure time was 96 minutes (range, 25–172).

## Safety

One severe adverse event was reported. A patient had a minor ischemic stroke (NIHSS 1) following the procedure. This complication was determined by the data and safety monitoring board (DSMB) to be related to difficulties in aneurysm coiling and not related to the G60 device, because there was no evidence of spasm or carotid artery damage during the procedure. The hospitalization was prolonged by 1 day. The DSMB report is available upon

#### Details of the procedures and end points (all 10 patients)

Femoral access, <i>n</i>	7
Radial access, <i>n</i>	3
Aortic arch type 1	5
Aortic arch type 2	3
Aortic arch: bovine	2
Target vessel diameter, mean ( $\pm$ SD) mm	4.2 ( $\pm$ 0.6)
Successful navigation to target vessel, <i>n</i>	10 (100%)
Adjunctive/rescue device needed (wire/balloon/other catheter)	0 (0%)
Total access time, mean (range) min	22.5 (13–45)
Navigation time from puncture site to target vessel with GC and G60 device, mean (range) min	8 (4–17)
Overall procedure time, mean (range) min	96 (25–172)
Procedural AE (including access site), <i>n</i>	0
Procedural SAE, <i>n</i>	1
G60-related AE, <i>n</i>	0
G60-related SAE, <i>n</i>	0
Postprocedure AE, <i>n</i>	0
Postprocedure SAE, <i>n</i>	0

**Note:**—AE indicates adverse event; SAE, severe adverse event.

reasonable request. The summary of all procedure details and end points is presented in [Table](#).

## DISCUSSION

Since the beginning of the endovascular era, the catheterization of SAVs during diagnostic angiography and neuroendovascular interventions has been challenging in keeping with complex aortic arch anatomy and arterial tortuosity, requiring the development of specifically configured catheters and catheterization techniques.<sup>5</sup> Tortuosity of the aortic arch and carotid arteries is also associated with atherosclerotic disease burden. Bendszus et al<sup>6</sup> reported a significant correlation between the appearance of embolic lesions following diagnostic cerebral angiography and vessels that were difficult to catheterize, noting that emboli likely arose from the disruption of atherosclerotic plaques by excessive catheter manipulation. Easing the catheterization of the SAVs might subsequently diminish this risk.

The G60 device is intended for subjects who require endovascular navigation to access their cervical or intracranial vascular pathologies with a GC. The potential benefits of the G60 device include the possibility to navigate a GC in any type of vascular anatomy, from a radial or femoral access site, without the need for switching between different types of guidewires and diagnostic catheters.

For the 10 patients (100%), successful navigation to the target vessel with the G60 device and the GC was achieved according to the protocol (aortic arch types 1 and 2 and femoral or radial arterial puncture). Navigation to the target SAV was performed without vascular damage or vasospasm in all cases, even for the procedures in the vertebral artery and those conducted via a transradial approach.

Based upon the risks identified and the procedural and monitoring methods used to minimize these risks, the successful navigation of the G60 device to position the guide for performing cervical and intracranial vascular pathology treatment was in line with the expected benefits. There were no complications related to the G60 device during the procedures for the 10 patients.

This FIH clinical investigation was successful with regard to clinical performance and safety.

The benefits of this type of device could extend to emergent procedures, such as mechanical thrombectomy,<sup>7</sup> for which procedural difficulty due to unfavorable vascular anatomy of the aortic arch, supra-aortic artery tortuosity, and length of neurointerventional procedures are associated with poor outcome.<sup>5,8–11</sup>

## Study Limitations

This study's limitations are inherent to its FIH single-center design (as requested by the regulatory authorities), with a restricted number of patients, and the exclusion of type 3 aortic arch and

emergent stroke cases. No statistical analysis could be performed due to the small number of patients.

## CONCLUSIONS

The G60 device is a “one-size-fits-all” solution that not only enables but also eases GC navigation above the aortic arch and could replace the need for configured diagnostic catheters and guidewires that are usually required for variable anatomy and different access sites.

In this FIH study of 10 patients, the G60 device proved to be safe and effective with a reasonable time performance.

## ACKNOWLEDGMENTS

**Ethical Considerations:** This study was conducted according to GCP guidelines; with informed consent and Independent Ethics Committee (IEC) review and approval as defined in the World Medical Association Declaration of Helsinki, ISO 14155:2020 and the Medical Device Regulations (2017/745) of 5 April 2017. This trial was registered on ClinicalTrials.gov, Identifier: NCT05355259. Written consent from the patient was obtained in all cases.

**DSMB:** The DSMB was composed of 3 expert physicians in the field of endovascular neurointervention and/or neurosurgery, who were independent and not involved in the trial, nor in the BCV company. The purpose of the DSMB was to provide recommendations to the sponsor, provide assessment of end points, and assist in the interpretation of the adverse events observed during the conduct of the study.

**Disclosure forms** provided by the authors are available with the full text and PDF of this article at [www.ajnr.org](http://www.ajnr.org).

## REFERENCES

1. Couture T, Szwedczyk J. **Design and experimental validation of an active catheter for endovascular navigation.** *J Med Devices* 2017;12:011003 [CrossRef](#)
2. Lahlouh M, Chenoune Y, Blanc R, et al. **Aortic arch anatomy characterization from MRA: a CNN-based segmentation approach.** 2022

IEEE 19th International Symposium on Biomedical Imaging (ISBI) March 28–31, 2022; Kolkata, India. 1–5 [CrossRef](#)

3. Madhwal S, Rajagopal V, Bhatt DL, et al. **Predictors of difficult carotid stenting as determined by aortic arch angiography.** *J Invasive Cardiol* 2008;20:200–04
4. Badrou A, Tardif N, Chaudet P, et al. **Simulation of multi-curve active catheterization for endovascular navigation to complex targets.** *J Biomech* 2022;140:111147. [CrossRef Medline](#)
5. Simmons CR, Tsao EC, Thompson JR. **Angiographic approach to the difficult aortic arch: a new technique for transfemoral cerebral angiography in the aged.** *Am J Roentgenol Radium Ther Nucl Med* 1973;119:605–12 [CrossRef Medline](#)
6. Bendszus M, Koltzenburg M, Burger R, et al. **Silent embolism in diagnostic cerebral angiography and neurointerventional procedures: a prospective study.** *Lancet Lond Engl* 1999;354:1594–97 [CrossRef](#)
7. Powers WJ, Derdeyn CP, Biller J; American Heart Association Stroke Council, et al. **2015 American Heart Association/American Stroke Association focused update of the 2013 guidelines for the early management of patients with acute ischemic stroke regarding endovascular treatment: a guideline for healthcare professionals from the American Heart Association/American Stroke Association.** *Stroke* 2015;46:3020–35 [CrossRef Medline](#)
8. Knox JA, Alexander MD, McCoy DB, et al. **Impact of aortic arch anatomy on technical performance and clinical outcomes in patients with acute ischemic stroke.** *AJNR Am J Neuroradiol* 2020;41:268–73 [CrossRef Medline](#)
9. Shapiro M, Raz E, Nelson PK. **Aortic arch variants: a practical guide to safe and timely catheterization.** *Interv Neurol* 2018;7:544–55 [CrossRef Medline](#)
10. Sidiq M, Scheidecker E, Potreck A, et al. **Aortic arch variations and supra-aortic arterial tortuosity in stroke patients undergoing thrombectomy: retrospective analysis of 1705 cases.** *Clin Neuroradiol* 2023;33:49–56 [CrossRef](#)
11. Snelling BM, Sur S, Shah SS, et al. **Unfavorable vascular anatomy is associated with increased revascularization time and worse outcome in anterior circulation thrombectomy.** *World Neurosurg* 2018;120:e976–e983 [CrossRef Medline](#)