



**Providing Choice & Value**  
Generic CT and MRI Contrast Agents

**FRESENIUS  
KABI**

**CONTACT REP**

**AJNR**

**Utility of Gadolinium-Based Contrast in  
Initial Evaluation of Seizures in Children  
Presenting Emergently**

Denas Andrijauskis, Graham Woolf, Alexander Kuehne,  
Khalid Al-Dasuqi, Cicero T. Silva, Seyedmehdi Payabvash  
and Ajay Malhotra

This information is current as  
of July 29, 2025.

*AJNR Am J Neuroradiol* published online 31 August 2023  
<http://www.ajnr.org/content/early/2023/08/31/ajnr.A7976>

# Utility of Gadolinium-Based Contrast in Initial Evaluation of Seizures in Children Presenting Emergently

 Denas Andrijauskis,  Graham Woolf, Alexander Kuehne,  Khalid Al-Dasuqi,  Cicero T. Silva,  Seyedmehdi Payabvash, and  Ajay Malhotra

## ABSTRACT

**BACKGROUND AND PURPOSE:** The frequency and utility of gadolinium in evaluation of acute pediatric seizure presentation is not well known. The purpose of this study was to assess the utility of gadolinium-based contrast agents in MR imaging performed for the evaluation of acute pediatric seizure presentation.

**MATERIALS AND METHODS:** We identified consecutive pediatric patients with new-onset seizures from October 1, 2016, to September 30, 2021, who presented to the emergency department and/or were admitted to the inpatient unit and had an MR imaging of the brain for the evaluation of seizures. The clinical and imaging data were recorded, including the patient's age and sex, the use of IV gadolinium, and the underlying cause of epilepsy when available.

**RESULTS:** A total of 1884 patients were identified for inclusion. Five hundred twenty-four (28%) patients had potential epileptogenic findings on brain MR imaging, while 1153 (61%) patients had studies with normal findings and 207 (11%) patients had nonspecific signal changes. Epileptogenic findings were subclassified as the following: neurodevelopmental lesions, 142 (27%); intracranial hemorrhage (traumatic or germinal matrix), 89 (17%); ischemic/hypoxic, 62 (12%); hippocampal sclerosis, 44 (8%); neoplastic, 38 (7%); immune/infectious, 20 (4%); phakomatoses, 19 (4%); vascular anomalies, 17 (3%); metabolic, 3 (<1%); and other, 90 (17%). Eight hundred seventy-four (46%) patients received IV gadolinium. Of those, only 48 (5%) cases were retrospectively deemed to have necessitated the use of IV gadolinium: Fifteen of 48 (31%) cases were subclassified as immune/infectious, while 33 (69%) were neoplastic. Of the 1010 patients with an initial noncontrast study, 15 (1.5%) required repeat MR imaging with IV contrast to further evaluate the findings.

**CONCLUSIONS:** Gadolinium contrast is of limited additive benefit in the imaging of patients with an acute onset of pediatric seizures in most instances.

**ABBREVIATIONS:** ACR = American College of Radiology; GBC = gadolinium-based contrast; SPR = Society for Pediatric Radiologists

It is estimated that as many as 1% of children will experience at least 1 afebrile seizure by adolescence, and population-based studies estimate the incidence of epilepsy in childhood at around 0.5–8 per 1000 person-years.<sup>1–5</sup> The causes of epilepsy in the pediatric population are numerous and can be divided into 6 groups: genetic, structural, metabolic, immune, infectious, and unknown.<sup>6,7</sup> MR imaging is the criterion standard for the detection of structural epileptogenic abnormalities, making it critical in helping to define the electroclinical syndrome and for identifying surgically amenable lesions.<sup>6,8</sup> MR imaging has also been shown to be an important prognostic tool for predicting medical refractoriness.<sup>9–13</sup>

While the utility of MR imaging in the diagnosis and management of new-onset seizures is well-established, the extra yield of

adding gadolinium-based contrast (GBC) to the initial evaluation is not well-defined. Current American College of Radiology (ACR) guidelines state that MR imaging of the brain without and with contrast may be appropriate.<sup>13</sup> In a recent Society for Pediatric Radiologists (SPR) survey, nearly 24% of respondents stated that they used GBC “always or usually” for the initial evaluation of seizures, and another 32% responded that they used it “sometimes.”<sup>14</sup>

Multiple studies have shown evidence of trace amounts of GBC being retained chronically in the patient's body following administration.<sup>15–17</sup> Unlike in the acute setting, the chronic effects and safety profile of GBC are not yet known.<sup>18</sup>

The purpose of this study was to assess the use and utility of GBC in MR imaging performed for the evaluation of acute-seizure presentation in the pediatric population.

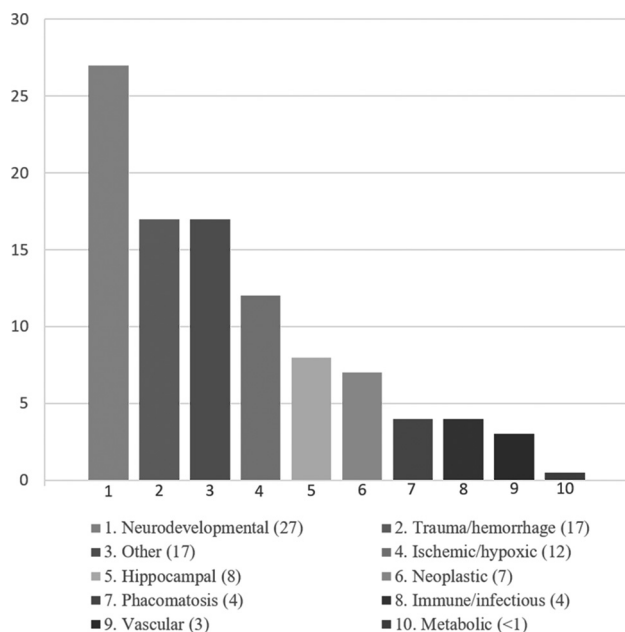
## MATERIALS AND METHODS

This Health Insurance Portability and Accountability Act–compliant retrospective study was approved by the institutional review board. Informed consent was waived for this retrospective analysis.

Received June 16, 2023; accepted after revision August 2.

From the Department of Radiology and Biomedical Imaging, Yale School of Medicine, New Haven, Connecticut.

Please address correspondence to Ajay Malhotra, MD, MMM, Department of Radiology and Biomedical Imaging, Yale School of Medicine, Box 208042, Tompkins East 2, New Haven, CT 06520-8042; e-mail: [ajay.malhotra@yale.edu](mailto:ajay.malhotra@yale.edu); @AjayMalhotraRad <http://dx.doi.org/10.3174/ajnr.A7976>



**FIGURE.** Frequencies of epileptogenic lesions stratified by etiologic categories in percentages (brackets).

Retrospective analysis of the clinical and imaging data was performed of consecutive patients with new-onset seizures, younger than 18 years of age, from October 1, 2016, to September 30, 2021, who presented to the emergency department and/or were admitted to the inpatient unit of an academic, tertiary care center and had an MR imaging of the brain for the evaluation of seizures. Patients with a previously established epilepsy diagnosis were excluded from the study. Patients with a previously known neurologic diagnosis and new-onset seizures were further subclassified and accounted for separately. MR imaging at the institution is performed as ordered by the providers and is not monitored in real-time for the administration of contrast.

All MR imaging cases with positive findings were reviewed, and the indication for GBC was determined on the basis of whether the abnormality was visualized on the noncontrast portion of examination, the additive value of GBC such as enhancement or better delineation of the lesion in the postcontrast portion of the examination, or the recommendation of the interpreting radiologist to order a follow-up MR imaging examination with contrast for better delineation of the lesion found on the initial noncontrast study. The review of cases with positive findings was performed by 2 residents supervised by an attending physician with >12 years of experience.

## RESULTS

A total of 1884 patients were identified for inclusion. The median age was 7 years (range, 3 days to 17.9 years) and 55% were male. Two hundred seventy of 1884 (14.3%) patients were younger than 1 year of age, including 102/1884 (5.4%) patients younger than 1 month of age. Of the 1884 patients, 524 (28%) had potential epileptogenic findings on brain MR imaging, while 1153 (61%) had normal findings and 207 (11%) had nonspecific signal changes of

unknown clinical significance. One hundred forty-six of 270 (54%) infants and 41/102 (40%) neonates had normal findings on MR imaging.

The most common type of epileptogenic finding was neurodevelopmental lesions detected in 142 (27%) children. The most frequent abnormalities in this group consisted of focal cortical dysplasia in 47 (33%), followed by polymicrogyria in 24 (17%). Neurodevelopmental lesions were seen in 18/270 (6.7%) infants and in 6/102 (5.9%) neonates. The second most common category of epileptogenic findings was intracranial hemorrhage, accounting for 89 (17%) cases. Hemorrhage was seen in a higher proportion of infants (52/270; 19.2%) and neonates (25/102; 24.5%). Eighteen of 52 hemorrhages in infants were due to germinal matrix bleeds, and all these patients had bleeds detected on head ultrasound before the MR imaging obtained for seizure work-up. Birth trauma or nonaccidental trauma was the cause of hemorrhage in 19 infants, 7 of them neonates. Hemorrhagic infarct was seen in 2 patients, and the remaining 13 had nonspecific bleeds. Evidence of a hypoxic-ischemic injury was identified in 62 (12%) children with etiologically relevant lesions on brain MR imaging. Of note, this was the most common seizure etiology among the neonate population (27; 43%). Epileptogenic lesions associated with a hippocampal etiology were noted in 44 (8%) children. The next most common types of epileptogenic lesions were neoplastic (38; 7%) and immune/infectious (20; 4%). Phacomatoses as an etiology of seizures was detected in 19 (4%) children with 14/19 (74%) diagnosed with tuberous sclerosis; 4/19 (21%), with neurofibromatosis; and 1 patient, with Sturge-Weber syndrome. Vascular anomalies were identified in 17 (3%) patients. The least common epileptogenic category was metabolic (eg, metachromatic leukodystrophy, Gaucher disease), which was detected in 3 patients (<1%). The rest of the identified epileptogenic lesions were subclassified as “other” (17%). Sample findings in this category include structural asymmetry, periventricular leukomalacia, or large arachnoid cysts with mass effect.

The frequency of epileptogenic lesions stratified by etiologic categories is shown in the Figure. The frequencies of epileptogenic lesions were not statistically different between the male and female pediatric population ( $P > .05$ ).

A total of 874 (46%) patients received IV gadolinium for the brain MR imaging. Of those, 48 (5%) cases were retrospectively deemed to have necessitated the use of IV gadolinium to establish the initial diagnosis, in which enhancement or better delineation of the lesion in the postcontrast portion of the examination was noted. There was no case in which the abnormality was seen only on the postcontrast images. Fifteen of 48 (31%) cases were subclassified as immune/infectious, while 33 (69%) were neoplastic. Five of these 15 patients with infections were infants (3 neonates). The immune/infectious cause was clinically suspected for 9 of 15 patients (eg, meningitis, encephalitis), while 6 patients did not have an established clinical differential for the seizure etiology, and it turned out to be MS, Lyme disease, or a nonspecific demyelination process. Fifteen of 33 patients with a neoplastic seizure cause had an already known and previously confirmed CNS malignancy; therefore, contrast-enhanced MR imaging was ordered on the basis of prior medical history. Eighteen cases of

neoplastic process were newly diagnosed and not suspected on clinical examination: pilocytic astrocytoma ( $n = 3$ ), ganglioglioma ( $n = 3$ ), choroid plexus papilloma ( $n = 2$ ), pineal glioma ( $n = 2$ ), anaplastic astrocytoma ( $n = 1$ ), pleomorphic xanthoastrocytoma ( $n = 1$ ), schwannoma ( $n = 1$ ), tectal glioma ( $n = 1$ ), and low-grade gliomas, not biopsied ( $n = 4$ ).

The remainder of the patients did not show the additional value of GBC for initial diagnostic purposes.

Of 1010 patients with an initial noncontrast MR imaging study, 15 (1.5%) required repeat MR imaging with IV contrast for further evaluation as per the recommendation of interpreting radiologist. These cases were the following: indeterminate lesions with broad differential ( $n = 4$ ), low-grade glioma, not biopsied ( $n = 3$ ), encephalitis ( $n = 1$ ), MS ( $n = 1$ ), anaplastic astrocytoma ( $n = 1$ ), choroid plexus papilloma ( $n = 1$ ), Lyme disease ( $n = 1$ ), pilocytic astrocytoma ( $n = 1$ ), pineal glioma ( $n = 1$ ), and ganglioglioma ( $n = 1$ ).

## DISCUSSION

Our results showed that 28% of patients with new-onset pediatric seizures had a potential epileptogenic focus on brain MR imaging. This finding is consistent with those in previous studies that have validated MR imaging as an important diagnostic and prognostic tool for the evaluation of new-onset seizures in the pediatric population.<sup>9,19,20</sup>

Forty-six percent of our study cohort received IV gadolinium for the initial brain MR imaging study. This is consistent with the results of the 2017 SPR survey, in which 24.7% of respondents indicated that they “always or usually” administered GBCA agents for patients with seizures, while 32% indicated that they used it “sometimes.”<sup>14</sup> The current ACR guidelines for patients with seizures state that MR imaging with GBC may be appropriate for the initial evaluation of new seizures in a patient without known trauma.<sup>13</sup> While the ACR guidelines do report that contrast should be used when images without IV contrast are found to be insufficient or when there is clinical suspicion of a neoplastic or inflammatory condition, this recommendation is based on and cites a review article.<sup>8</sup>

Specifically, for children 1 month to 18 years of age with focal seizures, MR imaging with GBC was deemed “maybe appropriate, with disagreement” due to insufficient medical literature evidence.<sup>21</sup> There is a lack of data regarding the diagnostic advantage of GBC-enhanced MR imaging. Our study specifically investigated the utility of MR imaging contrast in the evaluation of new-onset pediatric seizures and found limited benefit from GBC in most cases. In a recent retrospective study, Nelson et al<sup>19</sup> found that in adults presenting with acute seizure, contrast was not necessary in all cases. Our results were concordant, and very few patients had potentially epileptogenic findings that required contrast for characterization. Forty-eight of 874 (5.5%) patients who received GBC had infection/inflammation or neoplastic etiology, and in 24 of these patients, there was previous clinical concern for infection or known CNS malignancy. Fifteen of 1010 (1.5%) patients with an initial noncontrast MR imaging underwent a repeat study with IV contrast to further evaluate as per the recommendation of the interpreting radiologist. Most patients with previously unsuspected or incompletely characterized

lesions on noncontrast MR imaging had low-grade nonenhancing tumors.

The value of GBC for the detection of brain neoplasms and CNS infections is well-established in the literature.<sup>13,22,23</sup> Thus, when there is clinical suspicion of tumor or an immune/infectious process, such as fever, suspected encephalitis, or a history of malignancy or primary CNS tumor, an initial evaluation with MR imaging of the brain with and without contrast is warranted. However, infectious processes and neoplasms account for only a subset of seizure etiologies and epileptogenic findings on MR imaging. In our study, these accounted for only 11% of all potentially epileptogenic findings and were identified in only 3% of patients overall.

The administration of GBC is not without risks. Along with known potential acute allergic and physiologic reactions, recent literature has increasingly demonstrated trace, chronic gadolinium deposition within tissue.<sup>15-17</sup> The potential adverse effects of chronic gadolinium deposition within tissues are not yet well-understood.<sup>24</sup>

With the potential long-term consequences of gadolinium deposition still unknown and our study showing that in the overwhelming majority of cases, GBC administration has little diagnostic benefit, it stands to reason that contrast administration should be restricted in the pediatric population. Restricting the use of gadolinium would also lead to a potential reduction in scan times and the need for sedation. Contrast may be reserved for specific clinical scenarios where there is clinical suspicion of neoplasm or infection or subsequent to an abnormality on noncontrast MR imaging warranting postcontrast imaging. Implementing this stepwise approach may be met with concerns over potential delays in diagnosis and the inconvenience of having to recall patients for subsequent imaging. However, at most, in our study, <1/40 patients had findings requiring contrast for further evaluation that would have required a callback, and most of these were nonurgent, low-grade lesions. Real-time monitoring of these patients for the use of contrast during scanning might also be beneficial.

Limitations of our study primarily revolve around the retrospective nature of the chart and imaging review used to collect our data for analysis. Contrast may have been useful in excluding meningitis as a potential cause in patients with suspected infection. However, there is little literature evidence that gadolinium use can exclude underlying infection. We also used data from a single tertiary care center, which does not account for possible regional or institutional variation in the use of GBC for first-time pediatric seizures.

## CONCLUSIONS

Our study shows limited additive benefit of GBC in the imaging of pediatric patients with acute-onset seizures. These findings support reserving contrast use for specific clinical circumstances or when indicated by a finding on a noncontrast examination. More restrictive use of GBC in pediatric seizure imaging may be of particular importance in the pediatric population because the potential chronic adverse effects of GBC are not yet well-understood.

**Disclosure forms** provided by the authors are available with the full text and PDF of this article at [www.ajnr.org](http://www.ajnr.org).

## REFERENCES

1. Fiest KM, Sauro KM, Wiebe S, et al. **Prevalence and incidence of epilepsy: a systematic review and meta-analysis of international studies.** *Neurology* 2017;88:296–303 [CrossRef Medline](#)
2. Hauser WA, Annegers JF, Kurland LT. **Prevalence of epilepsy in Rochester, Minnesota: 1940–1980.** *Epilepsia* 1991;32:429–45 [CrossRef Medline](#)
3. Oka E, Ohtsuka Y, Yoshinaga H, et al. **Prevalence of childhood epilepsy and distribution of epileptic syndromes: a population-based survey in Okayama, Japan.** *Epilepsia* 2006;47:626–30 [CrossRef Medline](#)
4. Aaberg KM, Gunnes N, Bakken IJ, et al. **Incidence and prevalence of childhood epilepsy: a nationwide cohort study.** *Pediatrics* 2017;139:e20163908 [CrossRef Medline](#)
5. Russ SA, Larson K, Halfon N. **A national profile of childhood epilepsy and seizure disorder.** *Pediatrics* 2012;129:256–64 [CrossRef Medline](#)
6. Scheffer IE, Berkovic S, Capovilla G, et al. **ILAE classification of the epilepsies: position paper of the ILAE Commission for Classification and Terminology.** *Epilepsia* 2017;58:512–21 [CrossRef Medline](#)
7. Beghi E. **The epidemiology of epilepsy.** *Neuroepidemiology* 2020;54:185–91 [CrossRef Medline](#)
8. Cendes F, Theodore WH, Brinkmann BH, et al. **Neuroimaging of epilepsy.** *Handb Clin Neurol* 2016;136:985–1014 [CrossRef Medline](#)
9. Berg AT, Mathern GW, Bronen RA, et al. **Frequency, prognosis and surgical treatment of structural abnormalities seen with magnetic resonance imaging in childhood epilepsy.** *Brain* 2009;132:2785–97 [CrossRef Medline](#)
10. Bernasconi A, Cendes F, Theodore WH, et al. **Recommendations for the use of structural magnetic resonance imaging in the care of patients with epilepsy: a consensus report from the International League Against Epilepsy Neuroimaging Task Force.** *Epilepsia* 2019;60:2143–44 [CrossRef Medline](#)
11. Tellez-Zenteno JF, Hernandez Ronquillo L, Moien-Afshari F, et al. **Surgical outcomes in lesional and non-lesional epilepsy: a systematic review and meta-analysis.** *Epilepsy Res* 2010;89:310–18 [CrossRef Medline](#)
12. Semah F, Picot MC, Adam C, et al. **Is the underlying cause of epilepsy a major prognostic factor for recurrence?** *Neurology* 1998;51:1256–62 [CrossRef Medline](#)
13. Lee RK, Burns J, Ajam AA, et al; Expert Panel on Neurological Imaging. **ACR Appropriateness Criteria(R) Seizures and Epilepsy.** *J Am Coll Radiol* 2020;17:S293–304 [CrossRef Medline](#)
14. Blumfield E, Moore MM, Drake MK, et al. **Survey of gadolinium-based contrast agent utilization among the members of the Society for Pediatric Radiology: a Quality and Safety Committee report.** *Pediatr Radiol* 2017;47:665–73 [CrossRef Medline](#)
15. Lersy F, Boulouis G, Clément O, et al. **Consensus Guidelines of the French Society of Neuroradiology (SFNR) on the use of gadolinium-based contrast agents (GBCAs) and related MRI protocols in neuroradiology.** *J Neuroradiol* 2020;47:441–49 [CrossRef Medline](#)
16. McDonald RJ, McDonald JS, Kallmes DF, et al. **Intracranial gadolinium deposition after contrast-enhanced MR imaging.** *Radiology* 2015;275:772–82 [CrossRef Medline](#)
17. McDonald JS, McDonald RJ, Jentoft ME, et al. **Intracranial gadolinium deposition following gadodiamide-enhanced magnetic resonance imaging in pediatric patients: a case-control study.** *JAMA Pediatr* 2017;171:705–07 [CrossRef Medline](#)
18. McDonald RJ, Levine D, Weinreb J, et al. **Gadolinium retention: a research roadmap from the 2018 NIH/ACR/RSNA Workshop on Gadolinium Chelates.** *Radiology* 2018;289:517–34 [CrossRef Medline](#)
19. Nelson KA, Thaker AA, Callen AL, et al. **New-onset seizures in adults: low diagnostic yield of gadolinium contrast in initial brain MRI evaluation.** *J Neuroimaging* 2021;31:874–78 [CrossRef Medline](#)
20. Hourani R, Nasreddine W, Dirani M, et al. **When should a brain MRI be performed in children with new-onset seizures? Results of a large prospective trial.** *AJNR Am J Neuroradiol* 2021;42:1695–701 [CrossRef Medline](#)
21. Trofimova A, Milla SS, Ryan ME, et al; Expert Panel on Pediatric Imaging. **ACR Appropriateness Criteria® Seizures-Child.** *J Am Coll Radiol* 2021;18:S199–211 [CrossRef Medline](#)
22. Villanueva-Meyer JE, Mabray MC, Cha S. **Current clinical brain tumor imaging.** *Neurosurgery* 2017;81:397–415 [CrossRef Medline](#)
23. Kastrup O, Wanke I, Maschke M. **Neuroimaging of infections.** *NeuroRx* 2005;2:324–32 [CrossRef Medline](#)
24. Noda SM, Oztek MA, Stanescu AL, et al. **Gadolinium retention: should pediatric radiologists be concerned, and how to frame conversations with families.** *Pediatr Radiol* 2022;52:345–53 [CrossRef Medline](#)