



## Discover Generics

Cost-Effective CT & MRI Contrast Agents



FRESENIUS  
KABI

[VIEW CATALOG](#)

# AJNR

## Handbook of Neurosurgery, 6th ed.

*AJNR Am J Neuroradiol* published online 26 September 2007

<http://www.ajnr.org/content/early/2007/09/26/ajnr.A0722.citation>

This information is current as  
of September 1, 2025.

## BOOK REVIEW

**Handbook of Neurosurgery, 6th ed.**

M.S. Greenberg, ed. New York: Thieme Medical Publishers; 2006, 1000 pages, \$79.95.

This readily portable, 8 × 5-inch, 1000-page *Handbook of Neurosurgery* (6th ed) is jam-packed with information vital to every practicing neuroradiologist. It serves best to tuck this paperback book in a laboratory coat, so that quick consultation on patient evaluation, clinical management, and surgical approach is readily at hand. From a production standpoint, I have only 2 misgivings: 1) the tightly packed information has necessitated the use of a very small font size, so for those older than 40, reading glasses are a necessity, and 2) a somewhat annoying feature (becoming increasingly common in textbooks these days) is the frequent use of incomplete sentences. The presumption is that this is done to save space, but it makes for uneven reading. Although some features in this book are not useful for radiologists (eg, the front inside cover that serves as a quick reference for pediatric head size versus age, the back inside cover that serves as an eye chart pupil gauge or a centimeter ruler, and sections within the book that deal with drug treatment), the bulk of the book contains information that one can use virtually on a daily basis.

In the book, Chapter 1 deals with general neurosurgical care and includes sections on neuroanesthesia, critical care, fluid administration, hematology, and pharmacology; this information would be of passing interest only to neuroradiologists. Chapters 2, 3, and 4 entail neurology, neuroanatomy and physiology, and developmental anomalies. They describe a host of diseases and anomalies in a succinct manner and in a way most useful to neurosurgeons. For example, the clinical syndromes of abnormalities located in certain areas are summarized (various jugular foraminal syndromes, manifestations of parietal lobe dysfunction), nonsurgical neurologic disorders such as Guillain-Barré syndrome, amyotrophic lateral sclerosis, acute transverse myelitis (one could argue that his classification of “post trauma” as the cause of a myelitis is incorrect), parkinsonism (Parkinson disease and its variants such as olivopontocerebellar atrophy, progressive supranuclear palsy, and multiple system atrophy), dementias, multiple sclerosis and its various clinical categories/diagnostic criteria, and vasculopathies. For each disease, the summaries include clinical manifestations, pathophysiology, and treatment. For potential surgical options, the reader is referred to latter portions of the book. For example, after reading a description of parkinsonism, the reader can find information on related surgery 300 pages later in the book.

The section on anatomy provides a quick review of cranial and vascular anatomy, anatomy of the spine and

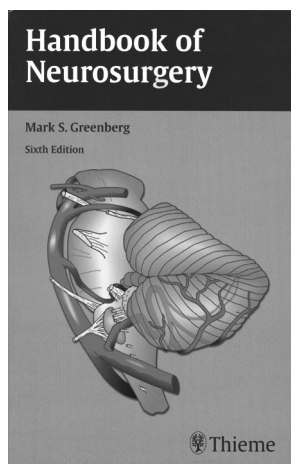
brain, and dermatomal organization along with physiologic conditions and neurologic disorders correlated with abnormalities of specific regions of the brain and spine. Developmental abnormalities include a full range of anomalies of the skull, brain, and spine. Charts summarize items such as signs and symptoms associated with Chiari malformations, various faciocranial dysmorphic syndromes, findings on neural tube defects, and surgical techniques used to care for these patients.

Chapter 5 covers neuroradiology in a brief fashion (without images, which is appropriate). In addition to a short description of the various imaging modalities, there are a couple of areas that radiologists can have “at their ready.” Subheadings include treatment of reactions to contrast agents, preparation schemes for patients with known allergies to contrast agents, aneurysmal clips and their MR compatibility, and a review of some of the measurements made on radiographs and CT (eg, basilar invagination, sellar size, and prevertebral soft tissue distances). Chapters 6 through 9 cover electrodiagnoses, neurotoxicology, coma (including the Glasgow Coma Scale), brain death, and CSF. The tables of CSF provide a quick reference of solute concentration, cells, and alterations of CSF in different diseases.

Chapter 10, which discusses hydrocephalus, is useful because it provides a handy summary of the various shunt types, including the most commonly used ones. Diagrams show the hardware components of the shunt, pressures associated with various settings, and names of the more popular shunts. Complications and shunt failures including infection, slit ventricles, and malfunction are described along with the steps taken when one taps a shunt to determine the adequacy of its function, remove fluid, or instill antibiotics or chemotherapeutic agents.

Chapter 12, a relatively extensive chapter on infections of the brain and spine, takes us from specific infections, to antibiotic and antiviral treatments, and through potential surgical management. For instance, the criteria for surgical versus medical management of cerebral abscesses are outlined. Even nonsurgical diseases such as herpes simplex encephalitis, AIDS, Creutzfeldt-Jakob disease, and Lyme disease are nicely summarized from a clinical and pathologic standpoint. Osteodiskitis and tuberculous epidural abscesses are considered from a medical standpoint and an operative approach. Although of limited interest to neuroradiologists, the chapter on seizures does discuss the classification scheme of seizures including subdivisions of generalized and partial seizures; however, most of this chapter deals heavily with the classifications of antiepileptic drugs and their usage.

In the chapter on the spine, cervical and lumbar procedures are described, but the chapter is unfortunately incomplete. For instance, a reasonable summary of potential hardware for fusion and stabilization is missing as is a description of a laminoplasty, an ever increasingly popular approach to cervical spine stenosis. The author describes spinal conditions such as ankylosing spondylitis, Paget disease, and rheumatoid arthritis, all of which are difficult to deal with from a surgical standpoint. The chapter on functional neurosurgery will be valuable to neuroradiologists because it shows where “nontraditional” surgical techniques are headed. Included are subheadings on the treatment of Parkinson disease, spasticity, hemifacial



spasm, tremors, hyperidrosis, and sympathectomy for various conditions.

As expected, the section on tumors comprises the largest portion of the book. Important, useful information is contained including the World Health Organization classification of tumors of the central nervous system, histologic features, survival rates, and frequency of occurrence. Other useful information consists of sensitivity to various treatment regimens, management of tumors of varying sizes, advantages and disadvantages of different approaches to strategically located masses, and complications and care of those complications. In addition, typical presenting symptoms for each tumor, tumor staging, classifications of pineal tumors, and many other features are discussed. The section on tumor markers serves to remind us of these prominent markers, both for histologic and clinical diagnosis. The section on spinal tumors (of the cord, canal, or column) is considered similar to that on brain tumors but is more abbreviated.

The last one third of the book deals with radiation therapy, stereotactic neurosurgery, the peripheral nervous system

(with excellent diagrams and laying out of muscular innervation), and the treatment of neuropathies and plexus and nerve injuries. It also covers entrapment syndromes, neuro-ophthalmology, neuro-otology, a summary of various cranial and spinal operations and approaches, and trauma to the head and spine. Also included in the last part are the evaluation and treatment of stroke, aneurysms (grading, types, management options, vasospasm treatment, and the timing of surgery and intervention), vascular malformations (classification, grading approach), and intracerebral hemorrhage. The final chapter lays out the differential diagnoses of many syndromes such as low back pain, sciatica, syncope, diplopia, cranial neuropathies, and tinnitus, among many others.

This book will serve as a comprehensive companion for all those in the clinical neurosciences. It covers the entire neurosurgical field and, because of that, is recommended as a reference book for all radiology department libraries. For those who work closely with neurosurgeons, having a copy of this book within easy reach is beneficial.

DOI 10.3174/ajnr.A0722