



Get Clarity On Generics

Cost-Effective CT & MRI Contrast Agents

**FRESENIUS
KABI**

[WATCH VIDEO](#)

AJNR



This information is current as
of August 9, 2025.

Embolization of Posterior Fossa Meningiomas Supplied with Meningohypophyseal Trunk by Using *n*-BCA and Dual Balloon Protection

Jota Tega, Koichiro Takemoto, Takayuki Koga, Dai
Kawano, Shintaro Yoshinaga, Hideaki Tanaka, Kei
Yamashiro, Toshiyuki Enomoto, Hironori Fukumoto,
Yoshinobu Horio, Hiromasa Kobayashi, Takashi Morishita,
Mitsutoshi Iwaasa and Hiroshi Abe

AJNR Am J Neuroradiol published online 17 October 2024
<http://www.ajnr.org/content/early/2025/03/20/ajnr.A8536>

Embolization of Posterior Fossa Meningiomas Supplied with Meningohypophyseal Trunk by Using *n*-BCA and Dual Balloon Protection

Jota Tega, Koichiro Takemoto, Takayuki Koga, Dai Kawano, Shintaro Yoshinaga, Hideaki Tanaka,  Kei Yamashiro, Toshiyuki Enomoto, Hironori Fukumoto, Yoshinobu Horio, Hiromasa Kobayashi, Takashi Morishita, Mitsutoshi Iwaasa, and  Hiroshi Abe



ABSTRACT

BACKGROUND AND PURPOSE: Efficacy of tumor embolization for posterior fossa meningioma is controversial due to the lack of adequate embolization for dangerous feeders. Of these, a meningohypophyseal trunk (MHT) has high therapeutic value despite the high risks associated with embolization.

MATERIALS AND METHODS: To analyze the utility of preoperative MHT embolization for posterior fossa meningiomas by using *n*-BCA with dual balloon protection, a single-center retrospective record review was performed on 8 consecutive patients who underwent preoperative tumor embolization via the MHT for posterior fossa meningiomas between 2020 and 2024.

RESULTS: In all cases the MHT was successfully embolized by using *n*-BCA. Complete obliteration was achieved in 5 cases, which is related to the tentorial artery alone as the feeding vessel. None of the patients had cerebral infarction associated with distal embolization. One patient experienced worsening of preoperatively observed abducens nerve palsy due to cranial nerve ischemia. Gross total resection was achieved in 7 of 8 cases. The mean estimated blood loss during surgical resection was 186 mL (range, 39–392 mL). The mean operative time was 431 minutes (range, 317–767 minutes).

CONCLUSIONS: The MHT embolization of posterior fossa meningiomas by using *n*-BCA is technically feasible with a high success rate and an acceptable complication rate.

ABBREVIATIONS: BGC = balloon guide catheter; CN = cranial nerve; GTR = gross total resection; ILT = inferolateral trunk; MHT = meningohypophyseal trunk; PVA = polyvinyl alcohol


In recent years, meta-analyses of case series and matched cohorts have shown that preoperative embolization for meningiomas is effective in reducing perioperative complications, improving postoperative functional outcomes, and prolonging the time to recurrence.^{1–4} However, the results for skull base meningiomas are still controversial and unsatisfactory: a systematic review showed a lower rate of adequate embolization of the feeding vessels (17%) and a higher complication rate due to the preoperative embolization (12%) than in nonskull base meningiomas.⁵ The main reason may be the lack of adequate embolization of dangerous feeders such as the ascending pharyngeal artery, the

meningohypophyseal trunk (MHT) and inferolateral trunk (ILT), the artery of the foramen rotundum, the accessory meningeal artery, and the anterior/petrosal branch of the middle meningeal artery.⁵ In particular, MHT and ILT originating from the ICA make insertion of a microcatheter difficult, such as the branching angle, curvature, and vessel diameter. The risk of cerebral infarction and cranial nerve (CN) impairment must also be considered. On the other hand, from a surgical approach (ie, retrosigmoid/transpetrosal), it is desirable for the surgeon if preoperative closure can be achieved because MHT and ILT are the deepest tumor feeding vessels and devascularization must be achieved at the end of surgery.⁶ The MHT, as the feeding vessel of the meningioma, was embolized with particulate in previous reports. However, the difficulty of navigating the particle-compatible microcatheter can decrease the success rate of endovascular devascularization preoperatively. We hypothesized that the use of smaller diameter microcatheters would increase the probability of introducing the microcatheter into the MHT. We performed embolization of the MHT by using *n*-BCA for posterior fossa meningiomas. We aimed to review our series and discuss safety and technical tips for the procedure from an anatomic perspective.

Received June 16, 2024; accepted after revision October 13.

From the Department of Neurosurgery (J.T., Y.H.), Fukuoka Seisyukai Hospital, Fukuoka, Japan; and Departments of Neurosurgery (K.T., T.K., D.K., S.Y., H.T., K.Y., T.E., H.K., T.M., H.A.), and Emergency and Critical Medicine (H.F., M.I.), Faculty of Medicine, Fukuoka University, Fukuoka, Japan.

Please address correspondence to Koichiro Takemoto, 7-45-1 Nanakuma, Jonan-ku, Fukuoka 814-0180, Japan; e-mail: take9016@gmail.com

 Indicates open access to non-subscribers at www.ajnr.org

 Indicates article with supplemental data.

<http://dx.doi.org/10.3174/ajnr.A8536>

SUMMARY

PREVIOUS LITERATURE: Efficacy of tumor embolization for posterior fossa meningioma is controversial due to the lack of adequate embolization for dangerous feeders. Of these, a MHT has high therapeutic value despite the high risks associated with embolization.

KEY FINDINGS: In all cases the MHT was successfully embolized by using *n*-BCA without cerebral infarction. One patient experienced worsening of abducens nerve palsy. Gross total resection was achieved in 7 cases. The mean blood loss during surgery was 186 mL (range, 39–392 mL). The mean operative time was 431 minutes (range, 317–767 minutes).

KNOWLEDGE ADVANCEMENT: The MHT embolization of posterior fossa meningiomas by using *n*-BCA is technically feasible with a high success rate and an acceptable complication rate.

MATERIALS AND METHODS

Study Design

We retrospectively reviewed consecutive patients who underwent preoperative tumor embolization via MHT for posterior fossa meningiomas at our institution between September 2020 and January 2024. Baseline data on the patients were collected, including age and sex, maximum tumor size, location, and venous sinus invasion of the tumor. Details of the anatomic character of MHT were evaluated, including the vessel size and branching angle based on 3D rotational angiography. Based on conebeam CT, we evaluated whether the feeding vessel was a tentorial artery, a dorsal meningeal artery, or both. In addition, procedural outcomes of the embolization were collected, including technical success, complete or incomplete obstruction of the MHT, and complications including cerebral infarction and CN impairment. Finally, surgical variables were collected, including estimated blood loss, gross total resection (GTR) of the tumor, and operative time. This study was approved by our institutional review board. All patients provided written informed consent for treatment, and we applied an opt-out approach for participation. This study has been reported in accordance with the Strengthening the Reporting of Observational Studies in Epidemiology statement.⁷

Embolization Procedure

All patients underwent angiography before endovascular treatment, and neurosurgeons and neurointerventionists discussed the decision to perform preoperative embolization and the goals of the procedure. Embolization was then performed under general anesthesia 1 or 2 days before resection. An 8F balloon guide catheter (BGC) was advanced to the internal carotid artery via the transfemoral approach. A 3.2F distal access catheter was advanced to the petrous segment of the ICA from the guiding catheter. For embolization, a 1.3F DeFractor (Medico's Hirata) soft microcatheter was navigated to the MHT over a CHIKAI X10 soft microwire (Asahi Intech). The MHT typically arises from the posterior vertical cavernous segment of the ICA, and runs almost inverted against the ICA. Furthermore, due to its being thin and bent, it is difficult to catheterize. Therefore, after the microguidewire was inserted into the MHT, we used a balloon catheter to fix the microguidewire to the ICA wall to prevent the microguidewire from deviating into the distal ICA. The balloon catheter was left dilated, and we followed the tip of the microcatheter to the origin of the MHT, and carefully inserted the microguidewire more distally, and the

microcatheter was advanced to the depth of the MHT (Fig 1). After super selective angiography to verify the catheter's appropriate position and lack of dangerous anastomoses leading to cerebral infarction, the embolization was performed by using *n*-BCA (B-Braun Aesculap) diluted in 12.5%–33%. Before *n*-BCA injection, both the BGC and balloon catheter were inflated. We first dilated the BGC, and then dilated the balloon catheter to prevent the distal migration of injected glue into the ICA (Fig 1). After the *n*-BCA injection, the DeFractor microcatheter was removed followed by deflating the balloon catheter. Aspiration from the BGC was performed by using a 20 mL syringe at least twice. Finally, the BGC was deflated. At the end of the embolization, conventional angiography and conebeam CT were performed to confirm no evidence of obvious cerebral infarction and or intracranial hemorrhage.

RESULTS

Among 15 preoperative embolizations for posterior fossa meningiomas performed between 2020 and 2024, we identified 8 patients who agreed to our performing embolization of the MHT preoperatively (Supplemental Data). MHT embolization was successfully achieved in all patients by using the previously described method. The mean diameter of the MHT was 1.0 mm (range, 0.52–1.45 mm), and the mean branching angle of the MHT from the ICA was 118° (range, 50°–155°). Among the 8 cases, the tentorial artery alone was the feeding vessel in 5 cases, and both the tentorial artery and the dorsal meningeal artery were feeding vessels in the remaining 3 cases. Complete obliteration was obtained in the first 5 cases (ie, supplied with the tentorial artery alone) (Supplemental Data). None of the patients had cerebral infarction associated with distal embolization. One patient experienced a worsening of preoperatively observed abducens nerve palsy due to CN ischemia. Regarding the tumoral character, the mean maximum tumor diameter was 30.6 mm (range, 22–49 mm), and the tumor attachment sites were the petroclival in 6 cases and cerebellopontine angle in 2 cases. Among them, the transpetrosal approach was selected in 5 cases, and the retrosigmoid approach in 3 cases. GTR was achieved in 7 of 8 cases. The mean estimated blood loss during surgical resection was 186 mL (range, 39–392 mL). The mean operative time was 431 minutes (range, 317–767 minutes).

DISCUSSION

The first-line embolic material for meningioma embolization is particulate; however, the use of *n*-BCA is increasing. In recent

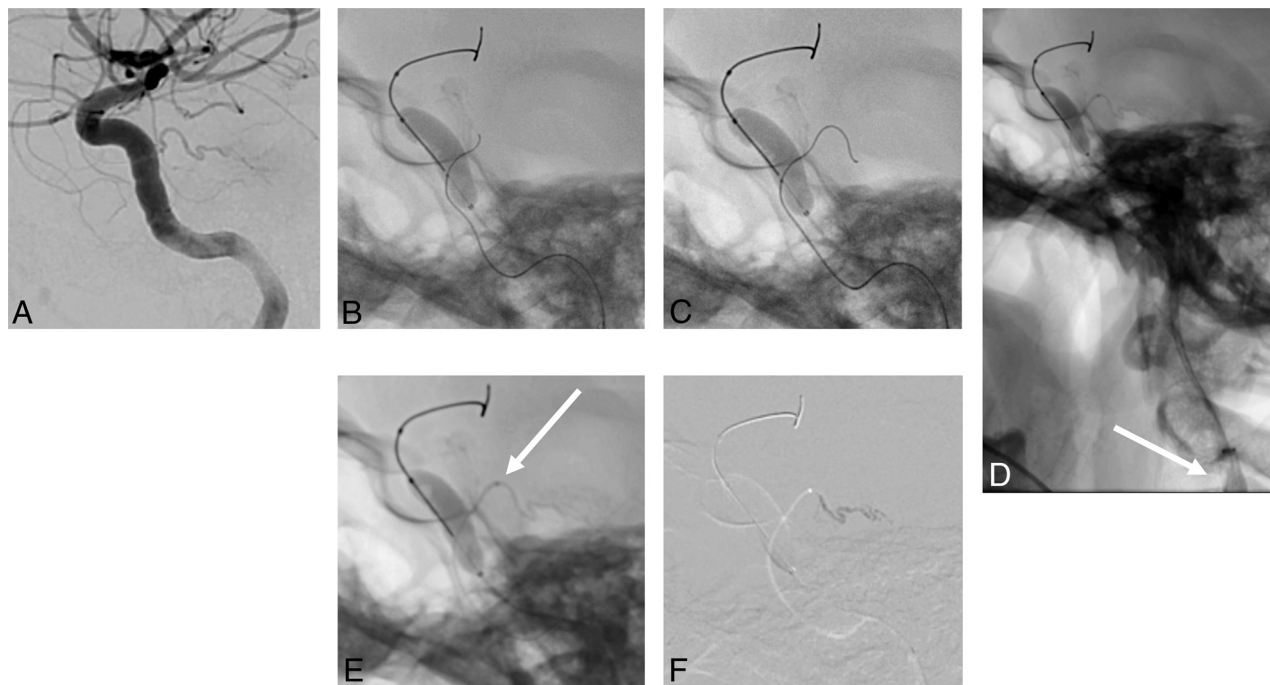


FIG 1. Internal carotid angiogram (*lateral view*) showed supply to the tumor from the enlarged MHT (A). After the CHIKA I X10 microguidewire was inserted into the MHT, Scepter C balloon catheter was inflated to fix the CHIKA I X10 to the ICA wall to prevent it from deviating into the distal ICA (B). The Scepter C balloon catheter was left dilated, and the tip of the DeFrictor nano microcatheter was advanced to the MHT origin. We then carefully inserted the CHIKA I X10 to the depth of the MHT (C). Superselective angiography via the DeFrictor nano (*white arrow*) shows fluoro marker located 5 mm proximal to the tip of microcatheter. The catheter tip was non-braded for 5 mm from the tip to provide flexibility (D). Both the BGC (*white arrow*) and balloon catheter were inflated to prevent the distal migration of injected glue into the ICA (E). Twenty-five percent *n*-BCA was injected for feeder occlusion (F).

years, large case series of meningioma embolization by using *n*-BCA have shown a low complication rate and a reduction in intraoperative blood loss.^{8,9} In addition, a comparative study between *n*-BCA and particles used for intracranial tumor embolization showed no difference in complication rates.¹⁰ Suzuki et al¹¹ conducted a retrospective evaluation for their 20 skull base meningiomas treated with *n*-BCA, which showed high technical success without permanent complications. The present study is the first report to focus on MHT embolization by using *n*-BCA for posterior fossa meningiomas.

MHT Embolization Using Particle

Several prior series of tumor embolization targeting the MHT and ILT have reported excellent outcomes: Hirohata et al¹² with 7 cases by using polyvinyl alcohol (PVA) 250–350 μ m and no complications; Robinson et al¹³ with 5 cases by using PVA 150–250 μ m and no complications; Raz et al¹⁴ with 14 cases by using 45–250 μ m PVA and no complications; and Waldron et al¹⁵ with 10 cases by using PVA, coil, and microsphere and no complications. In the present series, we embolized the MHT by using 12.5%–33% *n*-BCA in 8 cases; there was a single complication with worsening of an already present abducens nerve palsy. However, the advantage of the present technique is a higher success rate than the previous reports. The tumor embolization from the MHT and ILT might raise 2 concerns: a reflux of embolic material into the parent ICA that can lead to embolic infarcts within ICA territory and a risk of CN ischemia due to embolic occlusion

of vasa nervorum that is commonly supplied by these vessels.¹⁴ Previous authors seem to be reluctant to use the *n*-BCA as an embolic material, which can lead to CN ischemia due to the high permeability. Another reason for the reluctance is that the feeding vessels of the skull base meningioma, including the MHT and ILT, potentially anastomose with the other meningeal arteries.¹⁴ *n*-BCA can lead to a leak into the cerebral arteries, such as the ICA and vertebral artery, via these meningeal arteries with a rich vascular network. Therefore, many authors recommend using particles, including PVA and microspheres, as the safest embolic material for the embolization of skull base meningiomas. Likewise, we consider large-sized particles (ie, microspheres 300–500 μ m) as the safest material. A medial tentorial artery and a medial branch of the dorsal meningeal artery branching from MHT are known to have vasa nervorum, each feeding the oculomotor/trochlear nerve and abducens nerve.¹⁶ The vasa nervorum consists of 2 functionally independent systems, extrinsic and intrinsic vessels, which serve to supply the peripheral nerve to maintain its structural and functional requirements. The extrinsic vessels are located outside of the perineurium, and segmentally branch into radicular vessels, which supply the intrinsic vessels. The former is believed to have some collateral circulation, while the latter is not expected to have collateral circulation, and its vessel diameter is reported to be 100–200 μ m.¹⁷ Hence, caution should be exercised in the use of small particles less than 300 μ m. Large particles are safe; however, their use requires more than 1.6F microcatheters. Raz et al¹⁴ used a 1.6F Headway Duo microcatheter (MicroVention; inner diameter is 0.0165 inch), which

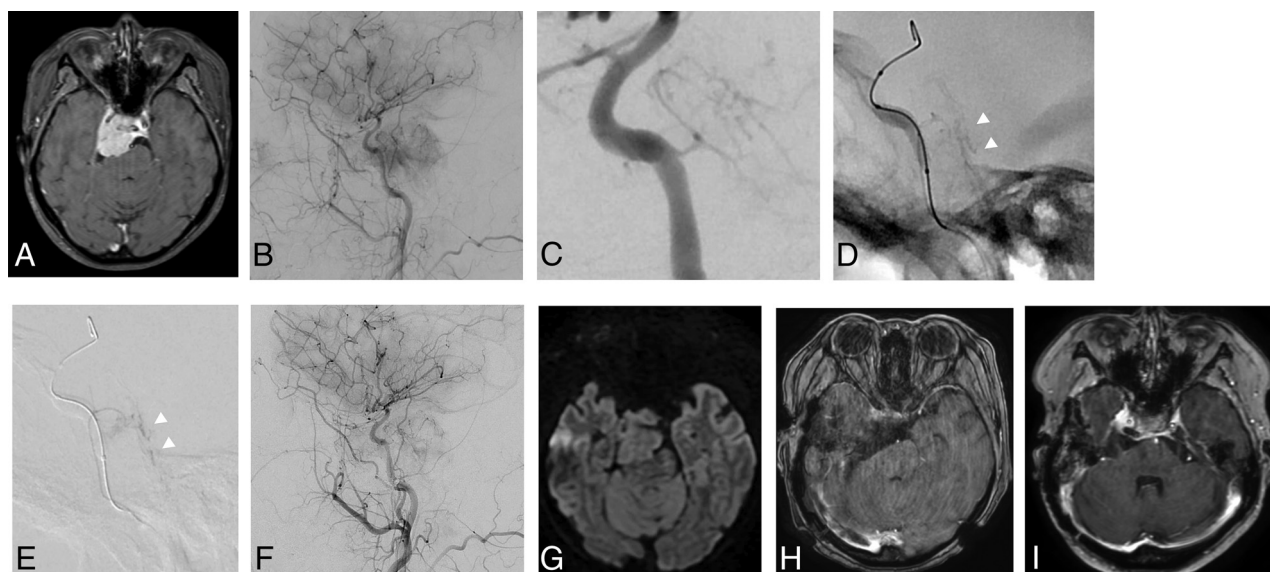


FIG 2. Adult patient with petroclival meningioma on gadolinium (Gd)-T1WI (A). Right common carotid angiogram (*lateral view*) showed supply to the tumor from the enlarged MHT (B). Both the tentorial artery and the dorsal meningeal artery were feeding vessels (C). A total of 12.5% *n*-BCA penetrated into the dural attachment of the tumor (*arrowheads*) via the dorsal meningeal artery (D and E). Postprocedural angiogram showed a partial obliteration of the feeding vessels (F). Postprocedural diffusion-weighted image showed no evidence of intratumoral ischemia and cerebral infarction (G). Postoperative Gd-T1WI showed a partial removal of the tumor (H). The 9-month follow-up Gd-T1WI showed a small recurrence on the wall of the right cavernous sinus (I).

was the smallest diameter catheter in the series using particulate. The particle-compatible microcatheter limits the proper vessels that can be navigated, and it requires care to ensure that the catheter does not become wedged in position so that the particles can penetrate into the tumor in the bloodstream without reflux.¹⁴ Such favorable conditions are likely to be limited: prior authors have reported low success rates (range, 32.1%–36%) when cannulating microcatheters into the MHT.^{15,18}

MHT Embolization Using *n*-BCA and Dual Balloon Protection

The advantage of MHT embolization with *n*-BCA was the high success rate of navigating the target vessel by using smaller diameter microcatheters. We used 1.3F DeFrictor Nano catheters over the Chikai X10 microguidewires, which were navigable even into narrow and tortuous vessels. The balloon catheters were useful in preventing the microguidewires and microcatheters from deviating into the distal ICA. Because the balloon catheters could interfere with the microguidewires (ie, Chikai X10) and sometimes made it difficult to navigate the microguidewires into the MHT, we advanced the balloon catheters to the cavernous portions from the petrous portions of the ICA after insertion of the tips of the microguidewires into the MHT. To prevent the distal migration of injected glue into the ICA, we used dual balloon protection (ie, balloon catheter and BGC). The reason for this is that glue can damage the balloon, which is inflated by the cavernous portion of the ICA. In these situations, the BGC acts as an airbag: In the unlikely event of balloon failure in the cavernous portion, the blockage of blood flow to the ICA by the BGC will prevent distal embolization of liquid embolic material to the ICA.

It is also useful to prevent glue attached to the tip of the microcatheter from migrating into the ICA when the microcatheter is removed. The drawbacks of this technique should also be discussed. The MHT has 3 branches (ie, tentorial, inferior

hypophyseal, and dorsal meningeal artery), most form a common trunk, however, their range is very short and they branch out soon. When the MHT as a feeding vessel has multiple branches (ie, both the tentorial artery and the dorsal meningeal artery), it seems to lead to incomplete occlusion. In such cases, the microcatheter is usually inserted into 1 of the 2 branches and blood flow is maintained in the branch that is not inserted. On the other hand, to reduce complications, it is desirable to advance the microcatheter tip as far into the tumor as possible during tumor embolization by using *n*-BCA. Therefore, a particle may be most effective as an embolic material if both a tentorial artery and a dorsal meningeal artery are developed as tumor feeders, and the MHT is thick enough to navigate a more than 1.6F microcatheter. Regarding *n*-BCA concentration, we currently believe that embolization with medium concentration (ie, 25%–33%) of *n*-BCA aimed at feeder occlusion is safer than low concentration of *n*-BCA. In our prior series of tumor embolization for the convexity meningiomas, we reported the efficacy of 10%–12.5% *n*-BCA with high penetration and necrotic changes of the tumor.¹⁹ The ultra-low concentration of *n*-BCA easily penetrates the tumor and even the dura mater at the site of tumor attachment, which connects with the normal meningeal artery at the tentorium and clivus. In our case, in which we used 12.5% *n*-BCA for petroclival meningioma with rich tumor vessel, the glue penetrated into the dural attachment of the tumor: the deeply penetrated glue could lead to CN ischemia (Fig 2). Therefore, caution seems to be needed as aggressive embolization by using ultra-low concentration *n*-BCA for skull base meningiomas can lead to CN ischemia due to embolic occlusion of vasa nervorum.

Limitations

This study was conducted at a single institution and the number of cases was small. Although our surgical outcomes were

acceptable (ie, relatively low blood loss, short operative time, and high rate of GTR), to demonstrate the true benefit of MHT embolization, comparisons with nonembolized cases and statistical studies by using a matched cohort are needed. Furthermore, we observed only 1 recurrent case in this series. Preoperative embolization of meningiomas may decrease recurrence rates. However, the results for skull base meningiomas are completely unclear, and continued accumulation and tracking of cases is needed.

As mentioned above, embolic agents should be selected according to the form of MHT, and further experience with these selection criteria is needed. So far, if the MHT is thick enough to pass through a 1.6F or larger microcatheter, the conventional method by using large particles is recommended as the first choice. Our method may be useful as an alternative when these large-diameter catheters are difficult to navigate. In addition, for extremely thin MHT/ILT cases that are difficult to treat even with our method, a distal balloon protection technique can be considered as salvage method.¹⁴ We used the BGC to avoid distal migration of *n*-BCA, and have not experienced thromboembolic complications. However, a prior series of tumor embolization targeting the MHT and ILT had achieved same result without BGC. Further study (ie, case-control study) will be needed to elucidate the usefulness of the BGC.

CONCLUSIONS

MHT embolization of posterior fossa meningiomas by using *n*-BCA and a dual balloon catheter is a useful technique with a high procedural success rate. The microcatheter tip should be advanced as far into the tumor as possible, and dual balloon protection should be used to ensure prevention of reflux and migration of glue into the ICA. Using a medium to high concentration of *n*-BCA aimed at feeder occlusion may be useful in reducing the frequency of CN ischemia.

ACKNOWLEDGMENTS

The authors would like to thank Stephen Boyes for the English editing.

Disclosure forms provided by the authors are available with the full text and PDF of this article at www.ajnr.org.

REFERENCES

1. Yin Y, Li Y, Jiang Z, et al. **Clinical outcomes and complications of reoperative embolization for intracranial giant meningioma tumor-ectomy: a retrospective, observational, matched cohort study.** *Front Oncol* 2022;12:852327 [CrossRef Medline](#)
2. Akimoto T, Ohtake M, Miyake S, et al. **Preoperative tumor embolization prolongs time to recurrence of meningiomas: a retrospective propensity-matched analysis.** *J Neurointerv Surg* 2023;15:814–20 [CrossRef Medline](#)
3. Scharzt D, Furst T, Ellens N, et al. **Preoperative embolization of meningiomas facilitates reduced surgical complications and improved clinical outcomes: a meta-analysis of matched cohort studies.** *Clin Neuroradiol* 2023;33:755–62 [CrossRef Medline](#)
4. Przybylowski CJ, Zhao X, Baranoski JF, et al. **Preoperative embolization versus no embolization for WHO grade I intracranial meningioma: a retrospective matched cohort study.** *J Neurosurg* 2021;134:693–700 [CrossRef Medline](#)
5. Ilyas A, Przybylowski C, Chen CJ, et al. **Preoperative embolization of skull base meningiomas: a systematic review.** *J Clin Neurosci* 2019;59:259–64 [CrossRef Medline](#)
6. Yoon N, Shah A, Couldwell WT, et al. **Preoperative embolization of skull base meningiomas: current indications, techniques, and pearls for complication avoidance.** *Neurosurg Focus* 2018;44:E5 [CrossRef Medline](#)
7. von Elm E, Altman DG, Egger M; STROBE Initiative, et al. **The Strengthening the Reporting of Observational Studies in Epidemiology (STROBE) statement: guidelines for reporting observational studies.** *Lancet* 2007;370:1453–57 [CrossRef Medline](#)
8. Ishihara H, Ishihara S, Niimi J, et al. **The safety and efficacy of preoperative embolization of meningioma with N-butyl cyanoacrylate.** *Interv Neuroradiol* 2015;21:624–30 [CrossRef Medline](#)
9. Omura N, Hiramatsu R, Yagi R, et al. **Comparison of outcomes with/without preoperative embolization for meningiomas with diluted N-butyl-2-cyanoacrylate.** *Clin Neurol Neurosurg* 2024;238:108178 [CrossRef Medline](#)
10. Iida Y, Akimoto T, Miyake S, et al. **Differences and advantages of particles versus liquid material for preoperative intracranial tumor embolization: a retrospective multicenter study.** *J Neuroendovasc Ther* 2024;18:110–18 [CrossRef Medline](#)
11. Suzuki K, Nagaishi M, Matsumoto Y, et al. **Preoperative embolization for skull base meningiomas.** *J Neurol Surg B Skull Base* 2017;78:308–14 [CrossRef Medline](#)
12. Hirohata M, Abe T, Morimitsu H, et al. **Preoperative selective internal carotid artery dural branch embolisation for petroclival meningiomas.** *Neuroradiology* 2003;45:656–60 [CrossRef Medline](#)
13. Robinson DH, Song JK, Eskridge JM. **Embolization of meningohypophyseal and inferolateral branches of the cavernous internal carotid artery.** *AJNR Am J Neuroradiol* 1999;20:1061–67 [Medline](#)
14. Raz E, Cavalcanti DD, Sen C, et al. **Tumor embolization through meningohypophyseal and inferolateral trunks is safe and effective.** *AJNR Am J Neuroradiol* 2022;43:1142–47 [CrossRef Medline](#)
15. Waldron JS, Sughrue ME, Hetts SW, et al. **Embolization of skull base meningiomas and feeding vessels arising from the internal carotid circulation.** *Neurosurgery* 2011;68:162–69 [CrossRef Medline](#)
16. Martins C, Yasuda A, Campero A, et al. **Microsurgical anatomy of the dural arteries.** *Neurosurgery* 2005;56:211–51 [CrossRef Medline](#)
17. Boissaud-Cooke M, Pidgeon TE, Tunstall R. **The microcirculation of peripheral nerves: the vaso nervorum.** In: *Nerves and Nerve Injuries*. 2015:507–23
18. Yamashiro K, Hayakawa M, Adachi K, et al. **Tumor embolization via the meningohypophyseal and inferolateral trunk in patients with skull-based tumors by using the distal balloon protection technique.** *AJNR Am J Neuroradiol* 2024;45:618–25 [CrossRef Medline](#)
19. Aihara M, Naito I, Shimizu T, et al. **Preoperative embolization of intracranial meningiomas using n-butyl cyanoacrylate.** *Neuroradiology* 2015;57:713–19 [CrossRef Medline](#)