

Get Clarity On Generics

Cost-Effective CT & MRI Contrast Agents



FRESENIUS
KABI

WATCH VIDEO

AJNR

This information is current as
of August 24, 2025.

Implementation of a Survey Spine Magnetic Resonance Imaging Protocol for Cord Compression in the Emergency Department: Experience at a Level-1 Trauma Center

Mercy H. Mazurek, Annie R. Abruzzo, Alexander H. King, Erica Koranteng, Grant Rigney, Winston Lie, Shahaan Razak, Rajiv Gupta, William A. Meehan, Michael H. Lev, Joshua A. Hirsch, Karen Buch and Marc D Succi

AJNR Am J Neuroradiol published online 3 May 2024
<http://www.ajnr.org/content/early/2024/05/03/ajnr.A8326>

Implementation of a Survey Spine Magnetic Resonance Imaging Protocol for Cord Compression in the Emergency Department: Experience at a Level-1 Trauma Center

Mercy H. Mazurek, Annie R. Abruzzo Alexander H. King MS, Erica Koranteng, Grant Rigney, Winston Lie, Shahaan Razak, Rajiv Gupta, William A. Meehan, Michael H. Lev, Joshua A. Hirsch, Karen Buch, Marc D Succi

ABSTRACT

BACKGROUND AND PURPOSE: Imaging stewardship in the emergency department (ED) is vital in ensuring patients receive optimized care. While suspected cord compression (CC) is a frequent indication for total spine MRI in the ED, the incidence of CC is low. Recently, our level-I trauma center introduced a survey spine MRI protocol to evaluate for suspected CC while reducing exam time to avoid imaging overutilization. This study aims to evaluate the time savings, frequency of ordering patterns of the survey, and the symptoms and outcomes of patients undergoing the survey.

MATERIALS AND METHODS: This retrospective study examined patients who received a survey spine MRI in the ED at our institution between 2018 and 2022. All exams were performed on a 1.5T GE scanner using our institutional CC survey protocol, which includes sagittal T2 and STIR sequences through the cervical, thoracic, and lumbar spine. Exams were read by a blinded, board-certified neuroradiologist.

RESULTS: A total of 2,002 patients received a survey spine MRI protocol during the study period. Of these patients, 845 (42.2%, mean age 57 ± 19 years, 45% female) received survey spine MRI exams for the suspicion of CC, and 120 patients (14.2% positivity rate) had radiographic CC. The survey spine MRI averaged 5 minutes and 50 seconds (79% faster than routine MRI). On multivariate analysis, trauma, back pain, lower extremity weakness, urinary or bowel incontinence, numbness, ataxia, and hyperreflexia were each independently associated with CC. Of the 120 patients with CC, 71 underwent emergent surgery, 20 underwent non-emergent surgery, and 29 were managed medically.

CONCLUSIONS: The survey spine protocol was positive for CC in 14% of patients in our cohort and acquired at a 79% faster rate compared to routine total spine. Understanding the positivity rate of CC, the clinical symptoms that are most associated with CC, and the subsequent care management for patients presenting with suspected cord compression who received the survey spine MRI may better inform the broad adoption and subsequent utilization of survey imaging protocols in emergency settings to increase throughput, improve allocation of resources, and provide efficient care for patients with suspected CC.

ABBREVIATIONS: CC, cord compression; ED, emergency department; MRI, magnetic resonance imaging; T2; T2-weighted imaging sequence; STIR, short TI inversion recovery.

Received month day, year; accepted after revision month day, year.

From the Harvard Medical School, Boston, MA (M.H.M., A.R.A., A.H.K., E.K., G.R., W.L., S.R., R.G., W.A.M., M.H.L., J.A.H., K.B., M.D.S.), Medically Engineered Solutions in Healthcare Incubator, Innovation in Operations Research Center (MESH IO), Massachusetts General Hospital, Boston, MA (M.H.M., A.R.A., A.H.K., E.K., G.R., W.L., S.R., R.G., W.A.M., M.H.L., J.A.H., K.B., M.D.S.), Department of Radiology, Massachusetts General Hospital, Boston, MA (R.G., W.A.M., M.H.L., J.A.H., K.B., M.D.S.).

All authors declare no conflicts of interest related to the content of this article. MDS is the Founder and CEO, 2 Minute Medicine, Inc. Inventor, patents licensed to Frequency Therapeutics. President, Isernia Labs, LLC. RG would like to disclose the following interests that are unrelated to the current paper: Scientific Advisory Board: Bayer HealthCare LLC, BrainTale Inc, Agfa HealthCare Inc; Speaker honorarium: Siemens Medical Solutions, USA; Research Grant: Samsung Healthcare; Consulting: Idorsia, Inc, Medtronic Inc, US Attorney's Office, District of Colorado.

Please address correspondence to Marc D. Succi, MD, Department of Radiology, Massachusetts General Hospital, 55 Fruit Street, Boston, MA 02114, USA; msucci@mgh.harvard.edu

SUMMARY SECTION

PREVIOUS LITERATURE: Imaging stewardship is essential in ensuring patients receive high-quality, efficient care while avoiding unnecessary studies and their associated costs. An area of focus is the increasing use of spine magnetic resonance imaging (MRI) for the acute detection of cord compression (CC). Despite the powerful diagnostic capabilities of MRI for CC, the long examination and image interpretation times hinders its broad application. Rapid MRI protocols has been posited as a solution to reduce imaging time while screening for specific indications. Our center developed a rapid survey spine MRI protocol to evaluate the total spine for the specific clinical indication of CC.

KEY FINDINGS: The survey spine protocol was positive for cord compression in 14% of patients in our cohort, acquired at a 79% faster rate compared to routine total spine, and 59% underwent emergent surgery. Presenting symptoms associated with CC included trauma, back pain, lower extremity weakness, urinary/bowel incontinence, numbness, ataxia, and hyperreflexia,

KNOWLEDGE ADVANCEMENT: Our survey spine protocol detected CC at a 79% faster compared to routine total spine MRIs. Understanding the survey utilization and characteristics of the population receiving the survey may inform the adoption of rapid imaging protocols to decrease acquisition times and provide efficient care for patients with suspected CC.

INTRODUCTION

Imaging stewardship in the emergency department is essential in ensuring patients receive high-quality, efficient care while avoiding unnecessary studies and their associated costs (1-5). An area of focus is the increasing use of spine magnetic resonance imaging (MRI) in the emergency department (6-12). Spine MRIs are commonly used to diagnose spinal injuries including cord compression (CC), which is a critical, time-sensitive diagnosis that often requires emergent surgery, radiation therapy, and/or medical management given that untreated, cord compression will result in permanent neurological damage (9-13).

Despite prior studies citing a low incidence rate for CC of 0.5% to 5%, total spine MRI examinations are the current standard of care for those suspected of possibly having an underlying correctable cause given the potentially devastating consequences (6, 14-18). Patients may present with a broad range of symptoms including back pain, radiculopathy, paresthesia, weakness, and urinary retention. The acquisition of a spine MRI provides unsurpassed insight into the diagnosis of CC by allowing for visualization of the spinal cord to identify potential causes, such as extrinsic compression of the cord by tumors, traumatic injury, a herniated disk, spondylosis, infection and/or degenerative spine disease (9-13,19). Furthermore, assessing the degree and localization of compression is critical to plan treatment and decision-making, especially regarding potentially emergent surgical decompression (8, 13, 20, 21).

Studies investigating the utility of imaging in the ED have suggested that as much as 22% of emergency department imaging studies may be unnecessary, resulting in increased healthcare costs, medical error, and potentially causing harm to patients (22-24). Despite the powerful diagnostic capabilities of MRI for CC, the long examination and image interpretation times hinder the ease of broad application of MRI for emergent conditions (25). Moreover, MRI scanners and the infrastructure needed to safely house them are expensive and labor-intensive, rendering them less accessible in the emergency setting (26). Recently, rapid MRI protocols have been posited as a solution to long acquisition times associated with routine MRI. These protocols are focused for a specific clinical indication and have a reduced number of sequences and imaging time (25, 27-29).

Objective

Our level-I trauma center implemented a rapid survey spine MRI protocol to reduce exam times while still maintaining the ability to detect the features associated with CC. The main difference between the cord compression survey and a routine total spine MRI is the lack of sagittal T1-weighted imaging of the spine and complete axial imaging stacks. The core sequences of the cord compression survey are sagittal T2 and STIR sequences for the assessment of canal compromise and potential cord signal abnormality. This study aims to evaluate the frequency of ordering patterns of the survey, the symptoms and outcomes of patients undergoing the survey, and its time savings.

MATERIALS AND METHODS

Study Design, Setting, and Population

This is a retrospective, observational cohort study that was conducted at a large urban academic medical center with a level I trauma center from January 2018 to December 2022. All patients presenting to the ED who received a survey spine MRI protocol for the clinical suspicion of cord compression were included. The study was compliant with the Health Insurance Portability and Accountability Act and approved with exemption by our Institutional Review Board.

Survey Spine MRI Protocol

Our institution's survey spine MRI protocol included sagittal T2 and STIR sequences through the cervical, thoracic, and lumbar spine. All survey MRIs were reviewed by a neuroradiology fellow or attending before the exam was completed with axial T2 sequences prescribed only at the discretion of the neuroradiologist if there was an area of concern on the sagittal views that the neuroradiologist wanted to view on axial for further evaluation. For instance, if the neuroradiologist suspected at least moderate spinal canal stenosis, moderate foraminal stenosis, or impingement of a nerve root based on the information from the sagitta exams, axial slices were obtained. These cases could have near complete or complete effacement of the ventral or dorsal cerebrospinal fluid spaces or any sort of disc extrusion or lateral protrusion that may have impinged on a nerve root or had foraminal extension was present. All survey spine exams were performed on a 1.5T GE scanner (GE Healthcare Clinical Systems, Wauwatosa, WI, USA). Survey spine MRI sequence parameters are outlined in Table 1.

Table 1. Sequence Parameters for the Survey Spine MRI Protocol.

Sequences	T2-Weighted Imaging (T2W)			Short Tau Inversion Recovery (STIR)		
	Cervical	Lumbar	Thoracic	Cervical	Lumbar	Thoracic
TR/TE (ms)	2782/85.1	2000/107.8	3864/108.2	5207/49.5	3856/48.3	4903/49.7
NEX	2	0.5	1.5	1.5	1.5	1.5
Flip Angle	160	160	160	170	170	170

Matrix	288x220	288x256	288x224	288 x 192	288 x 192	288 x 192
FOV (mm2)	210 x 210	280x280	340x340	200 x 200	280 x 280	350 x 350
Slice Thickness (mm)	3	3	4	3	4	3
Slice Spacing (mm)	3.5	3	5	3.5	4	3
Acquisition Time	3 min, 31 sec	3 mins, 51 sec	3 min, 48 sec	1 min, 38 sec	2 min, 28 sec	1 min, 44 sec

Variables

The primary outcome in this study was defined as the rate of CC-positive survey spine MRI examinations in all patients receiving a survey spine MRI and the time savings of the survey compared to routine total spine MRI. Secondary outcomes included the assessment of presenting symptoms in all patients receiving the survey and the outcomes for patients who received a positive study. A CAQ-certified neuroradiologist (with greater than 5 years of experience) read the radiographic images for the purposes of this study. The exams were characterized as one of three categories: (1) no radiographic findings, (2) chronic degenerative findings without severe spinal canal stenosis, and (3) severe spinal canal stenosis including acute and chronic cord compression. A positive exam was qualified as an exam resulting in severe spinal canal stenosis including acute and chronic cord compression. Demographic variables were also collected from the electronic medical record, including age, sex, and self-reported race.

Statistical Methods

Continuous data are presented as means and standard deviations or medians and interquartile ranges, as appropriate; categorical data are reported as counts and percentages. Univariate analysis was performed using the chi-squared test. A multivariate logistic regression was performed with stepwise backwards elimination where the variable with the largest P value was removed in a stepwise fashion in each iteration until all variables on the final model had a P<.05. Statistical significance was set at P<.05. All statistical computations were completed using Stata version 18 (Stata corporation, College Station, TX).

RESULTS

Study Population and Demographics

A total of 845 patients (42.2%, mean age 57 ± 19 years, 45% female) received a survey spine MRI protocol for the suspicion of CC. Patient demographics and examination characteristics are compiled in Table 2.

Table 2. Patient Demographics

Characteristic	
Total patients, n	845
Age, median (IQR)	60 (44-72)
Sex, n (%)	
Female	381 (45%)
Male	463 (55%)
Race, n (%)	
American Indian/Alaskan Native	3 (0.4%)
Asian	21 (2.5%)
Black or African American	74 (8.8%)
White	653 (77.3%)
Unknown/Other	63 (7.5%)
Interpreter Required, n (%)	72 (8%)

Examination Year, n (%)	
2018	183 (21.7%)
2019	156 (18.5%)
2020	142 (16.8%)
2021	193 (22.8%)
2022	171 (20.2%)
Clinical Presentation, n (%)	
Trauma	195 (23.0%)
Malignancy	48 (5.7%)
Lower Extremity Weakness	437 (51.7%)
Back Pain	468 (55.3%)
Neck Pain	120 (14.2%)
Bladder Incontinence or Retention	119 (14.1%)
Sensory Changes	168 (19.9%)
Ataxia or Gait Abnormality	62 (7.3%)
Order to Scan Initiation (min), median (range)	189 (5-56,142)
Scan Initiation to Scan End (min), median (range)	46 (28-786)
Time to Exam Interpretation (min), median (range)	80 (4-2276)

Time Savings of Survey Spine MRI

The survey spine MRI averaged 5 minutes and 50 seconds compared to an average time of 27 minutes and 13 seconds for routine total spine MRI during the same period, resulting in 22 minutes and 27 seconds saved per exam (79% faster compared to routine).

Positivity Rate of Cord Compression on Survey Spine MRI

Of the 845 patients who received a protocol for CC, 396 patients (47%) had no radiographic findings, 329 patients (39%) had chronic degenerative findings without severe spinal canal stenosis, and 120 patients (overall positivity rate = 14.2%) had severe spinal canal stenosis including acute and chronic cord compression. Across the study period, positivity rate increased from 13.7% (n=25/183) in 2018 to 16.4% (n=28/171) in 2022, representing a 19.7% increase (Figure 1 and Figure 2).

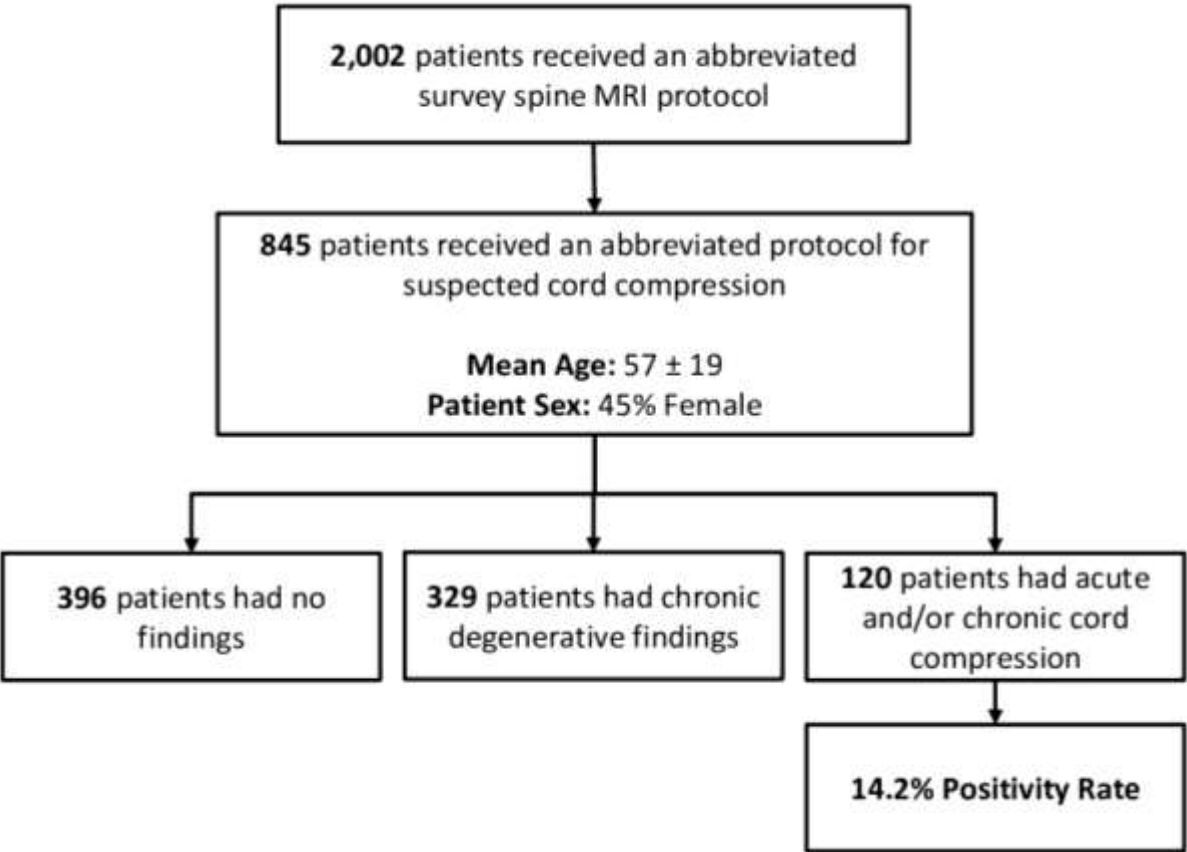


Figure 1. Overall Five-year Positivity Rate for Study Population.

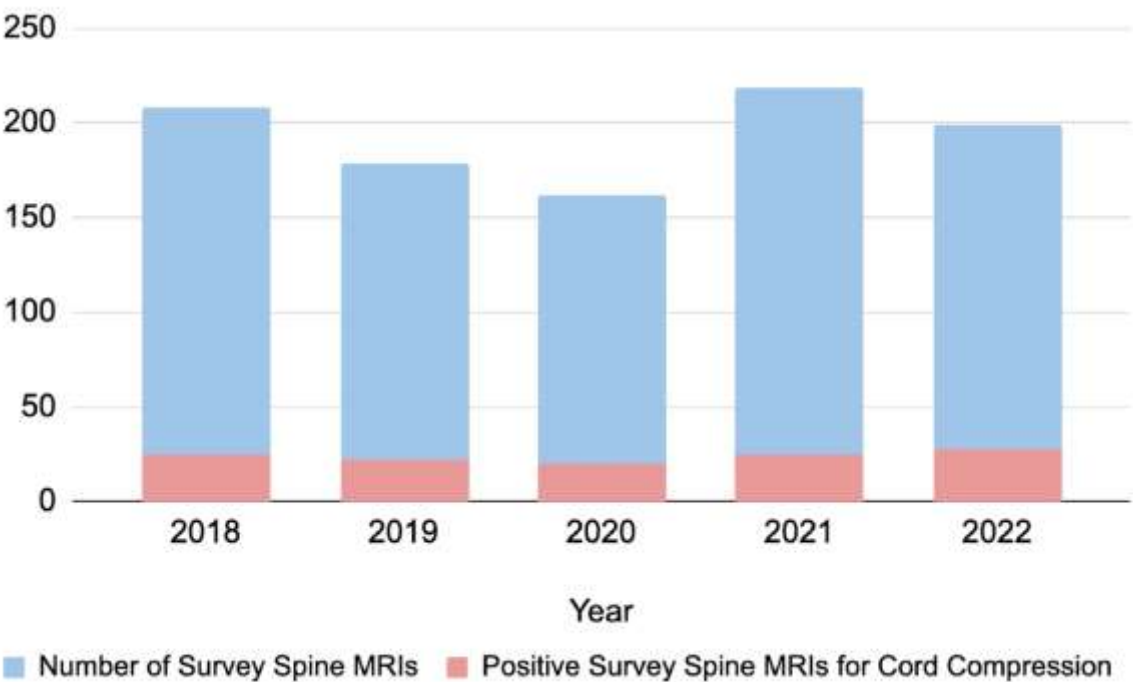


Figure 2. Relative Utilization of a Survey Spine MRI Protocol and its Positivity Rate for Cord Compression Over a 5-Year Duration.

Patient Clinical Presentation

For patients who received a spine MRI for suspected CC, 55% had back pain, 29% had lower extremity weakness, 23% presented with trauma, 20% had numbness, 14% had neck pain, 14% had urinary incontinence, 7.3% had ataxia, 6.4% had hyperreflexia, 6.0% had bowel incontinence, and 5.7% had history of malignancy. On univariate analysis, trauma, back pain, numbness, ataxia, and hyperreflexia were associated with having evidence of cord compression on MRI (Table 3).

Table 3. Univariate analysis of factors associated with positive vs negative MRI for acute cord compression.

Predictor	MRI Negative for CC (N=725)	MRI Positive for CC (N=120)	P Value
Age	57.4 ± 19.4	59.3 ± 17.0	.31
Males	381 (52.6%)	82 (68.3%)	.001
Trauma presentation	3139 (19.2%)	56 (46.7%)	<.001
Back pain	382 (52.7%)	86 (71.7%)	<.001
Lower extremity weakness	163 (22.5%)	79 (65.8%)	<.001
Malignancy history	39 (5.4%)	9 (7.5%)	.35
Urinary incontinence	77 (10.6%)	42 (35.0%)	<.001
Bowel incontinence	29 (4.0%)	22 (18.3%)	<.001
Neck pain	98 (13.5%)	22 (18.3%)	.11
Sensory paresthesia	91 (12.6%)	77 (64.2%)	<.001
Ataxia	16 (2.2%)	46 (38.3%)	<.001
Hyperreflexia	7 (1.0%)	47 (39.2%)	<.001

In the multivariate model, trauma, back pain, lower extremity weakness, urinary or bowel incontinence, numbness, ataxia, and hyperreflexia were significantly associated with acute CC (Table 4).

Table 4. Multivariate logistic regression of predictors associated with MRI findings suggestive of acute cord compression among patients undergoing spine MRI for suspected cord compression in the emergency department.

Predictor	Odds Ratio	95% Confidence Interval	P Value
Age	1.01	1.00 - 1.03	.08
Male	1.81	1.01 - 3.23	.045
Trauma presentation	4.71	2.56 - 8.68	<.001
Back pain	4.45	2.40 - 8.28	<.001
Lower extremity weakness	2.86	1.58 - 5.16	.001
Urinary incontinence	2.92	1.45 - 5.90	.003
Neck pain	1.86	.81 - 4.28	.15
Sensory paresthesia	3.30	1.74 - 6.24	<.001
Ataxia	8.49	3.18 - 22.64	<.001

Hyperreflexia	15.31	5.19 - 45.13	<.001
---------------	-------	--------------	-------

Care Management for Patients with Cord Compression

Of the 120 patients with scans positive for CC, 71 (59%) underwent emergent spine surgery and 20 (17%) underwent non-emergent surgery. Of the 29 non-operative patients, 23 were referred for medical management, three were not surgical candidates due to clinical instability, one required an emergent non-spine surgery which superseded the need for emergent spine surgery, and two declined surgery or left against medical advice (Figure 3).

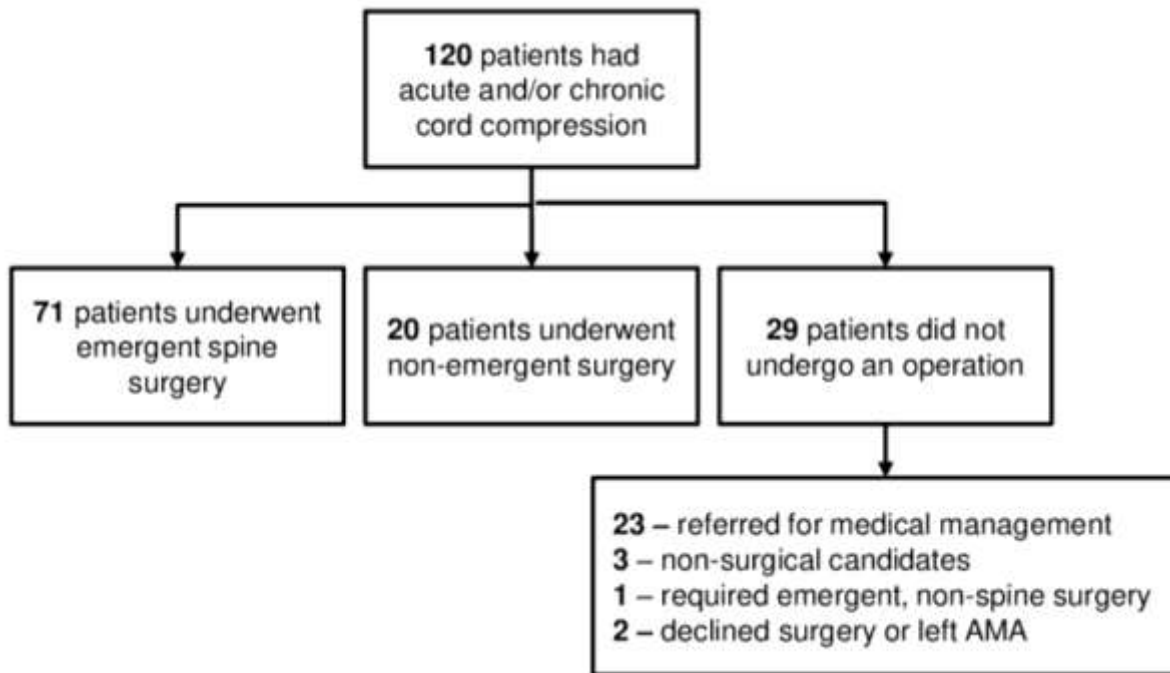


Figure 3. Care Management for Patients with Cord Compression.

Time Savings of Survey Spine MRI

The survey spine MRI averaged 5 minutes and 50 seconds compared to an average time of 27 minutes and 13 seconds for routine total spine MRI during the same period, resulting in 22 minutes and 27 seconds saved per exam (79% faster compared to routine).

DISCUSSION

Patients presenting with symptoms suspicious for cord compression (CC) are common in the emergency setting. Our level-1 trauma center developed a survey spine MRI protocol to reduce exam times while still maintaining the ability to detect the features associated with CC. We report on its utilization in a pilot study conducted over a five-year period and the characteristics of the patient population. In addition, we report on the presenting symptoms associated with CC and the outcomes of patients found to have CC to inform triage of utilizing the survey protocol and improve resource allocation. The results of this study demonstrate that a survey spine protocol results in time savings and may inform the potential adoption of rapid survey spine MRI protocols for CC screening at other institutions.

Imaging stewardship is a core tenet in radiology that guides the efficient use of imaging modalities. In the current paradigm, MRI is the gold standard for imaging of patients with suspected spinal CC as it is noninvasive and has been demonstrated to have high sensitivity and specificity in diagnosing spinal CC (9-13, 19, 22). Acute spinal CC can lead to devastating neurologic impairment. Therefore, timely and accurate diagnosis is paramount (30-33). Since multiple levels in the spinal cord can be involved in patients with metastatic CC, it is recommended that the entirety of the spine be surveyed for epidural and spinal lesions (33). However, the presenting symptoms of CC are myriad, and the incidence rate of CC is low (19). Therefore, screening for CC in the emergency setting presents multiple challenges due to the inherent pressures of maintaining an expeditious throughput of patients, resource constraints, and the high number of patients with back and neck pain, of whom the overwhelming majority are benign etiologies (25, 27, 32). In addition, MRI scanners are expensive, and examinations require significant time to complete, rendering them challenging to access in the emergency setting (25, 26). The ability to reduce acquisition time while maintaining the capacity to detect for the features of CC would afford more efficient patient turnaround and care management in the ED setting.

The use of rapid MRI protocols has been posited as a solution to reduce imaging time while screening for specific indications (25, 27-29). These protocols have shown promise in abdominal screening (34), identifying hydrocephalus in pediatric populations (35-41), and for evaluating traumatic brain injuries, seizures, tumors, vascular malformations, among others (42-47). Prior studies have reported on the development of a rapid protocol including sagittal T1 and T2 fat-saturated sequences of the lumbar spine only to detect acute fracture,

infection, and malignancy (29). Others have developed rapid protocols for total spine evaluation. One group developed a 20-minute “FAST” spine MRI protocol including sagittal T1-weighted and STIR sequences in all spinal regions (25). Another group developed a rapid total spine protocol comprised of sagittal STIR and axial T2 sequences and demonstrated it is noninferior to standard MRI for emergent findings (27).

Our center developed a rapid survey spine MRI protocol to evaluate the total spine for the specific clinical indication of CC. The survey is unique in that it is 5 minutes and 50 seconds and is comprised of sagittal T2 and STIR sequences, with the ability to add axial T2 at the discretion of the neuroradiologist. The impetus for developing the survey spine MRI protocol for cord compression was multifactorial. Foremost, we wanted to provide a high-quality and rapid MR evaluation of multiple segments of the spine to expedite diagnosis for acute cord compression. Secondly, this reduced scan time expedites imaging turnaround times with the goal of decreasing ED disposition (either admission to a hospital floor or discharge to home). Moreover, patients who would be otherwise unable to tolerate a long scan acquisition may be more likely to obtain a diagnostic scan. The main difference between the survey spine MRI and a conventional total spine MRI is the lack of sagittal T1-weighted of the spine and lack of complete axial imaging stacks. The protocol for spine survey was chosen utilizing T2/STIR sequences as this yields higher soft tissue to fluid contrast compared to T1 weighted images. This enables the ability to assess the degree of effacement of the ventral and dorsal CSF spaces surrounding the cord to evaluate for the degree of spinal canal stenosis. Similarly, in instances where there is compression of the cord with intramedullary edema, we are able to easily visualize the intramedullary edema on T2/STIR sequences. This is not as easily apparent on T1 weighted images.

Using the survey protocol, we identified findings positive for CC in 120 (14.2%) of patients who received the survey spine protocol for CC. The general incidence rates of cord compression have been previously cited as 2.5-5% in patients with cancer (48, 49) while other studies cite an incidence of 24.4% for CC in the cervical spine in their population (50). The findings in our study are higher than the general incidence rates of cord compression given that our cohort is solely derived from patients who presented with suspected CC, and thus our findings are not generalizable to the broader population. Our CC survey was specifically designed to be utilized in patients with suspected CC and thus patients who received it were more likely to have CC. Additionally, our center is a major tertiary care hospital with a large referral network, which may further contribute to our higher reported rates of CC. It is also important to note that there were 86% of patients overall who received the survey spine MRI protocol in our cohort who did not have findings positive for CC requiring emergent intervention. While the positivity rate increased by 20% across the study period demonstrating improved utilization, there is still room for improvements in decreasing the ordering frequency of imaging for patients with suspected CC.

To further reduce imaging and better guide triage of patients who may be good candidates to receive survey protocols to improve resource allocation, we evaluated the presenting symptoms of all patients and the outcomes of patients who received a positive study. Prior studies cite the most common and often first symptom of CC is back pain (11, 14, 18). Similarly, in our cohort, 55.3% of patients presented with back pain. Additional common presenting symptoms in patients with CC have been cited as neck pain, difficulty ambulating, and weakness (32). However, patient presentations are varied given the broad etiologies of CC ranging from vertebral fracture to spinal epidural abscess and hematoma to disc herniation and metastatic or primary spine tumors, among others (11, 32). In our study, we found that trauma, back pain, numbness, ataxia, and hyperreflexia were symptoms significantly associated with CC in both univariate and multivariate models, and lower extremity weakness and urinary or bowel incontinence were significantly associated with CC in the multivariate model. It is important to note that while certain presenting symptoms (e.g., back pain) were associated with studies positive for CC, one symptom in isolation is likely not a specific enough marker for CC but rather these symptoms combined may be more highly associated with cord compression. Nonetheless, evaluating the symptoms commonly associated with the clinical presentation of CC can inform which patients may be more likely to have CC and thereby require emergent imaging to rule in acute CC and pursue subsequent workup.

Urgent evaluation for acute spinal CC is necessary since, untreated, it has the potential to cause progressive and devastating neurologic impairment. Previous studies have shown that neurologic function at the time of treatment is an important predictor of final outcome, and if diagnosis is missed or delayed, patients may have further neurologic deterioration (31). The workup for acute CC often requires emergent decompressive surgery. For these reasons, we further investigated the subsequent care management of the 120 patients with CC in our cohort. We found that 71 underwent emergent spine surgery, 20 underwent non-emergent surgery, and 29 did not receive surgery. Of those that did not receive any form of intervention, medical management, lack of surgical candidacy, and decline of procedure were the most common reasons. To eliminate imaging use in patients positive for CC who never underwent a surgery, considerations regarding medical management as well as patient surgical candidacy and desire for surgery could be addressed prior to ordering imaging to ensure imaging is adding value and guidance for subsequent management.

The goal of the rapid MRI protocols is to reduce acquisition time and allow for more efficient triage (7, 8, 25, 27-29). At our institution, our survey spine MRI is 22 minutes and 27 seconds faster than routine spine MRI, operating at a 79% faster rate. Eliminating extraneous scan time further could lead to significant cost savings and more efficient patient care in the emergency setting, especially certain imaging studies such as MRI (6). Thus, the use of survey protocols for common indications such as CC in the emergency setting may lead to efficient and cost-saving patient management.

Limitations

This study has several limitations. First, this retrospective study is susceptible to patient and outcome selection bias. We relied exclusively on documentation present in each patient’s medical record, and therefore our data subject to the possibility of confounding by unmeasured variables. All patients in this study were evaluated at a single center which houses dedicated 24/7/365 subspecialized

neuroradiology coverage that includes the ability for neuroradiologists to evaluate scans as they are being performed, which could limit the generalizability of the results to other locations with a different demographics, disease patterns or subspecialty coverage. Additionally, our center is a major tertiary care hospital with a large referral network, which may contribute to our higher reported rates of CC. Future studies should evaluate the use of the survey spine MRI protocol at their sites to best understand its potential broad adoption into clinical care. It may be difficult to achieve time-savings at institutions that are unable to provide around the clock neuroradiology coverage to check and modify the scans real-time.

CONCLUSIONS

Our level-1 center developed a survey spine MRI protocol to screen for CC in the emergency setting. We found that the survey spine protocol was positive for CC in 14.2% of patients with suspected CC and was acquired at a 79% faster rate compared to routine total spine. Understanding the positivity rate of CC, the clinical symptoms that are most associated with CC, and the subsequent care management for patients presenting with suspected cord compression who received the survey spine MRI may better inform the broad adoption and subsequent utilization of survey imaging protocols in emergency settings to increase throughput, improve allocation of resources, and provide efficient care for patients with suspected CC.

REFERENCES

- Berlyand, Y., Fraga, J. A., Succi, M. D., et al. Impact of iodinated contrast allergies on emergency department operations. *The American journal of emergency medicine* 2020;61:127–130. <https://doi.org/10.1016/j.ajem.2022.08.052>
- Hadian, M., Jabbari, A., Mazaheri, E., et al. What is the impact of clinical guidelines on imaging costs?. *Journal of education and health promotion* 2021;10:10. https://doi.org/10.4103/jehp.jehp_225_20
- Lang, M., Cartmell, S., Tabari, A., et al. Evaluation of the Aggregated Time Savings in Adopting Fast Brain MRI Techniques for Outpatient Brain MRI. *Academic radiology* 2023;30(2):341–348. <https://doi.org/10.1016/j.acra.2021.07.011>
- Selvarajan, S. K., Levin, D. C., & Parker, L. The Increasing Use of Emergency Department Imaging in the United States: Is It Appropriate?. *AJR. American journal of roentgenology* 2019;213(4):W180–W184. <https://doi.org/10.2214/AJR.19.21386>
- Succi, M. D., Yun, B. J., Rao, S., et al. Turning around cancer: Oncology imaging and implications for emergency department radiology workflow. *The American journal of emergency medicine* 2020;38(2):317–320. <https://doi.org/10.1016/j.ajem.2019.158435>
- Emery, D. J., Shojania, K. G., Forster, A. J., et al. Overuse of magnetic resonance imaging. *JAMA internal medicine* 2013;173(9):823–825. <https://doi.org/10.1001/jamainternmed.2013.3804>
- Beker K, Garcés-Descovich A, Mangosing J, Cabral-Goncalves I, Hallett D, Morteale KJ. Optimizing MRI Logistics: Prospective Analysis of Performance, Efficiency, and Patient Throughput. *AJR Am J Roentgenol* 2017;209(4):836–844.2.
- O'Brien JJ, Stormann J, Roche K, et al. Optimizing MRI Logistics: Fo-cused Process Improvements Can Increase Throughput in an Academic Radiology Department. *AJR Am J Roentgenol* 2017;208(2):W38–W44.
- Black DF, Wood CP, Wells ML, Erickson BJ, Diehn FE, Kaufmann TJ et al (2015) Emergent, after hours magnetic resonance imaging of the spine. *J Neuroimaging* 25(4):590–594 2.
- Rosenkrantz AB, Hanna TN, Babb JS, Duszak R Jr (2017) Changes in emergency department imaging: perspectives from national patient surveys over two decades. *J Am Coll Radiol* 14(10):1282–1290 3.
- Ahad A, Elsayed M, Tohid H (2015) The accuracy of clinical symptoms in detecting cauda equina syndrome in patients undergoing acute MRI of the spine. *Neuroradiol J* 28(4):438–442 4.
- Rooney A, Statham PF, Stone J (2009) Cauda equina syndrome with normal MR imaging. *J Neurol* 256(5):721–725
- Laur, O., Nandu, H., Titelbaum, D. S., et al. Nontraumatic Spinal Cord Compression: MRI Primer for Emergency Department Radiologists. *Radiographics : a review publication of the Radiological Society of North America, Inc* 2019;39(6):1862–1880. <https://doi.org/10.1148/rg.2019190024>
- Ropper AE, Ropper AH (2017) Acute spinal cord compression. *N Engl J Med* 376(14):1358–1369 6.
- Davis JW, Phreaner DL, Hoyt DB, Mackersie RC (1993) The etiology of missed cervical spine injuries. *J Trauma* 34(3):342–346 7.
- Gitelman A, Hishmeh S, Morelli BN, Joseph SA Jr, Casden A, Kufik P et al (2008) Cauda equina syndrome: a comprehensive review. *Am J Orthop (Belle Mead NJ)* 37(11):556–562
- Huang, R., Ryu, R. C., Kim, T. T., et al. Is magnetic resonance imaging becoming the new computed tomography for cervical spine clearance? Trends in magnetic resonance imaging utilization at a Level I trauma center. *The journal of trauma and acute care surgery* 2020;89(2):365–370. <https://doi.org/10.1097/TA.0000000000002752>
- Lee, S. F., Wong, F. C. S., & Tung, S. Y. No Ordinary Back Pain: Malignant Spinal Cord Compression. *The American journal of medicine* 2018;131(7):772–774. <https://doi.org/10.1016/j.amjmed.2018.02.001>
- Singleton, J. M., & Hefner, M. Spinal Cord Compression. In *StatPearls*. StatPearls Publishing 2023.
- Gardner A, Gardner E, Morley T (2011) Cauda equina syndrome: a review of the current clinical and medico-legal position. *Eur Spine J* 20(5):690–697 9.
- Huang CWC, Ali A, Chang YM, Bezuidenhout AF, Hackney DB, Edlow JA et al (2020) Major radiologic and clinical outcomes of total spine MRI performed in the emergency department at a major academic medical center. *AJNR Am J Neuroradiol* 41(6):1120–1125
- Robert, S., Asch, M., & Nijmeh, L. Rate of Inappropriate Imaging Utilization by the Emergency Department in Community Hospitals. *Open Journal of Radiology* 2018;8(4):Article 4. <https://doi.org/10.4236/ojrad.2018.84031>
- Degnan AJ, Ghobadi EH, Hardy P, Krupinski E, Scali EP, Stratchko L et al (2019) Perceptual and interpretive error in diagnostic radiology-causes and potential solutions. *Acad Radiol* 26(6):833–845 11.
- Shah NA, Hoch M, Willis A, Betts B, Patel HK, Hershey BL (2010) Correlation among on-call resident study volume, discrepancy rate, and turnaround time. *Acad Radiol* 17(9):1190–1194
- Eisenmenger, L. B., Peret, A., Roberts, G. S., Spahic, A., Tang, C., Kuner, A. D., Grayev, A. M., Field, A. S., Rowley, H. A., & Kennedy, T. A. (2023). Focused Abbreviated Survey MRI Protocols for Brain and Spine Imaging. *Radiographics : a review publication of the Radiological Society of North America, Inc*, 43(6), e220147. <https://doi.org/10.1148/rg.220147>
- van Beek, E. J. R., Kuhl, C., Anzai, Y., et al. Value of MRI in medicine: More than just another test?. *Journal of magnetic resonance imaging:JMRI* 2019;49(7):e14–e25. <https://doi.org/10.1002/jmri.26211>
- Chang, Y. M., Ebrahimzadeh, S. A., Griffin, H., & Bhadelia, R. A. (2022). Shortened total spine MRI protocol in the detection of spinal cord

compression and pathology for emergent settings: a noninferiority study. *Emergency radiology*, 29(2), 329–337. <https://doi.org/10.1007/s10140-021-01956-9>

28. Kim JK, Learch TJ, Colletti PM, Lee JW, Tran SD, Terk MR (2000) Diagnosis of vertebral metastasis, epidural metastasis, and malignant spinal cord compression: are T(1)-weighted sagittal images sufficient? *Magn Reson Imaging* 18(7):819–824 13.
29. Wang B, Fintelmann FJ, Kamath RS, Kattapuram SV, Rosenthal DI (2016) Limited magnetic resonance imaging of the lumbar spine has high sensitivity for detection of acute fractures, infection, and malignancy. *Skeletal Radiol* 45(12):1687–1693
30. Metastatic Spinal Cord Compression: Diagnosis and Management of Patients at Risk of or with Metastatic Spinal Cord Compression. National Collaborating Centre for Cancer (UK) 2008. <http://www.ncbi.nlm.nih.gov/books/NBK55007/>
31. Chaichana, K. L., Woodworth, G. F., Sciubba, D. M., et al. Predictors of ambulatory function after decompressive surgery for metastatic epidural spinal cord compression. *Neurosurgery* 2008;62(3):683–692; discussion 683–692. <https://doi.org/10.1227/01.neu.0000317317.33365.15>
32. Dugas, A. F., Lucas, J. M., & Edlow, J. A. Diagnosis of Spinal Cord Compression in Nontrauma Patients in the Emergency Department. *Academic Emergency Medicine* 2011;18(7):719–725. <https://doi.org/10.1111/j.1553-2712.2011.01105.x>
33. Al-Qurainy, R., & Collis, E. Metastatic spinal cord compression: diagnosis and management. *BMJ (Clinical research ed.)* 2016;353:i2539. <https://doi.org/10.1136/bmj.i2539>
34. Canellas, R., Rosenkrantz, A. B., Taouli, B., Sala, E., Saini, S., Pedrosa, I., Wang, Z. J., & Sahani, D. V. (2019). Abbreviated MRI Protocols for the Abdomen. *Radiographics* : a review publication of the Radiological Society of North America, Inc, 39(3), 744–758. <https://doi.org/10.1148/rg.2019180123>
35. Ramgopal S, Karim SA, Subramanian S, Furtado AD, Marin JR. Rapid brain MRI protocols reduce head computerized tomography use in the pediatric emergency department. *BMC Pediatr* 2020;20(1):14.
36. Iskandar BJ, Sansone JM, Medow J, Rowley HA. The use of quick-brain magnetic resonance imaging in the evaluation of shunt-treated hydrocephalus. *J Neurosurg* 2004;101(2 suppl):147–151.
37. Kim I, Torrey SB, Milla SS, Torch MC, Tunik MG, Foltin JC. Benefits of brain magnetic resonance imaging over computed tomography in children requiring emergency evaluation of ventriculoperitoneal shunt malfunction: reducing lifetime attributable risk of cancer. *Pediatr Emerg Care* 2015;31(4):239–242.
38. Patel DM, Tubbs RS, Pate G, Johnston JM Jr, Blount JP. Fast-sequence MRI studies for surveillance imaging in pediatric hydrocephalus. *J Neurosurg Pediatr* 2014;13(4):440–447.
39. Gewirtz JI, Skidmore A, Smyth MD, et al. Use of fast-sequence spine MRI in pediatric patients. *J Neurosurg Pediatr* 2020;26(6):676–681
40. Ha JY, Baek HJ, Ryu KH, et al. One-Minute Ultrafast Brain MRI With Full Basic Sequences: Can It Be a Promising Way Forward for Pediatric Neuro-imaging? *AJR Am J Roentgenol* 2020;215(1):198–205.
41. Khaira G, Kurz JE. Rapid Brain MRI Use in a Pediatric Emergency Department. *Pediatr Neurol Briefs* 2020;34(0):21
42. Flom L, Fromkin J, Panigrahy A, Tyler-Kabara E, Berger RP. Development of a screening MRI for infants at risk for abusive head trauma. *Pediatr Radiol* 2016;46(4):519–526.
43. Kralik SF, Yasrebi M, Supakul N, et al. Diagnostic Performance of Ultrafast Brain MRI for Evaluation of Abusive Head Trauma. *AJNR Am J Neuroradiol* 2017;38(4):807–813.
44. Ryan ME, Jaju A, Ciolino JD, Alden T. Rapid MRI evaluation of acute intracranial hemorrhage in pediatric head trauma. *Neuroradiology* 2016;58(8):793–799.
45. Grewal SS, Middlebrooks EH, Kaufmann TJ, et al. Fast gray matter acquisition T1 inversion recovery MRI to delineate the mammillothalamic tract for preoperative direct targeting of the anterior nucleus of the thalamus for deep brain stimulation in epilepsy. *Neurosurg Focus* 2018;45(2):E6.
46. Wieshmann UC, Free SL, Everitt AD, et al. Magnetic resonance imaging in epilepsy with a fast FLAIR sequence. *J Neurol Neurosurg Psychiatry* 1996;61(4):357–361.
47. Loução R, Oros-Peusquens AM, Langen KJ, Ferreira HA, Shah NJ. A Fast Protocol for Multiparametric Characterisation of Diffusion in the Brain and Brain Tumours. *Front Oncol* 2021;11:554205
48. Robson P. Metastatic spinal cord compression: a rare but important complication of cancer. *Clinical medicine (London, England)* 2014;14(5):542–545. <https://doi.org/10.7861/clinmedicine.14-5-542>
49. Lawton, A. J., Lee, K. A., Cheville, A. L., et al. Assessment and Management of Patients With Metastatic Spinal Cord Compression: A Multidisciplinary Review. *Journal of clinical oncology:official journal of the American Society of Clinical Oncology* 2019;37(1):61–71. <https://doi.org/10.1200/JCO.2018.78.1211>
50. Nagata, K., Yoshimura, N., Muraki, S., et al. (2012). Prevalence of cervical cord compression and its association with physical performance in a population-based cohort in Japan: the Wakayama Spine Study. *Spine*, 37(22), 1892–1898. <https://doi.org/10.1097/BRS.0b013e31825a2619>

SUPPLEMENTAL FILES

None.