



**Get Clarity On Generics**

Cost-Effective CT & MRI Contrast Agents



FRESENIUS  
KABI

WATCH VIDEO

**AJNR**

**Percutaneous balloon myelotomy for treatment of hydromyelia: technical note.**

J R McConnell, J R Mawk and J D Kendall

*AJNR Am J Neuroradiol* 1988, 9 (5) 875-877

<http://www.ajnr.org/content/9/5/875.citation>

This information is current as  
of August 19, 2025.

# Percutaneous Balloon Myelotomy for Treatment of Hydromyelia: Technical Note

James R. McConnell,<sup>1</sup> John R. Mawk,<sup>2</sup> and John D. Kendall<sup>3</sup>

Hydromyelia is a disorder in which the central canal of the spinal cord is distended with spinal fluid. The hydromyelia may be segmental, polysegmental, or holocord [1]. Many surgical techniques have been employed for the decompression of symptomatic hydromyelia, including hydromyelo-subarachnoid or hydromyelo-peritoneal shunts, aspiration of the syrinx cavity, terminal ventriculostomy, and obex plugging [2]. Percutaneous myelotomy with a small-vessel balloon angioplasty catheter offers an alternative treatment.

## Case Report

An 8-year-old myelodysplastic boy with Chiari II malformation had previously undergone a posterior fossa decompression and plugging of the obex of the fourth ventricle for known hydromyelia. After these surgical procedures, the patient's posterior fossa symptomatology cleared, but clinical follow-up within 2 months showed the patient had further loss of leg function and decreased hand function. An MR image of the spine at that time showed the hydromyelia had enlarged and extended to the placode region. Lumbar exploration was done and the cord was untethered. In addition, a dorsal midline myelotomy through the placode was done and a Silastic stent was placed between the subarachnoid space and the hydromyelia. The patient's leg function improved to a plateau level after surgery. However, within several weeks his handwriting ability deteriorated showing a fine tremor and early fatigue and he developed hyperreflexia in the arms. A repeat MR image demonstrated progressive enlargement of the hydromyelic cavity throughout the entire cord, extending into the placode segment (Fig. 1). At this point, the Silastic stent and obex plugging were deemed nonfunctional. Because the obex plugging and stent procedure had failed to retard the progression of the hydromyelia, a decision was made to attempt a percutaneous balloon myelotomy. The purpose of the balloon myelotomy was to make a fistula between the hydromyelia and the subarachnoid space. Spinal somatosensory evoked potentials (SSEP) showed moderate improvement, decreasing from 42.88 msec latency before percutaneous myelotomy to 38.71 msec latency immediately after the procedure. Normal conduction time is 37 msec. In addition, there was a four-fold increase in SSEP amplitude after myelotomy; however, we believe that SSEP amplitude is less reliably correlated with neurologic function than is latency. After the procedure, neurologic examination showed an increase in dorsiflexion of the right ankle and improved

gait and hand function. Preoperative hyperreflexia in the upper arms became normal. The patient demonstrated improved handwriting ability without tremor, and dynametric testing showed an objective increase in grip strength in the right hand 1 week after the balloon myelotomy. Physical examination, MR imaging, and SSEP were repeated 4 months after the balloon myelotomy. The physical examination showed stable neurologic function. The gait and hand function had remained at the improved levels. The MR image showed moderate collapse of the hydromyelia compared with its dimensions before the balloon myelotomy (Fig. 2). The follow-up SSEP, which was performed in the same manner as previously, recorded a conduction time of 40.0 msec. Considering the clinically improved neurologic state, the collapse of the hydromyelia as shown on MR and the relatively improved SSEP latency suggested that a functioning drainage of the hydromyelia had been established.

## Technique

The procedure was performed on an outpatient basis. The patient was sedated with meperidine and diazepam, but remained awake during the entire procedure. Somatosensory evoked potentials were elicited continuously by stimulation of both posterior tibial nerves with 15.0 mA pulses recorded from the C5 spinal level. SSEP readings were obtained before, during, and after balloon myelotomy. Each SSEP sample was the average of 500 pulses. SSEP recordings from the C5 spinal level have been used in our institution so as to avoid the effects of sedation and anesthesia on the cerebral cortex.

Lumbar puncture was performed by using sterile technique, and the hydromyelic cavity was penetrated under fluoroscopic observation. The cavity was opacified with nonionic contrast medium (Fig. 3). Attempts to introduce a balloon catheter through an angiographic introducer sheath were thwarted by dense scar. A 16-gauge Thouy needle allowed passage of a 4F Omega C balloon dilatation catheter\* through the dorsal and ventral walls of the cord. Myelography was then performed to confirm penetration of the ventral wall of the cord. The myelotomy track was dilated three times by fully inflating the 2 × 15-mm balloon with nonionic contrast (Fig. 4). Contrast agent was injected during withdrawal of the balloon catheter, and, by fluoroscopy, could be seen leaking through the ventral myelotomy into the subarachnoid space, confirming communication (Fig. 5). The catheter

\* Cook Co., Bloomington, IN.

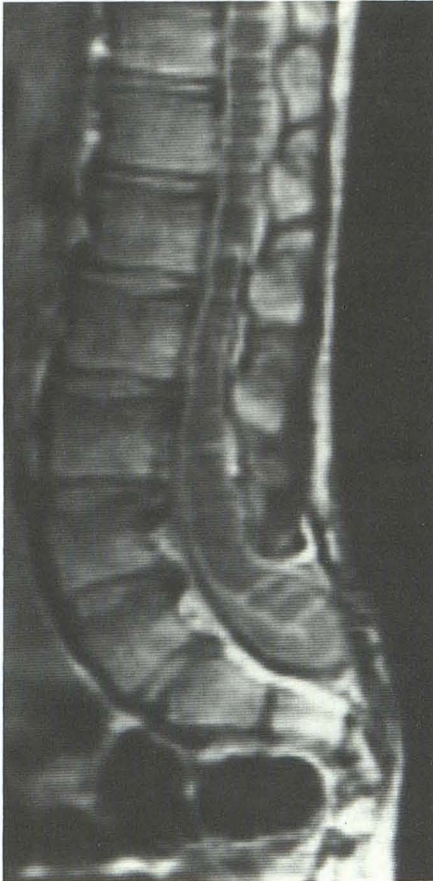Received November 2, 1987; accepted after revision January 25, 1988.

<sup>1</sup> Department of Radiology, University of Nebraska Medical Center, 42nd and Dewey Ave., Omaha, NE 68107. Address reprint requests to J. R. McConnell.

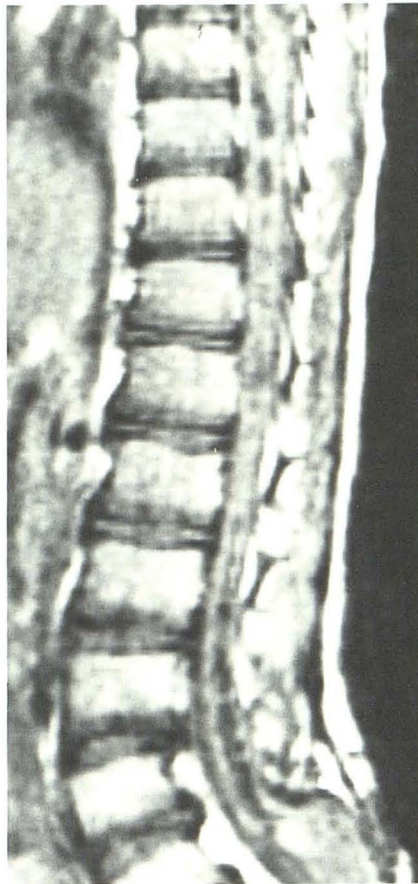
<sup>2</sup> Department of Surgery (Neurosurgery), University of Nebraska Medical Center, Omaha, NE 68107.

<sup>3</sup> Department of Pediatrics, University of Nebraska Medical Center, Omaha, NE 68107.





1



2

Fig. 1.—Sagittal MR image (2000/20) shows extensive hydromyelia extending into placode. Silastic stent is not visible.

Fig. 2.—Sagittal MR image (600/30) obtained 4 months after Fig. 1 demonstrates partial collapse of hydromyelia.

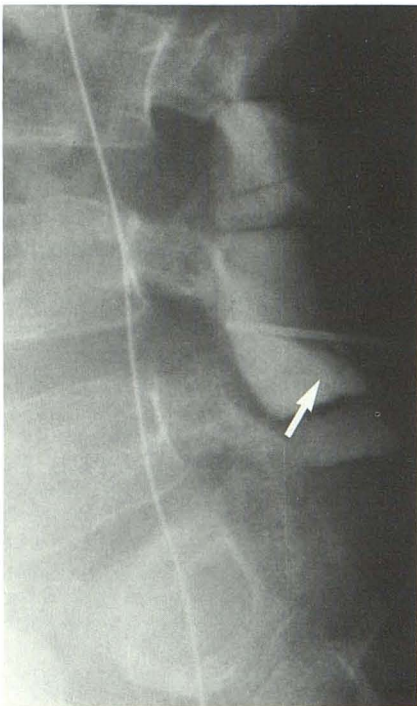


Fig. 3.—Lateral radiograph shows puncture of distended hydromyelic cavity within placode. Silastic stent (arrow) is faintly visible.

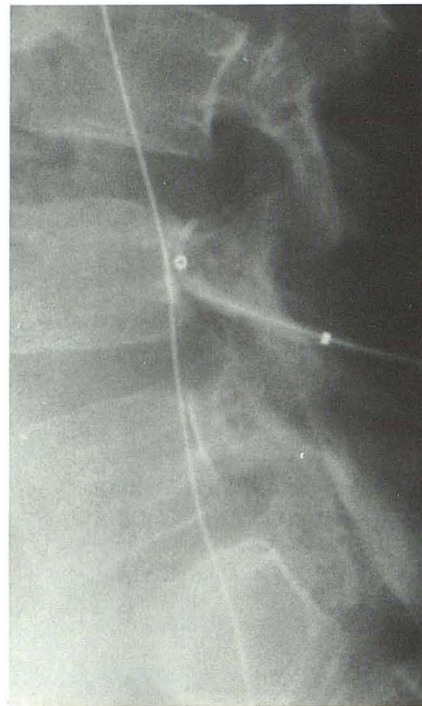


Fig. 4.—Lateral radiograph shows penetration of ventral cord with distended balloon catheter.

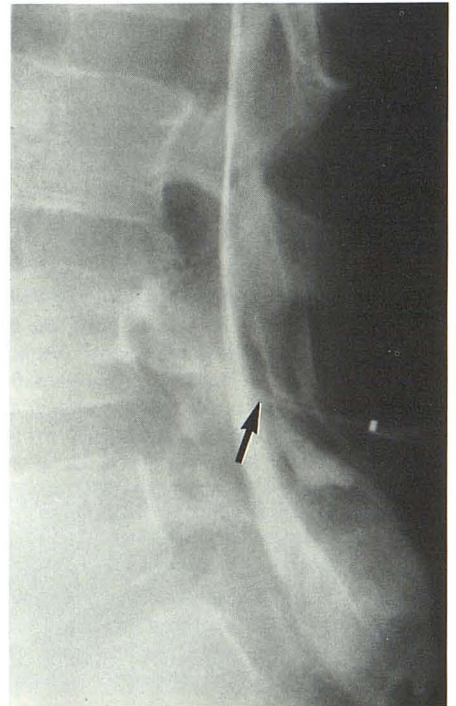


Fig. 5.—Lateral radiograph shows collapse of hydromyelic cavity. The myelotomy track (arrow) shows communication of hydromyelia and subarachnoid space.

and needle were withdrawn and a bandage was applied to the puncture site. After observation and reexamination, the patient was discharged home to the care of his parents.

### Discussion

Hydromyelia is a clinically unpredictable disease often accompanied by gradual, insidious neurologic losses. Surgical treatments of hydromyelia have been directed at draining the hydromyelic cavity, thus inducing collapse of the distended spinal cord, decreasing parenchymal pressure, and improving blood supply to the cord. Percutaneous cord puncture is hazardous and the potential for cord damage and neurologic loss should be carefully considered before undertaking balloon myelotomy. However, cord puncture has been shown to be a safe procedure when proper guidelines are followed [3]. SSEP is recommended during intrathecal positioning of the balloon dilatation catheter and balloon myelotomy. With careful planning and attention to detail percutaneous balloon myelotomy can be accomplished successfully, as our case

demonstrates. Moreover, the procedure may have special utility in the treatment of hydromyelia in myelodysplastic patients with paraplegia. In such cases, the balloon myelotomy could be performed in a nonfunctional region of the cord, obviating potential neurologic damage.

Percutaneous balloon myelotomy offers a new approach to the treatment of hydromyelia. The procedure is attractive because it can be done on an outpatient basis at a lower cost and without general anesthesia. It is a relatively simple procedure to perform and has apparent efficacy. Further study will be necessary to assess the long-term effectiveness of this treatment and the risk-benefit relation.

### REFERENCES

1. Sherman JL, Barkovich AJ, Citrin CM. The MR appearance of syringomyelia: new observations. *AJR* **1987**;148:381-391
2. Schlesinger EB, Autunes JL, Michelsen WJ, Louis KM. Hydromyelia: clinical presentation and comparison of modalities of treatment. *Neurosurgery* **1981**;9:(4)356-365
3. Quencer RM. Needle aspiration of intramedullary and intradural extramedullary masses of the spinal cord. *Radiology* **1980**;134:115-126