



Get Clarity On Generics

Cost-Effective CT & MRI Contrast Agents

 FRESENIUS
KABI

[WATCH VIDEO](#)

AJNR

Angiographic demonstration of the meningeal branch of the posterior cerebral artery.

W M Bojanowski, D Rigamonti, R F Spetzler and R Flom

AJNR Am J Neuroradiol 1988, 9 (4) 808

<http://www.ajnr.org/content/9/4/808.citation>

This information is current as
of August 12, 2025.

Angiographic Demonstration of the Meningeal Branch of the Posterior Cerebral Artery

The tentorial arteries arise from three main sources [1]. The first is the cavernous segment of the carotid artery. The meningohypophyseal trunk gives rise to the basal tentorial artery (artery of Bermasconi-Cassanari), and the inferior cavernous sinus artery gives rise to the marginal tentorial artery. The second source is the meningeal branch of the superior cerebellar artery. The third is the meningeal branch of the posterior cerebral artery (PCA, artery of Davidoff and Schechter), which has rarely been identified on angiographic studies. This report represents the first angiographic demonstration of the origin and the proximal part of the meningeal branch of the PCA.

Case Report

A 26-year-old, right-handed man was admitted for evaluation of a 13-year history of a seizure disorder caused by an arteriovenous malformation located in the left parietal lobe. Seizures could occur up to five times a day and were characterized by an inability to communicate and by a state of confusion that lasted for a few seconds. The patient also had grand mal seizures one or two times a year. He described occasional trouble with speech, and he sometimes experienced difficulty with reading and understanding. These subtle problems appeared to be progressing.

On examination, the patient was alert and had no speech disorders. Examination of the cranial nerves showed a right homonymous hemianopsia. The rest of the neurologic examination, including parietal function, was unremarkable.

Cerebral angiography confirmed the vascular pattern of a partially dural arteriovenous malformation with deep and superficial venous drainage. The origin and the course of the meningeal branch of the PCA were seen clearly (Fig. 1). Because of the size and location of the malformation, the lack of evidence of its rupture, and the good control of seizures by means of medication, a surgical procedure was not recommended.

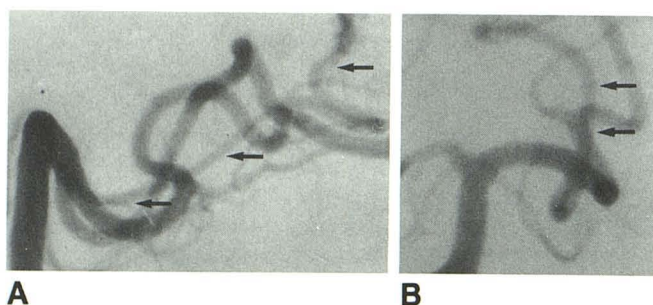


Fig. 1.—A and B, Lateral (A) and anteroposterior (B) left vertebral angiograms show origin and course of meningeal branch (arrows) of posterior cerebral artery running toward falcotentorial junction.

Discussion

The meningeal branch of the PCA is one of the main vascular supplies of the tentorium [1]. Wollschlaeger and Wollschlaeger, who first described this artery in 1965, named it the artery of Davidoff and Schechter in honor of their mentors [2]. In nine of 10 brain specimens with intact dura, the artery was identified as originating from the peduncular or ambient portion of the left PCA [2]. This long artery courses around the brainstem below the tentorium where it enters near the apex, supplying the adjacent falx cerebri. It also may give branches to the superior vermis and the inferior colliculi [1].

In 1974, Weinstein et al. [2] reported the first angiographic demonstrations of the meningeal branch of the PCA and presented three cases. A fourth angiographic identification was reported in 1977, and a posterior division of the meningeal branch of the PCA was described. However, in none of these cases was the origin and the proximal part of the artery visualized with certainty because the adjacent PCA was superimposed.

After it originates from the P2 part (also termed the ambient segment) of the PCA, the meningeal branch of the PCA courses posteriorly around the midbrain, following an inferiorly convex course (Fig. 1). The cisternal part is relatively parallel to the PCA and remains medial to it. The artery continues posteriorly toward the junction of the falx cerebri and the tentorium. When it arrives at the midline, it curves sharply to enter the tentorium.

Including our case, the meningeal branch of the PCA has been found on the left side in four of the five cases reported. These cases include three arteriovenous malformations, all with at least partial dural involvement, and two tumors, one of which was verified as a meningioma.

With magnification radiologic techniques, the meningeal branch of the PCA is not visualized on angiograms of normal subjects. It has been identified only on angiograms of patients who had abnormalities in which a well-vascularized lesion has caused the branch to enlarge. Its visualization should cause suspicion of a possible intracranial lesion involving the meninges.

W. Michel Bojanowski
Daniele Rigamonti
Robert F. Spetzler
Richard Flom
Barrow Neurological Institute
Phoenix, AZ 85013

REFERENCES

1. Ono M, Ono M, Rhoton AL Jr, Barry M. Microsurgical anatomy of the region of the tentorial incisura. *J Neurosurg* 1984;60:365-399
2. Weinstein M, Stein R, Pollock J, Stucker TB, Newton TH. Meningeal branch of the posterior cerebral artery. *Neuroradiology* 1974;7:129-131
3. Weinstein M, Duchesneau P, Dohn DF. Angiographic identification of the meningeal branch of the posterior cerebral artery. *AJR* 1977;128:326-327