



**Providing Choice & Value**

Generic CT and MRI Contrast Agents



**FRESENIUS  
KABI**

**CONTACT REP**

**AJNR**

**Orbital varicose capillary angioma: radiologic  
description of a distinct vascular entity.**

J R Jenkins

*AJNR Am J Neuroradiol* 1988, 9 (3) 589-591

<http://www.ajnr.org/content/9/3/589.citation>

This information is current as  
of July 28, 2025.

# Orbital Varicose Capillary Angioma: Radiologic Description of a Distinct Vascular Entity

John R. Jenkins<sup>1,2</sup>

Vascular hamartomas of the orbit have been extensively studied with a variety of techniques. Modern imaging equipment allows these studies to be carried out with greater facility and with a higher yield of detailed information than has been possible in the past. This report relates the radiologic definition of a newly observed vascular lesion of the orbit and places it in the framework of past reports of similar lesions.

## Case Report

A 26-year-old woman presented with complaints of positional exophthalmos accompanied by transient lid droop involving the left eye. For 3 years she had noticed this symptom complex brought on by bending over at the waist.

The initial axial CT scan demonstrated an irregular orbital apex mass that enhanced homogeneously after IV contrast administration (Fig. 1A). Repeat axial sections during jugular vein compression revealed remarkable enlargement of the mass and accompanying exophthalmos (Fig. 1B). This change in size was also noted between prone head-extended coronal sections and supine hanging-head coronal studies (Figs. 1C and 1D). An additional finding was a calcified phlebolith at the orbital apex (Fig. 1E).

As a parallel investigation, a histologically diagnosed cavernous hemangioma was evaluated before and after jugular compression and showed no evidence of enlargement, allowing for positional differences and photographic technique (Fig. 2).

In an effort to further characterize the lesion, subselective arterial digital subtraction angiography (DSA) was performed. This study demonstrated an early capillary blush at two separate points within the orbit, which was fed from the external carotid injection (Fig. 1F). Subsequently, during the late venous phase of selective left internal carotid arterial DSA, the variceal component opacified during quiet breathing and was seen to enlarge as expected with a second injection given during Valsalva maneuver (Figs. 1G and 1H).

Because of the benign clinical course and transient nature of the orbital manifestations, surgery did not seem to be indicated. Follow-up in clinic has been uneventful without progression of the symptomatology.

## Discussion

Orbital arteriovenous malformations, hemangiomas, and varices all have distinct radiologic appearances. The present

case shares characteristics of both capillary angioma and orbital varix: angiographic capillary blush followed by varicose venous drainage, which changes dynamically with various manipulations [1–7]. It may well be that the orbital varices reported in the past were of this type; however, arteriographic studies of sufficient detail did not accompany these reports [2–5, 7–9]. In addition, the capillary component is so small that it may have been overlooked in past surgical specimens. Nevertheless, rare reports do describe angiomatous lesions in association with radiologic and clinical venous variceal manifestations of orbital vascular hamartomas [10, 11].

Another possibility is that this case, and potentially other orbital varices, represents a true venous angioma of the orbit [12–21]. Certainly, venous angiomas with variceal components are documented within the CNS as well as peripherally and have similar radiographic presentations [22–25]. In fact, several recent publications relate definite angiomatous elements within certain venous angiomata of the cerebrum [15, 16, 18, 20, 26]. Only a single report has alluded to a “capillary network” in association with orbital varices, this being shown via orbital venography [21, 27]. Nevertheless, this would seem to further support a hypothesis of a mixed type of angioma. Finally, one report defines a true “proliferation of capillaries” associated with some venous angiomas, still further advancing the theory of a true angiomatous component in at least some of these lesions [12]. However, no histology is available in the current subject, and therefore it must remain a radiologic description.

In summary, an expanded view of vascular hamartomas with venous variceal components is indicated. This spectrum includes true isolated venous varices, classical venous angiomas with associated varicosities, and compound angiomatous/varicose combinations as demonstrated in the present case [12, 13, 15, 16, 18–21, 26–28]. A label of varicose capillary angioma seems to be warranted in cases manifesting the following combination of radiographic findings: (1) a serpiginous, irregular orbital lesion on CT that changes rapidly in size over a period of seconds with alterations in jugular venous pressure incurred by positional changes, jugular vein compression, or Valsalva maneuver; (2) an angiomatous cap-

Received July 18, 1986; accepted after revision October 23, 1986.

<sup>1</sup> Department of Radiology, King Faisal Specialist Hospital and Research Centre, P.O. Box 3354, Riyadh 11211 Saudi Arabia.

<sup>2</sup> Present address: Huntington Medical Research Institutes, NMR Imaging Laboratory, 10 Pico St., Pasadena, CA 91105-3201. Address reprint requests to J. R. Jenkins.



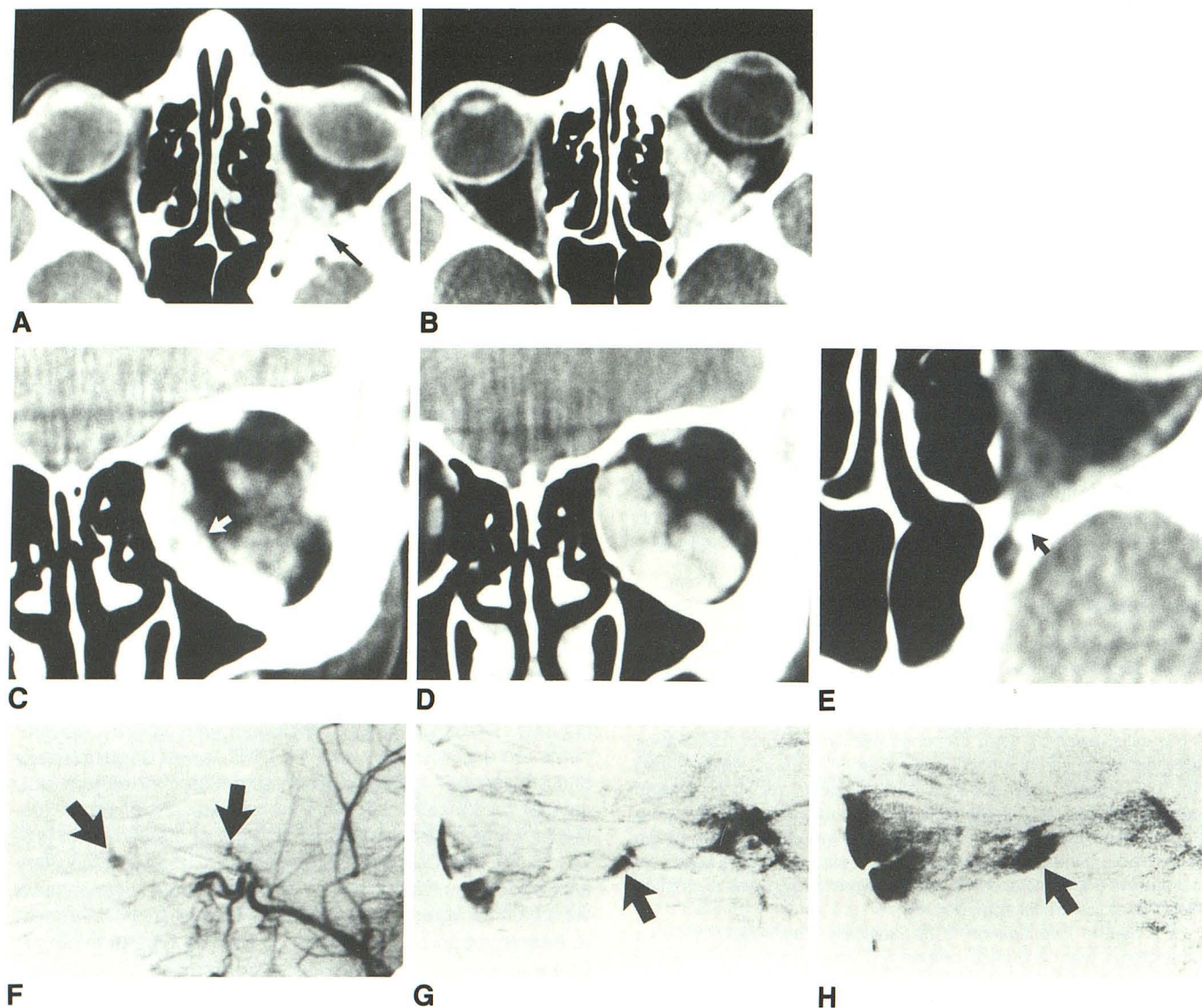


Fig. 1.—A, IV contrast axial CT scan during quiet breathing illustrates serpiginous enhancement within irregular left orbital apex mass (arrow).  
 B, Axial CT scan during jugular vein compression demonstrates that varicose portion of mass has enlarged remarkably and that exophthalmos has occurred acutely.  
 C, Prone head-extended coronal section shows crescentic shape of variceal component (arrow).  
 D, Supine hanging-head coronal slice at approximately same level as Fig. 1C demonstrates marked enlargement of varicosity due to increased venous hydrostatic pressure in this position of head.  
 E, Magnified view shows calcified phlebolith at orbital apex (arrow).  
 F, Orbital projection during selective left external carotid arterial DSA illustrates two areas of angiomatous capillary blush (arrows) fed from multiple orbital penetrating branches originating from internal maxillary artery.  
 G, During quiet breathing, lateral view of internal carotid arterial DSA centered over orbit reveals collapsed variceal component in late venous phase (arrow).  
 H, During Valsalva maneuver, late venous phase of a repeat internal carotid arterial DSA in lateral projection demonstrates moderate enlargement of varix (arrow) as compared with Fig. 1G along with diffuse venous engorgement of entire orbit, leading to a "fibrillary" appearance. Large density to reader's left represents upper and lower eyelid motion and therefore is a subtraction "artifact," which is also rendered more prominent by relative orbital venous stasis.

illary blush at arterial DSA fed from external and/or internal carotid sources; and (3) an acute, transient enlargement of the venous variceal component during selective internal carotid angiography in late venous phase with concomitant elevations in jugular venous pressure. Careful attention to surgical and histologic sectioning of lesions in future cases may clinically prove the true capillary/venous nature of these

complex angiodysplasias as observed angiographically [13, 17].

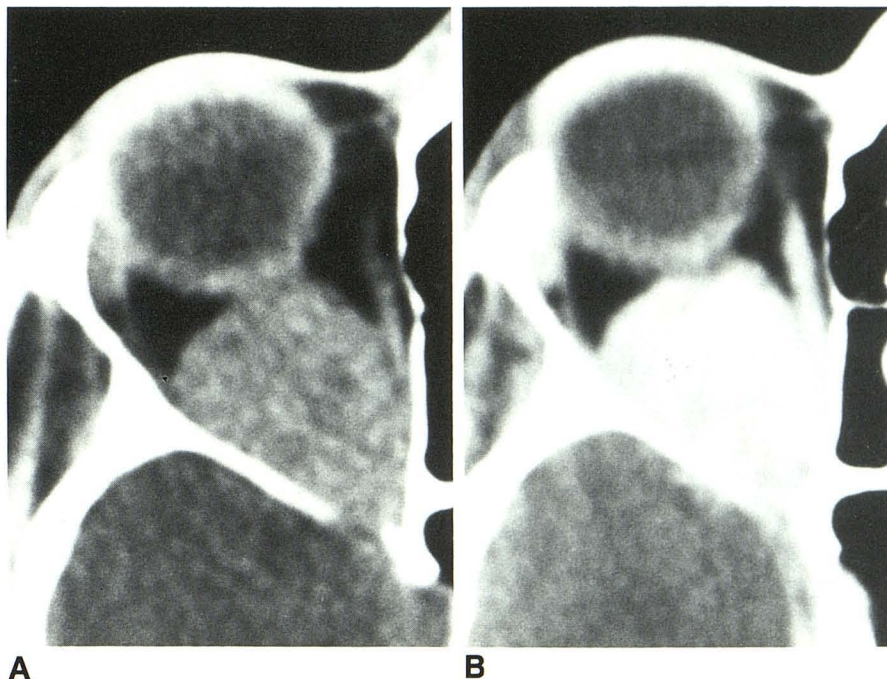
#### ACKNOWLEDGMENTS

I thank Mrs. A. Radford and Miss L. N. M. Van Laere for manuscript preparation, Mrs. C. Jenkins for manuscript research, and the Radiology Department for technical assistance with the illustrations.



Fig. 2.—A, Precontrast axial CT scan of subsequently surgically proved right orbital cavernous hemangioma during quiet respiration.

B, Axial CT scan at approximately same level during bilateral jugular vein compression after IV contrast administration demonstrates no significant change in size of lesion, allowing for minor positioning and magnification differences.



## REFERENCES

- Dilenge D. Arteriography in angiomas of the orbit. *Radiology* 1974;113:355-361
- Flanagan JC. Vascular problems of the orbit. *Ophthalmology* 1979;86:896-913
- Krayenbuhl H. The value of orbital angiography for diagnosis of unilateral exophthalmos. *J Neurosurg* 1962;19:289-301
- Lloyd GAS, Wright JE, Morgan G. Venous malformations in the orbit. *Br J Ophthalmol* 1971;55:505-516
- Shields JA, Dolinskas C, Augsburger JJ, Shah HG, Shapiro ML. Demonstration of orbital varix with computed tomography and Valsalva maneuver. *Am J Ophthalmol* 1984;97:108-111
- Winter J, Centeno RS, Bentson JR. Maneuver to aid diagnosis of orbital varix by computed tomography. *AJNR* 1982;3:39-40
- Wright JE. Orbital vascular anomalies. *Trans Am Ac Ophth Otol* 1974;78:606-616
- Handa H, Mori K. Large varix of the superior ophthalmic veins, demonstration by angular phlebography and removal by electrically induced thrombosis: case report. *J Neurosurg* 1968;29:202-205
- Peyster RG, Savino PJ, Hoover ED, Schatz NJ. Differential diagnosis of the enlarged superior ophthalmic vein. *J Comput Assist Tomogr* 1984;8:103-107
- Du Boulay GH. Orbital phlebography in the diagnosis of intra-orbital hemangiomas. *Trans Ophthalmol Soc UK* 1961;81:245-259
- Zeidler I, Zetterstrom B. Analysis of cases of venous cavernous angioma of the orbit. *Acta Ophthalmol (Copenh)* 1959;37:350-354
- Cabanes J, Blasco R, Garcia M, Tamarit L. Cerebral venous angiomas. *Surg Neurol* 1979;11:385-389
- Fierstien SB, Pribram HW, Hieshima G. Angiography and computed tomography in the evaluation of cerebral venous malformations. *Neuroradiology* 1979;17:137-148
- Hanafee WN. Orbital venography. *Radiol Clin North Am* 1972;10:63-81
- Hirata Y, Matsukado Y, Nagahiro S, Kuratsu J. Intracerebral venous angioma with arterial blood supply: a mixed angioma. *Surg Neurol* 1986;25:227-232
- Kramer RA, Wing SD. Computed tomography of angiographically occult cerebral vascular malformations. *Radiology* 1977;123:649-652
- Moritake K, Handa H, Mori K, Ishikawa M, Morimoto M, Takebe Y. Venous angiomas of the brain. *Surg Neurol* 1980;14:95-105
- Preissig RS, Preissig SH, Goree JA. Angiographic demonstration of a cerebral venous angioma. *J Neurosurg* 1976;44:628-631
- Sarwar M, McCormick WF. Intracerebral venous angioma. *Arch Neurol* 1978;35:323-325
- Wendling LR, Moore JS Jr, Kieffer SA, Goldberg HI, Latchaw RE. Intracerebral venous angioma. *Radiology* 1976;119:141-147
- Valavanis A, Wellauer J, Yasargil MG. The radiological diagnosis of cerebral venous angioma: cerebral angiography and computed tomography. *Neuroradiology* 1983;24:193-199
- Bliznak J, Staple TW. Radiology of angiodysplasias of the limb. *Radiology* 1974;110:35-44
- Handa J, Suda K, Sato M. Cerebral venous angioma associated with varix. *Surg Neurol* 1984;21:436-440
- Meyer JD, Baghai P, Latchaw RE. Cerebral varix and probable venous angioma: an unusual isolated anomaly. *AJNR* 1983;4:85-87
- Thomas ML, Andress MR. Angiography in venous dysplasias of the limb. *AJR* 1971;113:722-731
- Wolf PA, Rosman NP, New PF. Multiple small cryptic venous angiomas of the brain mimicking cerebral metastases. *Neuroradiology* 1967;17:491-501
- Doyon DL, Aron-Rosa DS, Ramee A. Orbital veins and cavernous sinus. In: Newton TH, Potts DG, eds. *Radiology of the skull and brain*. St. Louis: Mosby, 1974:2220-2254
- Newton TH, Troost BT. Arteriovenous malformations and fistulae. In: Newton TH, Potts DG, eds. *Radiology of the skull and brain*. St. Louis: Mosby, 1974:2490-2565