



Get Clarity On Generics

Cost-Effective CT & MRI Contrast Agents

**FRESENIUS
KABI**

[WATCH VIDEO](#)

AJNR

Longitudinal CT study of parenchymal brain changes in glioma survivors.

L A Stylopoulos, A E George, M J de Leon, J D Miller, S H Foo, E Hiesiger and A Wise

AJNR Am J Neuroradiol 1988, 9 (3) 517-522

<http://www.ajnr.org/content/9/3/517>

This information is current as
of August 24, 2025.

Longitudinal CT Study of Parenchymal Brain Changes in Glioma Survivors

Leonidas A. Stylopoulos¹
 Ajax E. George¹
 Mony J. de Leon²
 Jeffrey D. Miller^{1,2}
 Sun-Hoo Foo³
 Emile Hiesiger³
 Arlene Wise⁴

We reviewed the serial CT studies obtained between 1974 and 1986 of 31 patients with malignant glioma who survived for 2 to 11 years after surgical removal of their tumors. In all cases surgery was followed by radiation therapy to the head (6000 rad) and chemotherapy. Patients were divided into two age groups: those under age 40 ($n = 13$) and those over age 40 ($n = 18$). By 2 years all patients in the older group developed evidence of leukoencephalopathy characterized by periventricular zones of decreased attenuation. Only 58% of the younger group showed evidence of white matter changes at this point. All patients from both age groups who survived for 4 years developed leukoencephalopathy. The severity of leukoencephalopathy from 6 months after surgery and beyond was always greater in the older group. All patients developed cerebral atrophy as evidenced by sulcal dilatation and ventricular enlargement. Atrophy was progressive beginning with the first postirradiation scan, and was always more severe in the older patients.

A significant difference was found in the clinical status of the two age groups as determined by the mental status score and the Karnofsky scale. Despite progressive brain changes, survivors under age 40 maintained a nearly normal mental status and Karnofsky scores until their death, whereas survivors over age 40 showed progressive clinical decline.

Patients with malignant brain glioma are treated with surgery, postoperative radiation, and chemotherapy [1]. Patients who survive, even in the absence of tumor recurrence, develop chronic brain changes. These include cortical and central atrophy as evidenced by widening of the sulci, the fissures, and the ventricular system [2, 3]. In addition to these changes, we have found progressive leukoencephalopathy as evidenced by diffuse periventricular low-attenuation lesions in the absence of frank radiation necrosis. The purpose of this study was to evaluate with CT the progression of the cerebral changes in glioma survivors and to relate these findings to the patients' clinical status. To our knowledge, there are no longitudinal CT studies in the literature that address these issues in long-term glioma survivors.

Materials and Methods

We reviewed the serial CT studies of 31 patients, 14 males and 17 females ages 16–68 years old, with malignant glioma who survived from 2 to 11 years after surgery. At surgery their tumors were removed to the extent possible. Twenty-seven patients were treated with full-brain radiation for a total dose of 6000 rad delivered in daily fractions of 200 rad. The remaining four patients received whole-brain radiation of 3000–4800 rad and additional coned-down doses of 1500–3020 rad to the tumor site. Neuropathology of the resected tumors showed glioblastoma multiforme in 19 patients, gliosarcoma in two, anaplastic astrocytoma in five, and mixed anaplastic glioma in five [4, 5].

Twenty-two patients received IV BCNU (1,3-bis[2-chloroethyl]-1-nitrosourea). Ten of these were treated with BCNU only. The remaining 12 patients received combinations of BCNU and methyl-prednisolone, hydroxyurea, procarbazine, and VM-26 (epipodophyllotoxin). Four

Received July 28, 1987; accepted after revision November 2, 1987.

Presented in part at the 25th annual meeting of the American Society of Neuroradiology, New York, May 1987.

This work was supported in part by USPHS grants CA36014-03S1 (NCI) and MH36969 (NIMH).

¹ Department of Radiology (Neuroradiology), New York University Medical Center, 560 First Ave., New York, NY 10016. Address reprint requests to A. George.

² Department of Psychiatry, New York University Medical Center, New York, NY 10016.

³ Department of Neurology, New York University Medical Center, New York, NY 10016.

⁴ Department of Neurosurgery, New York University Medical Center, New York, NY 10016.

AJNR 9:517–522, May/June 1988

0195–6108/88/0903–0517

© American Society of Neuroradiology

patients were treated with methyl CCNU only, two with streptotocin only, two with procarbazine only, and one with high-dose methyl-prednisolone only.

Serial CT scans were obtained between 1974 and 1986 both with and without IV iodinated contrast administration. The first postoperative scan analyzed was the one obtained at the end of radiation treatment, usually 6–7 weeks after surgery. Subsequent scans were obtained at 3 months, 6 months, 9 months, and 1 year. The second and third year, scans were obtained at 6-month intervals and after that at 1- to 2-year intervals.

For the purposes of statistical analysis, all CT and clinical ratings were considered to have been obtained at one of the following time points: 1, 6, 12, 24, 48, 72, or 96+ months. Scans obtained at time points that did not coincide with the above were considered for the purpose of this analysis to have been obtained at the time point nearest to the actual date of the scan. For example, a scan obtained 7 months after surgery would be included in the 6-month time point. If more than one clinical or CT examination were done at one time point, an average of the results was used for that time point.

All scans were evaluated subjectively for ventricular enlargement, cortical atrophy, and the presence and severity of leukoencephalopathy. Ventricular enlargement and cortical atrophy were rated by using a 5-point scale, where 0 = normal (i.e., no evidence of enlargement), 1 = mild, 2 = moderate, 3 = moderate to severe, and 4 = severe enlargement. The same scale was applied to the subjective assessment of leukoencephalopathy. For these evaluations, 0 = no evidence of leukoencephalopathy; 1 or mild = faintly visualized low-attenuation lesions, usually in the periventricular region and typically frontal in location; 2 or moderate = involvement of less than one-third of the periventricular white matter by low-attenuation lesions that were generally diffuse and anterior as well as posterior; 3 or moderate-to-severe = involvement of more than one-third but less than two-thirds of the visualized white matter by low-attenuation lesions; 4 or severe = diffuse involvement of virtually all the visualized white matter by low-attenuation lesions.

The rating scores for each point were averaged to generate a group mean. The subjects were then divided into two age groups: the younger group was composed of 13 patients whose ages ranged from 16–40 years; the older group comprised 18 patients ages 41–68 years.

Clinical status was determined by using two measures: the mental status assessment and the Karnofsky score. The mental status assessment has been used by the Brain Tumor Study Group and the Brain Tumor Cooperative Group in Phase III Protocols 1975-01 [6], 1977-02 [7], and 1980-01 (USPHS National Cancer Institute grant CA 36014-03S1, unpublished data). The mental status assessment consists of a set of 10 questions designed to evaluate orientation, memory, arithmetic calculations, spelling, judgment, and ability to conceptualize. A 5-point rating scale was used based on the results of the above assessments: 0 = normal mental status, 1 = minimal impairment, 2 = moderate impairment, 3 = severe impairment, and 4 = marked impairment. Aphasic patients did not participate in the mental status measurement.

A Karnofsky score [8] using a scale of 10–100 was also generated at each evaluation. This scale is detailed in Table 1.

Results

A progressive increase in the incidence of leukoencephalopathy (Figs. 1 and 2) was shown for both groups over time (Table 2, Fig. 3). The incidence of leukoencephalopathy in the older group was greater than in the younger group, except during the first 6 months. At 24 months after surgery, all

TABLE 1: Karnofsky Rating

Score	Criteria	Definition
100	Normal, no complaints, no evidence of disease.	Able to carry on normal activity and to work; no special care is needed.
90	Able to carry on normal activity; minor signs or symptoms of disease.	
80	Able to carry out normal activity with effort; some signs or symptoms of disease.	
70	Able to care for self, but unable to carry on normal activity or to do active work.	Unable to work, but able to live at home and care for most personal needs; a varying amount of assistance is needed.
60	Requires occasional assistance but is able to care for most personal needs.	
50	Requires considerable assistance and frequent medical care.	
40	Disabled; requires special care and assistance.	Unable to care for self; requires equivalent of institutional or hospital care; disease may be progressing rapidly.
30	Severely disabled; hospitalization is indicated, although death not imminent.	
20	Very sick; hospitalization necessary; active supportive treatment is necessary.	
10	Moribund; fatal processes progressing rapidly.	
0	Dead.	

patients in the older group had developed evidence of leukoencephalopathy; only 58% of the younger group showed evidence of leukoencephalopathy at this time (Fig. 2). At 4 years all patients who survived, both in the younger and older groups, had developed leukoencephalopathy. Except during the first 6 months, the severity of leukoencephalopathy was always greater in the older group (Table 2, Fig. 4).

Ventricular enlargement representing central cerebral atrophy (Figs. 1 and 2) tended to be greater in the older group (Table 3, Fig. 5). Progressive ventricular enlargement was shown in both groups beginning with the first postradiation scan. Similar results were shown for cortical atrophy (Table 3, Figs. 1, 2, and 6). For statistically significant differences see Tables 2 and 3.

Despite the progressive atrophic changes and the progressive leukoencephalopathy, the clinical status of the younger patients as measured by both the mental status score and the Karnofsky score remained nearly normal throughout their period of survival (Table 4, Figs. 7 and 8). Only patients in the younger group who survived more than 6 years began to show a decline in clinical status; the older group on the other

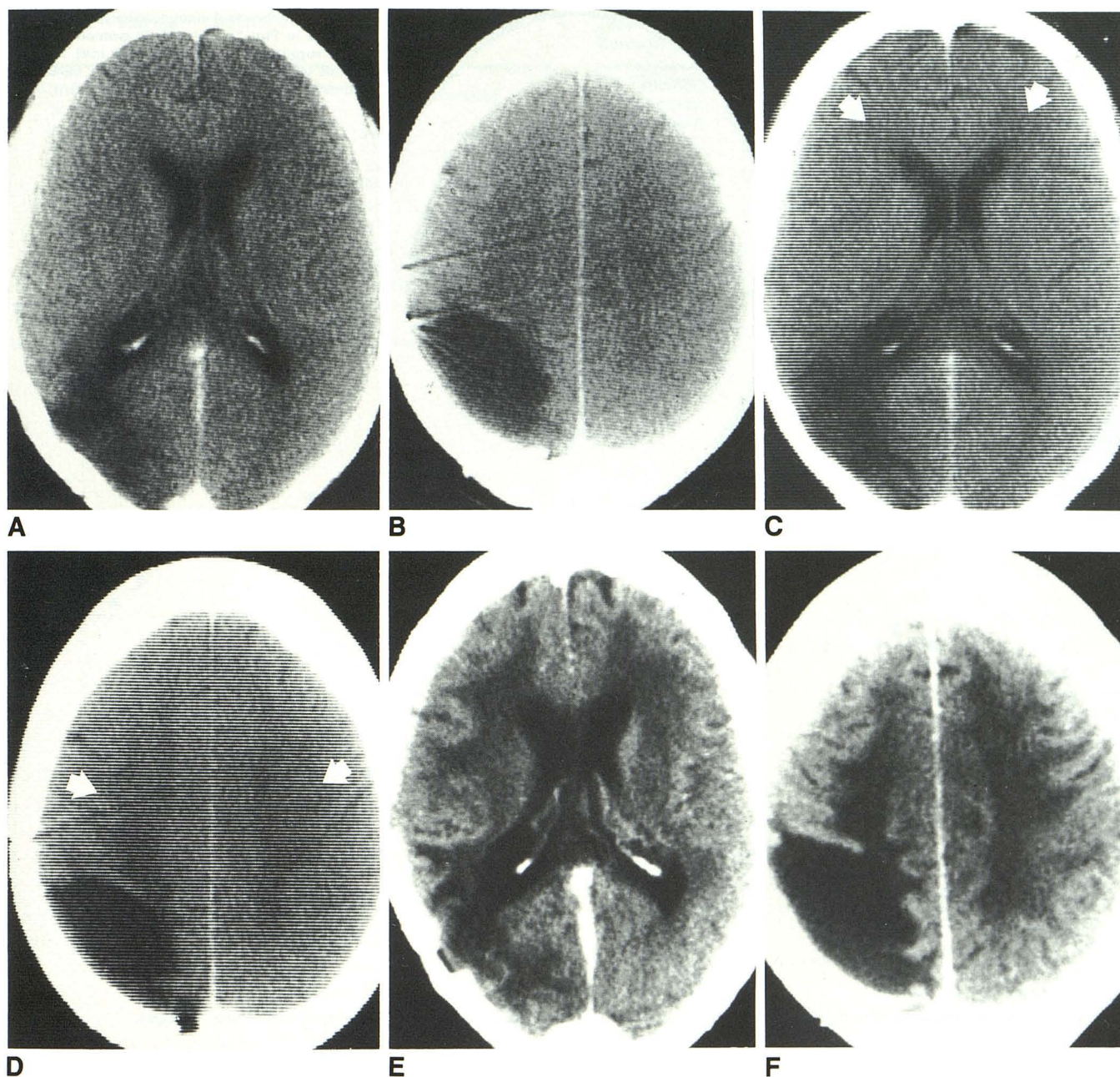


Fig. 1.—Progressive leukoencephalopathy in 55-year-old woman. Right parietooccipital glioma.

A and B, 6 months after surgical resection, 6000 rad whole-head irradiation and ongoing chemotherapy. No evidence of leukoencephalopathy; normal mental status. Karnofsky = 90.

C and D, 1 year after surgery, mild decrease in attenuation of white matter (arrows) consistent with leukoencephalopathy. Mild cortical and central atrophy. Mental status remains normal. Karnofsky = 90.

E and F, 4 years after surgery, leukoencephalopathy is now severe. There is also severe ventricular and cortical atrophy. Moderate memory loss. Karnofsky = 60.

hand showed progressive clinical deterioration beginning in the immediate postoperative period.

Discussion

The prognosis of patients with malignant glioma after surgical resection, chemotherapy, and radiation therapy is poor

[9, 10]. In an earlier report from this medical center, only 14% of patients with malignant astrocytomas lived at least 2 years [11]. It appears from the current study that the longer the patients survive, the more likely they are to develop chronic brain changes, including brain atrophy and evidence of leukoencephalopathy. We believe that one of the most important results of this study is the finding that patients under the age

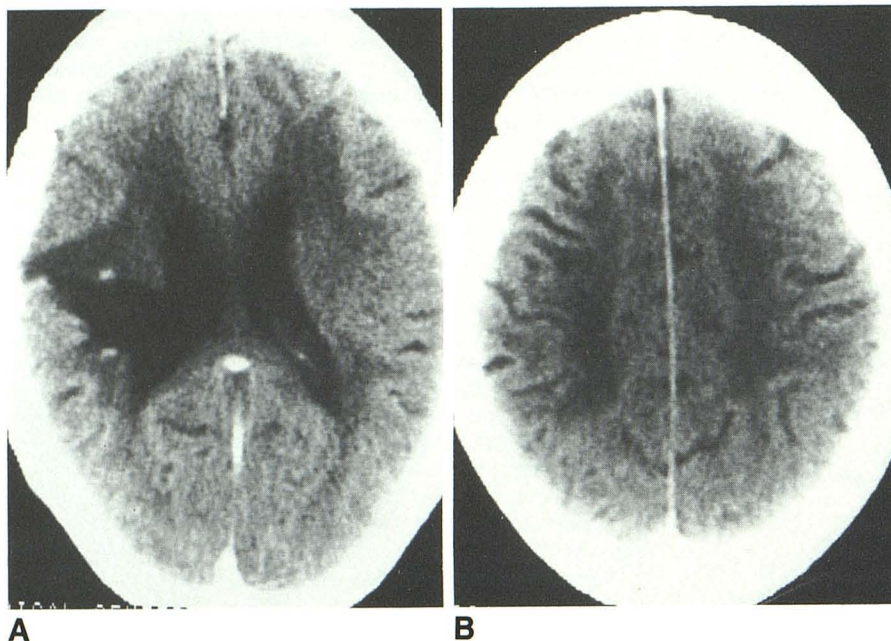


Fig. 2.—Severe leukoencephalopathy (comparable to Fig. 1). 35-year-old woman 2 years after surgery and irradiation (6000 rad). No evidence of tumor; severe brain atrophy; minimally abnormal mental status. Karnofsky = 90.

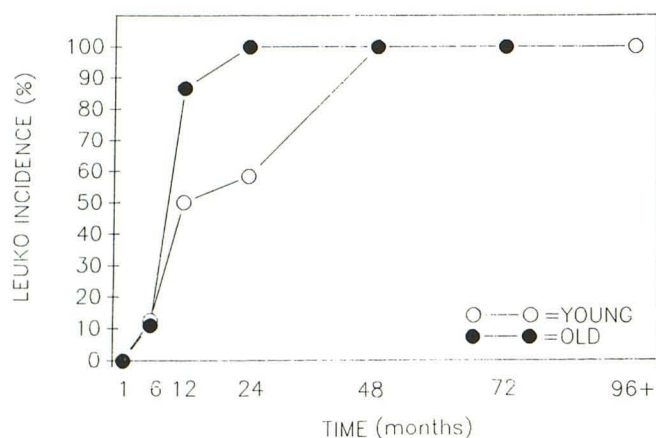


Fig. 3.—Progressive incidence of white matter disease.

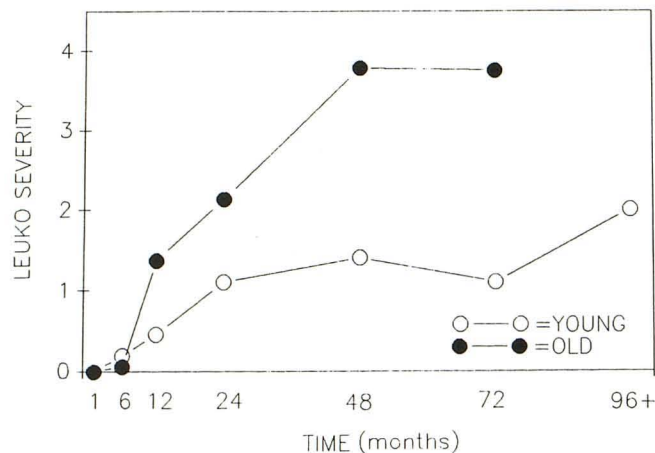


Fig. 4.—Progressive severity of white matter changes.

TABLE 2: Incidence and Severity of Leukoencephalopathy

Time After Surgery (months)	Percentage Incidence ^a		Severity ^b	
	Young	Old	Young	Old
1	0 (0/9)	0 (0/15)	0 (9)	0 (15)
6	12.5 (1/8)	11.1 (2/18)	0.19 (8)	0.06 (18)
12	50.0 (6/12)	86.7 (13/15)	0.45 (12)	1.37 (15) ^c
24	58.3 (7/12)	100 (13/13)	1.10 (12)	2.13 (13)
48	100 (6/6)	100 (5/5)	1.40 (6)	3.78 (5) ^d
72	100 (3/3)	100 (2/2)	1.10 (3)	3.75 (2) ^d
96+	100 (3/3)		2.0 (3)	

Note.—The Student t test was used for statistical analysis.

^a Number of patients with leukoencephalopathy/number in group in parentheses.

^b Severity rating at each time period expressed as group mean. Number of patients in parentheses.

^c $p < .05$.

^d $p < .01$.

of 40 were able to tolerate these chronic progressive brain lesions and to maintain a normal mental status for the duration of their survival, while patients over the age of 40 showed progressive cognitive and clinical decline. The differences in the two age groups may be interpreted in light of the possible expected changes due to normal aging. The known increased prevalence of hypertension and microvascular disease [12] in the older population may have partially contributed to the increased prevalence and severity of the leukoencephalopathy seen in our older group.

CT white matter lesions in brain tumor patients treated with radiation and chemotherapy have been observed previously and have been attributed to radiation necrosis [13]. We believe that the radiolucencies demonstrated in our study patients represent demyelination and microvascular changes but not frank radiation necrosis. The lesions we describe were

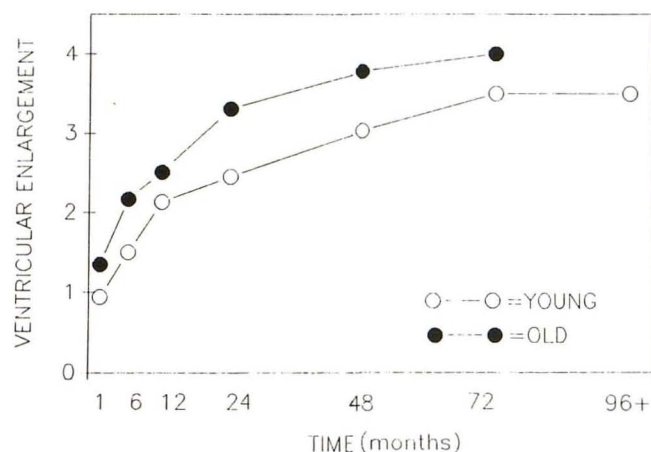
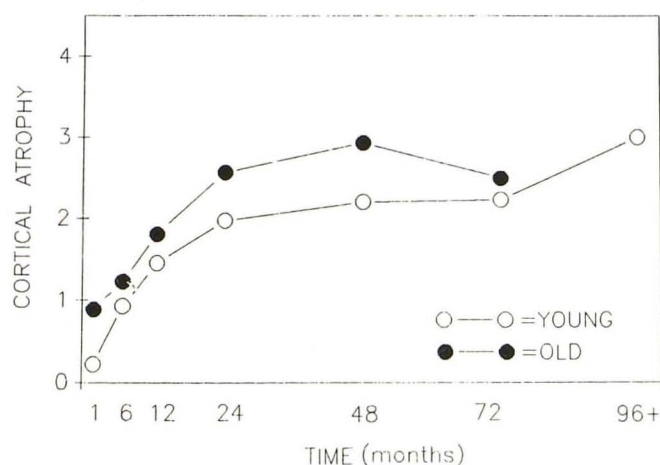
TABLE 3: Findings in Patients with Cerebral Atrophy

Time After Surgery (months)	Ventricular Enlargement		Cortical Atrophy	
	Young	Old	Young	Old
1	0.94 (9)	1.35 (15)	0.22 (9)	0.89 (15) ^a
6	1.50 (8)	2.17 (18) ^a	0.93 (8)	1.23 (18)
12	2.13 (11)	2.51 (15)	1.45 (11)	1.81 (15)
24	2.45 (11)	3.31 (13) ^a	1.97 (11)	2.57 (13) ^b
48	3.03 (6)	3.78 (5) ^a	2.20 (6)	2.93 (4)
72	3.50 (3)	4.00 (2)	2.23 (3)	2.50 (2)
96+	3.50 (3)		3.00 (3)	

Note.—The Student t test was used for statistical analysis. Number of patients in parentheses. Results at each time period expressed as group mean.

^a $p < .01$.

^b $p < .05$.

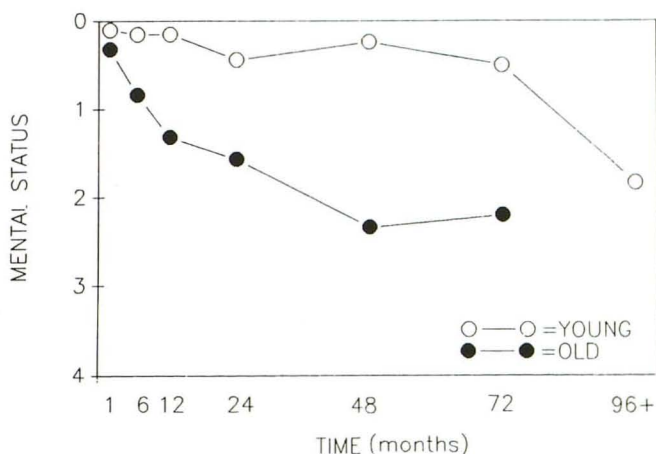
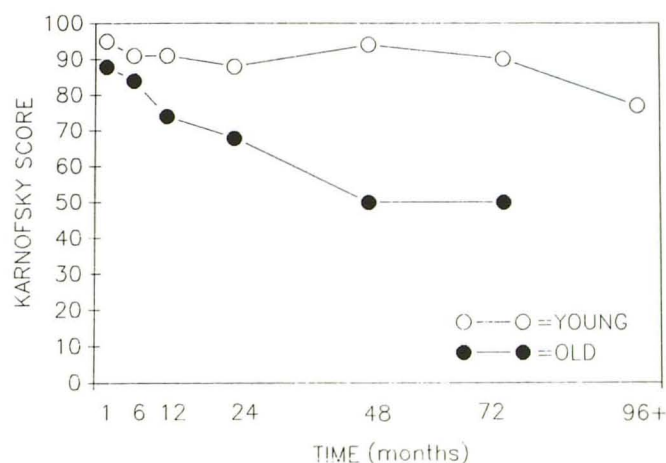
**Fig. 5.—Longitudinal progression of central cerebral atrophy.****Fig. 6.—Longitudinal progression of cortical atrophy.****TABLE 4: Clinical Assessments: Mental Status Score vs Karnofsky Score**

Time After Surgery (months)	Mental Status Score		Karnofsky Score	
	Young	Old	Young	Old
1	0.10 (10)	0.32 (14)	95 (10)	88 (15)
6	0.15 (10)	0.84 (18) ^a	91 (10)	84 (18)
12	0.15 (13)	1.32 (14) ^a	91 (13)	74 (16) ^a
24	0.44 (13)	1.57 (12) ^a	88 (13)	68 (13) ^a
48	0.24 (7)	2.34 (5) ^a	94 (7)	50 (5) ^b
72	0.50 (3)	2.20 (1)	90 (3)	50 (1)
96+	1.83 (3)		77 (3)	

Note.—The Student t test was used for statistical analysis. Number of patients in parentheses. Results at each time period expressed as group mean.

^a $p < .01$.

^b $p < .05$.

**Fig. 7.—Longitudinal progression of mental status.****Fig. 8.—Longitudinal progression of clinical status.**

not associated with mass effect and showed no evidence of enhancement, which are the features typically associated with radiation necrosis [3, 13]. In a study of patients with symptoms of delayed radiation necrosis who had received 6000

rad or more for the treatment of intracranial tumors, 14% were found to have delayed radiation necrosis [14]. In our subjects, in addition to the leukoencephalopathy, one of the 18 older patients and one of the 13 younger patients devel-

oped radiation necrosis with rapidly increasing mass effect and edema and blood-brain barrier disruption visualized with contrast enhancement. In both cases the lesions regressed spontaneously and were therefore considered to be due to radiation necrosis.

Leukoencephalopathy has been described in association with radiation therapy with or without intrathecal chemotherapy primarily in childhood leukemias; pathologically, it is characterized by demyelinating changes of the white matter and astrocytosis [15, 16]. The lesions appear a few weeks to several months after radiation treatment. We found the earliest CT evidence of leukoencephalopathy, which we believe to be a pathologically similar phenomenon, at 5 months after treatment in the older patient group and at 6 months after treatment in the younger group. Progression to the centrum semiovale was shown on subsequent scans.

In a review article, Kingsley and Kendall [17] described similar periventricular low-attenuation changes of the white matter in patients with astrocytoma treated with radiation, and in patients with acute lymphoblastic leukemia treated with radiation and intrathecal methotrexate. They attributed these white matter changes to "mineralizing microangiopathy" and "radiation atrophy." The same authors also found cerebral atrophy in one-third of children with acute lymphatic leukemia treated with prophylactic craniospinal radiation and intrathecal methotrexate. These earlier studies did not attempt to define the longitudinal progression or clinical significance of chronic brain changes after treatment with radiation.

In summary, all glioma survivors developed progressive cerebral atrophy. Survivors over the age of 40 had greater prevalence and severity of leukoencephalopathy than did survivors under the age of 40. Despite the presence of progressive brain changes, survivors under the age of 40 maintained nearly normal mental status and Karnofsky scores until their death; but survivors over the age of 40 showed progressive clinical decline.

ACKNOWLEDGMENTS

We thank Joan Askew for her assistance in preparing this manuscript.

REFERENCES

1. Lieberman A, Ransohoff J. Treatment of primary brain tumors. *Med Clin North Am* 1979;63:835-848
2. Pay NT, Carella RJ, Lin JP, and Kricheff II. The usefulness of computed tomography during and after radiation therapy in patients with brain tumors. *Radiology* 1976;121:79-83
3. Deck MDF. Imaging techniques in the diagnosis of radiation damage to the central nervous system. In: Gilbert HA, Kagan AR, eds. *Radiation damage to the nervous system: a delayed therapeutic hazard*. New York: Raven Press, 1980:107-127
4. Burger PC, Vogel SF, Green SB, Strike TA. Glioblastoma multiforme and anaplastic astrocytomas. *Cancer* 1985;56:1106-1111
5. Russell DS, Rubinstein LJ. *Pathology of tumours of the nervous system*. Baltimore: William & Wilkins, 1977:149-150, 236-238
6. Green SB, Byar DB, Walker MD, et al. Comparisons of carmustine, procarbazine, and high-dose methylprednisolone as additions to surgery and radiotherapy for the treatment of malignant gliomas. *Cancer Treat Rep* 1983;67:121-132
7. Green SB, Byar DP, Strike TA, et al. Randomized comparisons of BCNU, streptozotocin, radiosensitizer and fractionation of radiotherapy in the postoperative treatment of malignant glioma. *Proc Am Soc Clin Oncol* 1984;3:260
8. Karnofsky DA, Abelman WH, Craver LF, Burchenal TH. The use of the nitrogen mustards in the palliative treatment of carcinoma, with particular reference to bronchogenic carcinoma. *Cancer* 1948;1:634
9. Walker MD. Brain and peripheral nervous system tumors. In: Holland JF, Frei E III eds. *Cancer medicine*, 2nd ed. Philadelphia: Lea & Febiger, 1982:1603-1647
10. Saloman M. Survival in glioblastoma: historical perspective. *Neurosurgery* 1980;7:435-439
11. Lieberman AN, Foo SH, Ransohoff J, et al. Long-term survival among patients with malignant brain tumors. *Neurosurgery* 1982;10:450-453
12. George AE, de Leon MJ, Gentes CI, et al. Leukoencephalopathy in normal and pathologic aging: 1. CT of brain lucencies. *AJNR* 1986;7:561-566
13. Mikhael MA. Radiation of necrosis of the brain: correlation between patterns of computed tomography and dose of radiation. *J. Comput Assist Tomogr* 1979;3(2):241-249
14. Mikhael MA. Dosimetric considerations in the diagnosis of radiation necrosis of the brain. In: Gilbert HA, Kagan AR, eds. *Radiation damage to the nervous system: a delayed therapeutic hazard*. New York: Raven Press, 1980:59-91
15. Grossman RI, Zimmerman RA. Central nervous system abnormalities in the immunocompromised host. In: Latchaw RE, ed. *Computed tomography of the head, neck and spine*. Chicago: Year Book Medical, 1985:137-151
16. Sheline GE, Ware WM, Smith V. Therapeutic irradiation and brain injury. *Int J Radiat Oncol Biol Phys* 1980;6:1215-1228
17. Kingsley DPE, Kendall BE. CT of the adverse effects of therapeutic radiation on the central nervous system. *AJNR* 1981;2:453-460