



Providing Choice & Value
Generic CT and MRI Contrast Agents

**FRESENIUS
KABI**

CONTACT REP

AJNR

Temporoparietal dermoid cysts with intracranial extension.

G Currarino and J C Rutledge

AJNR Am J Neuroradiol 1988, 9 (2) 385-387

<http://www.ajnr.org/content/9/2/385.citation>

This information is current as
of July 19, 2025.

Temporoparietal Dermoid Cysts with Intracranial Extension

Guido Currarino¹ and Joe C. Rutledge²

We report two young children, each with an unusual dumbbell dermoid cyst and sinus that was unexpectedly located in the temporoparietal region of the skull at a site where epidermoids are usually found. Both dermoid cysts produced unusual radiographic changes in the skull, which may be characteristic of this type of lesion.

Case Reports

Case 1

A 9-month-old boy presented with a swelling in his left temporal area first noted by his mother 2 weeks prior to admission. Initially, the mass was soft and tender and the overlying skin was erythematous. Subsequently it enlarged and became firm and nontender. On physical examination, a firm, nontender 3 × 1 cm mass was palpated in the left temporal area, and a small black spot was noted on the overlying skin.

Films of the skull (Fig. 1A) showed a vertical 3 × 0.4 mm groove with slightly sclerotic margins in the left temporal area, involving primarily the greater wing of the sphenoid. A CT scan of the skull (Fig. 1B) showed a left temporal mass and a vertical groove with raised margins in the inner table of the skull, corresponding to the defect seen in the skull films.

At surgery, white, cheesy material was found extruding from a small defect in the temporal bone. Adjacent to this area, beneath the temporal muscle, was some purulent material and a sinus tract leading to the skin anterior and above the left ear. The soft-tissue cyst, overlying skin, and a bone flap centering on the lesion were removed together with an intracranial, decompressed part of the cyst that showed no attachment to the dura.

Histologic examination of the surgical specimen (Fig. 1C) showed a ruptured dermoid cyst with a few eccrine glands and hair follicles beneath the epithelium lining. The cyst was surrounded by granulation tissue, and the section of the bone showed periosteal reaction with new bone formation, granulation tissue, and marked acute inflammation. Foreign-body giant cells were evidence of reaction to previous rupture.

Case 2

A 17-month-old girl was admitted to the hospital because of an asymptomatic enlarging mass in the left parietal region, first noted by her mother when the child was 6 months old. A firm, nontender, fixed

mass about 2–3 cm in diameter was palpated above and behind the left ear. The overlying skin was intact.

Skull films (Fig. 2A) showed an almost vertical 3.5 × 0.6 cm groove with slightly sclerotic margins in the posteroinferior quadrant of the left parietal bone. A CT scan of the head (Fig. 2B) showed a vertical groove with raised edges in the inner table of the cranium, corresponding to the defect seen in the skull films.

At surgery, a cystic structure was found in the subgaleal space that penetrated the outer table of the skull through a small defect. The intracranial component of the dumbbell cystic structure together with several centimeters of the adherent dura and the subcutaneous component were removed.

Histologic examination of the surgical specimen showed findings similar to those described in case 1. A ruptured dermoid cyst was found involving a scooped-out area of the calvarium with adjacent thick, mature bone. Foreign-body granulomatous reaction was associated with hair follicles and sweat and sebaceous glands.

Discussion

Congenital dermal (inclusion) cysts of the scalp and calvarium are of two types, dermoid cysts and epidermal cysts of the diploe. Dermoid cysts have a well-developed fibrous wall lined by a stratified squamous epithelium and contain elements of mesodermal origin, such as hair follicles and sweat and sebaceous glands, which provide filling for the cavity. They are located preferentially in the periorbital region, over the anterior fontanelle, or in the occipital area. Periorbital dermoid cysts [1, 2] present as a small, soft-tissue mass in the outer third of the eyebrow without cutaneous changes or intracranial extension. Dermoid cysts of the anterior fontanelle [3–6] are located in the subgaleal space over the anterior fontanelle. They may be associated with a flattening or depression of the external table of the calvarium but have no intracranial extension or cutaneous involvement. Occipital dermoid cysts and sinuses [7, 8] are found in the center of the occipital bone in the midline, where there is a bony defect through which the dermal sinus extends intracranially. A cutaneous dimple is generally present at the site of the lesion.

In contrast to dermoid cysts, epidermal cysts of the diploe [9–12] do not contain hair follicles or glandular structures, and are filled with keratinized epithelial debris and cholesterol

Received January 16, 1986; accepted after revision March 20, 1986.

¹ Department of Radiology, University of Texas Southwestern Medical School and Children's Medical Center, Dallas, TX 75235. Address reprint requests to G. Currarino, Children's Medical Center, 1935 Motor St., Dallas, TX 75235.

² Department of Pathology, University of Texas Southwestern Medical School and Children's Medical Center, Dallas, TX 75235.

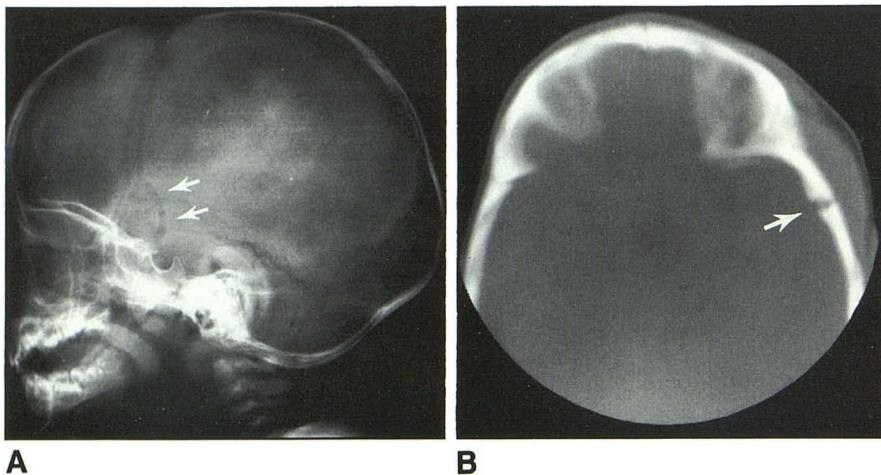


Fig. 1.—Case 1.
A, Lateral view of skull. Vertical linear defect with slightly sclerotic margins in left temporo-parietal area involves primarily the greater wing of the sphenoid (arrows).

B, CT scan of head. Swelling of epicranial soft tissues in left temporal area with an underlying vertical groove in inner aspect of calvarium (arrow), which corresponds to changes seen in skull films. No intracranial mass was demonstrated.

C, Transverse histology section of the greater wing of the sphenoid at level of lesion, which was removed surgically. Crater seen on intracranial aspect of bony fragment corresponds to groove on inner surface of calvarium shown in CT scan (arrow in B). Remnants of intracranial cyst wall (W).

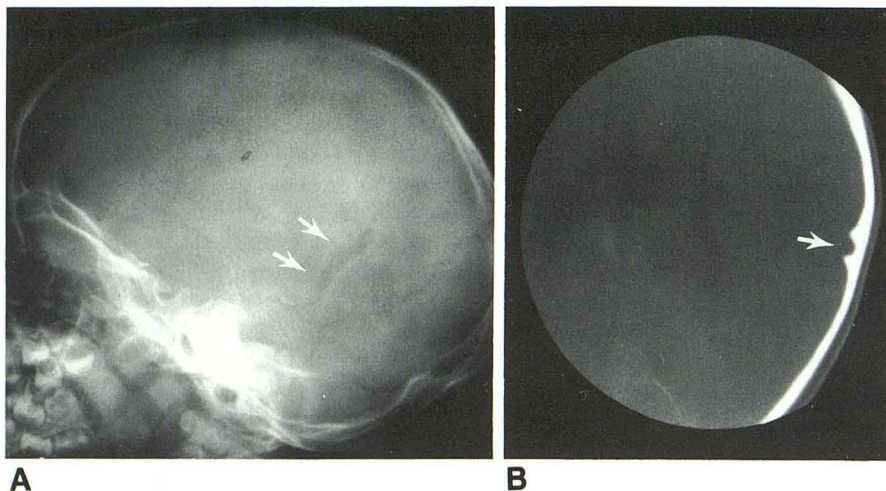
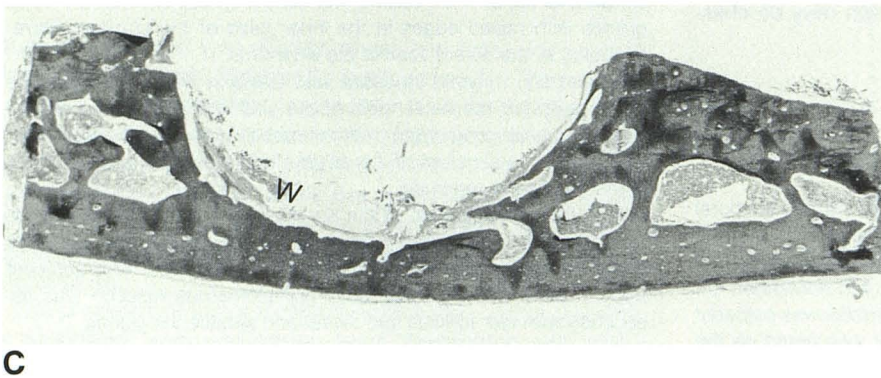


Fig. 2.—Case 2.
A, Lateral view of skull. Almost vertical linear defect with slightly sclerotic margins in posteroinferior aspect of left parietal bone (arrows).

B, CT scan of head. Vertical groove in inner aspect of left parietal bone corresponds to defect seen in skull films (arrow). No intra- or extracranial mass was demonstrated.

crystals. They are usually found in the lateral aspect of the frontal or parietal bone, frequently near the coronal suture. Less commonly, they occur in the squamosa of the temporal bone, in the occipital bone, and, rarely, in the midline of the frontal or occipital area. In skull films, epidermoid cysts appear as round or oval radiolucent defects 0.5–1.0 cm in diameter with smooth sclerotic margins. The outer table alone is in-

involved in about one-third of the cases, and the inner table alone in 10–15% of cases. Both tables are involved in more than 50% of the cases, and in some of them there is an involvement of the dura with occasional compression of the brain [12].

Midline dermal cysts probably originate from ectodermal rests that become pinched-off in the process of closure of the

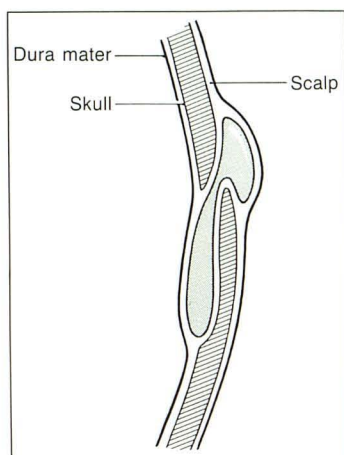


Fig. 3.—Diagram of dumbbell dermoid cyst and corresponding skull defect observed in the two patients.

neural groove during the first weeks of gestation. In the case of dermoid cysts that are not in the midline, a later onset is postulated and the embryologic cause may be an incomplete separation of the neural tube from the surface ectoderm. An epidermoid cyst results if the inclusion contains only ectodermal elements, whereas an inclusion of both ectodermal and mesodermal elements results in a dermoid cyst.

The two patients reported in this paper had a ruptured dermoid cyst in the temporoparietal region of the skull. The diagnosis of dermoid cyst was made in both instances on the basis of the glandular structures present in the cyst wall. Each cyst had an epicranial and an epidural component (Fig. 3), and the two parts were connected through a small defect in the greater wing of the sphenoid in the first patient and in the parietal bone in the second.

We have not been able to find any previous reports of such

dumbbell dermoid cysts in the temporoparietal region of the skull, an area of the skull that is more typical for epidermoid cyst of the diploe than for true dermoid cyst. However, if the two lesions are indeed as closely related developmentally as they appear to be, then an overlap in location, although exceptional, is not inconceivable. In both cases the cyst caused, in the skull films and CT scans, an almost vertical groove in the inner surface of the calvarium with slightly sclerotic borders. This is a most unusual feature and may be characteristic of this type of lesion.

REFERENCES

1. Cullen JF. Orbital diploic dermoids. *Br J Ophthalmol* 1974;58:105-106
2. New GB, Erich JB. Dermoid cysts of the head and neck. *Surg Gynecol Obstet* 1937;65:48-55
3. Adeloye A, Odeku EL. Congenital subgaleal cysts over the anterior fontanelle in Nigerians. *Arch Dis Child* 1971;46:95-98
4. Chaudhari AB, Lapado F, Mordt VPN, Choudhuri KJ, Naseem A. Congenital inclusion cyst of the subgaleal space. *J Neurosurg* 1982;56:540-544
5. Garza-Mercado R, Tamez-Montes D. Congenital subgaleal (epidermoid) inclusion cyst of the anterior fontanelle in a Mexican female child: case report. *Neurosurgery* 1983;12:451-453
6. Glasauer FE, Levy LF, Aughterlone WC. Congenital inclusion dermoid cysts of the anterior fontanelle. *J Neurosurg* 1978;48:274-278
7. Logue V, Till K. Posterior fossa dermoid cysts with special reference to intracranial infection. *J Neurol Neurosurg Psychiatry* 1952;15:1-12
8. Matson DD. *Neurosurgery of infancy and childhood*, 2nd ed. Springfield, Illinois: Charles C Thomas, 1969:96-112
9. Bucy PC. Intradiploic epidermoid (cholesteatoma) of the skull. *Arch Surg* 1935;31:190-199
10. Haig PV. Primary epidermoids of the skull including a case with malignant changes. *AJR* 1956;76:1076-1080
11. Holthusen W, Lassrich MA, Steiner C. Epidermoids and dermoids of the calvarial bones in early childhood: their behaviour in the growing skull. *Pediatr Radiol* 1983;13:189-194
12. Skandalakis JE, Godwin JT, Mabon RF. Epidermoid cyst of the skull: report of four cases and review of the literature. *Surgery* 1958;43:990-1001