



Get Clarity On Generics

Cost-Effective CT & MRI Contrast Agents



FRESENIUS
KABI

WATCH VIDEO

AJNR

Radiologic imaging of symptomatic ligamentum flavum thickening with and without ossification.

A Stollman, R Pinto, V Benjamin and I Kricheff

AJNR Am J Neuroradiol 1987, 8 (6) 991-994

<http://www.ajnr.org/content/8/6/991>

This information is current as
of August 27, 2025.

Radiologic Imaging of Symptomatic Ligamentum Flavum Thickening with and Without Ossification

A. Stollman^{1,2}
R. Pinto¹
V. Benjamin³
I. Kricheff¹

Thickening of the ligamenta flava with and without ossification in the thoracic and lumbar regions is a frequent finding on CT scanning; however, it is not widely appreciated as a possible primary cause of compressive cord, cauda equina, and nerve-root symptoms. We present observations from a series of seven patients whose symptoms were caused exclusively or largely by thickened ligamenta flava in the thoracic and lumbar regions. The findings were best demonstrated on myelography. One of our cases had been missed on previous MR, as would be expected with the null signal of calcification. CT scanning necessitates an extended window to ensure discrimination of an ossified ligament from thecal metrizamide. Thickened ligamenta flava are often found in conjunction with degenerative disease and spinal stenosis at multiple levels and should not be ignored as a possible major contributing factor to the patient's symptoms. In addition, those patients with a secondary block from a thickened ligamentum flavum should be studied from above with C1-C2 puncture to rule out other levels of clinically significant disease.

Attention to the particular findings of thickened ligamenta flava is important since surgical intervention must involve removal of the entire offending ligament(s); otherwise clinical symptoms may not be relieved.

Ligamenta flava (LF) thickening with and without ossification is a frequent finding on CT scanning; however, it is not widely appreciated as a possible primary cause of cord, cauda equina, or nerve-root symptoms [1-3]. We present observations on a series of seven patients whose symptoms were caused exclusively or largely by thickened LF with and without ossification in the thoracic and lumbar regions.

Materials and Methods

Seven patients 29-75 years old seen over the past 4 years at the New York University Medical Center and its affiliate, the Manhattan Veterans Administration Hospital, were included in this study. All had symptoms and signs of either cord or cauda equina compression including paraparesis to spastic paraplegia, numbness, and/or severe low back pain. The patients were studied with nonionic-contrast-medium myelography. One patient was also studied with lateral plain-film tomography, and a second patient was studied with MR. All patients underwent surgical intervention.

Results

The results of the study are included in Table 1. In all patients surgical intervention resulted in marked resolution of the symptoms over follow-up periods of 6 months to 4 years. One patient had recurrent symptoms at 6 months with a plateau of mild lower-extremity weakness. Repeat CT myelography demonstrated a second, higher level of block from calcified LF. The patient is currently being followed. In the majority of patients (four of seven), degenerative disease—including thickened and ossified LFs, facet joint changes, and disk herniations—was found at multiple levels.

Received August 20, 1986; accepted after revision April 21, 1987.

¹ Department of Neuroradiology, New York University Medical Center, 550 First Ave., New York, NY 10016.

² Present address: Department of Radiology, The Mount Sinai Medical Center, One Gustave L. Levy Pl., New York, NY 10029. Address reprint requests to A. Stollman.

³ Department of Neurosurgery, New York University Medical Center, New York, NY 10016.

AJNR 8:991-994, November/December 1987

0195-6108/87/0806-0991

© American Society of Neuroradiology

TABLE 1: Clinical and Radiographic Summary of Patients with Symptomatic Thickening of the Ligamenta Flava (LF)

Case No.	Age	Gender	Clinical History	Radiologic Findings at Clinical Level	Surgery and Clinical Course
1	60	M	Progressive leg weakness; proximal greater than distal cramping of thighs; numbness of feet; recurrent symptoms 6 months later, after initial improvement from first surgery	Initial presentation: complete block at T11–T12 from thickened ossified LF; second presentation 6 months later: complete block at T10–T11 from thickened, ossified LF	Removal of ossified LF with bilateral partial medial facetectomy, improved after initial surgery; recurrent milder symptoms after 6 months; now being followed without repeat surgery
2	29	M	3-week gradual onset of spastic paraplegia	High-grade block at T2–T3 with enlarged and ossified LF; additional enlarged, ossified LFs at T3–T4 and T4–T5	T2–T5 laminectomy with removal of ossified LF; complete resolution of spastic paraplegia at 8-month follow-up
3	57	M	Difficulty walking; hypesthesia at T12 dermatome; hyperreflexia in lower extremity with up-going toes	Complete block at T10–T11 from enlarged, ossified LF	T10–T11 radical laminectomy, removal of LF, and partial medial facetectomies; removal of 3-mm R paramedian T10–T11 disk not appreciated on CT myelogram; clinical improvement at 1-year follow-up
4	74	F	Severe low back pain with straight leg raising at 15°; inability to walk owing to pain	High-grade block at L3–L4 with marked degenerative spinal stenosis at L2–L3, L3–L4, and L4–L5 with ossified, thickened LF	L2–L3, bilateral L3–L4, R L4–L5 hemilaminectomies; removal of LFs and partial medial facetectomies; clinical improvement at 6-month follow-up
5	56	M	10-year history of progressive low back pain radiating to buttocks and thighs	L4–L5 spinal stenosis with thickened LF and facet joint osteophytes projecting posteriorly; L5–S1 herniated nucleus pulposus	L4–L5 laminectomies; removal of LF, noted to be compressing nerve root; L5–S1, removal of disk; clinical improvement at 4-year follow-up
6	75	F	Low back pain; weakness of L anterior tibialis	Complete block at L4–L5; facet joint osteoarthritis and thickened LF	L4–L5 hemilaminectomies with removal of LF; partial medial facetectomies; marked relief of pain continued at 1-year follow-up
7	59	M	Low back pain; bilateral weakness of anterior tibialis	L4–L5 spinal stenosis with thickened LF, facet joint osteoarthritis	L4–L5 laminotomies; removal of LF; medial facetectomies; removal of midline herniated nucleus pulposus; clinical improvement continued at 8 months

Although it is possible to perform a discectomy and/or facetectomy without resecting the LF, if a thickened LF is seen, it is removed completely.

Discussion

The anatomy of the LF has been described well [4–6]. The LF or yellow ligaments are composed mainly of elastic connective tissue fibers in a longitudinal array. They are the most purely elastic tissue in the human body [4, 5]. The ligaments extend from the anterior/inferior aspect of the lamina above a disk space to the posterior superior surface of the lamina below the disk space. Each half of the LF extends laterally from midline to the intervertebral foramen forming the posterior boundary and roof of the foramen. The ligaments then

turn dorsally outside the foramina and fuse with the capsule of the articular facets. The thickness of the LF gradually increases from the cervical to the lumbar regions [6]. The LF is approximately 1.5 mm in thickness at the C2–C3 level, 2.0 mm at the T11–T12 level, and 4–6 mm in the lower lumbar region. Thickening of the LF has been reported to be produced by an increase in the amount of fibrous tissue within the ligaments, which is believed to be from a degenerative change or aging [7]. Associated mucoid swelling and hyalinization of the interelastic fibrous connective tissue may contribute to a relatively radiolucent appearance of the involved, noncalcified LF. In addition, LF thickening is also believed to be caused by a buckling of the ligaments secondary to degenerative facet-joint changes and spondylosis. The term *hypertrophy* is not favored in describing thickened LF as it

implies an increase in the size of the cellular elements composing a particular structure, and this is not the case with the thickened LF.

Back pain and sciatica from "hypertrophy" of the LF was first claimed by Elsberg [8] in 1913. Thoracic myelopathy induced by ossification of the LF was reported by Yamaguchi et al. [9] in 1960. Since then isolated reports of both cervical [10] and thoracic [2, 3] myelopathy have appeared in the literature.

Our series of patients is different from others in that the possible multiple levels of LF involvement are emphasized, as well as the association with other degenerative changes that may further compromise the spinal canal.

All our patients had CT-myelogram evidence of a secondary high-grade block and/or marked stenosis from LF thickening with and without ossification. LF thickening as an isolated finding—one not producing spinal stenosis or associated with other causes of spinal stenosis (such as disk bulge and facet hypertrophy)—most likely is without clinical significance.

In two of our patients, thickened or buckled LF with ossification was the only actual anatomic cause of their symptoms: bilateral, progressive leg weakness in one (Fig. 1) and spastic paraplegia in the other (Fig. 2). Another patient had distal thoracic cord compression, mainly because of thickened LF, in addition to a 3-mm laterally extruded disk found at surgery but not seen at myelography. Thickening of the LF in our cases was always associated with facet-joint degeneration, although productive facet-joint changes need not have been contributory to spinal stenosis and consequent cord and nerve-root compression (Fig. 3). In case 1 a block was found at T11–T12 on the initial myelographic study. The patient initially improved after bilateral laminectomy with resection of an ossified LF at T11–T12 but returned in 6 months with recurrent symptoms. At that time CT myelography demonstrated an additional ossified LF with block at the T10–T11 level that was neither sought nor appreciated on the initial study. In light of this we believe that patients with a complete

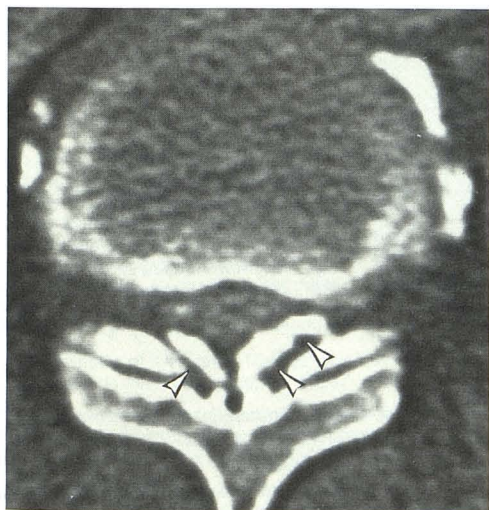
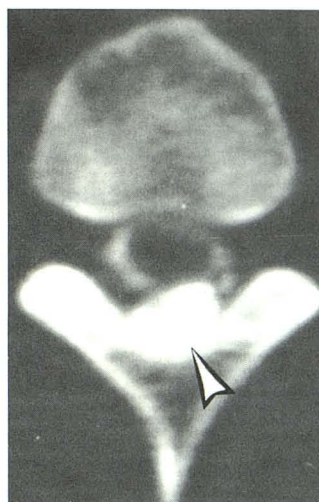
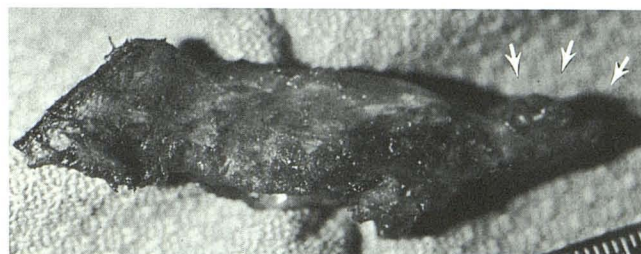
Fig. 1.—Case 1. Postmetrizamide-myelogram CT scan at T11–T12 level shows enlargement and ossification of ligamentum flavum (arrowheads) with compression of dural tube.



A



B

Fig. 2.—Case 2.

A, Postmyelogram CT scan just inferior to complete block at T2–T3 shows enlarged, ossified ligamentum flavum near midline (arrowhead).

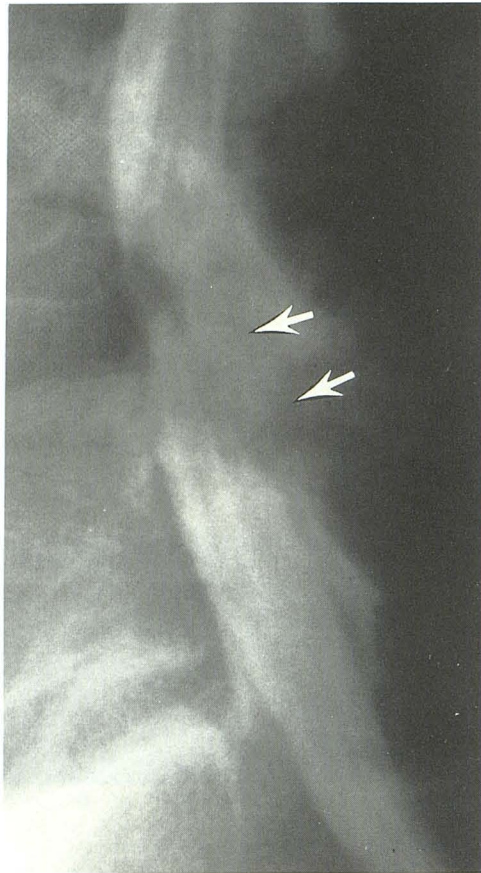
B, Surgical specimen shows spinous process with contiguous midline ligamentum flavum ossification (arrows).

block should also be studied from above with a C1–C2 cervical puncture to rule out other associated clinically significant levels. In one patient in whom MR scanning was performed the ossified ligaments were missed owing to the null signal of calcification. Even with CT myelography an extended window should be used to distinguish intrathecal contrast material from an ossified ligament (Fig. 4). In those cases (three of seven in our series) in which a herniated disk is present at the same level, surgical intervention must also include total removal of the offending ligament to relieve the clinical symptoms.

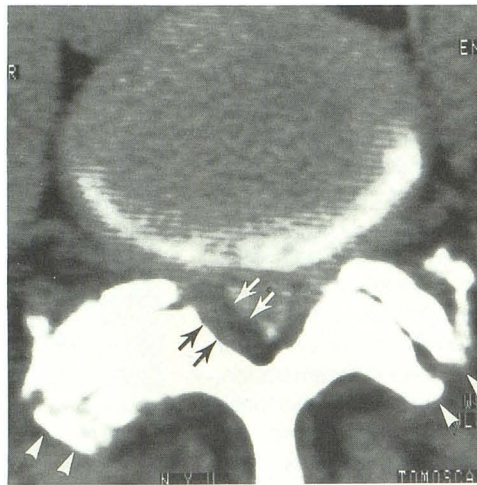
In conclusion, LF thickening with and without ossification is often found in conjunction with both degenerative disease and stenosis at the same and other levels, and should not be ignored as a possible contributing factor to a patient's symptoms. Patients with an extradural block to contrast agents should be studied from above to exclude any additional levels of clinically significant disease. Even in patients with associated disk herniation, surgical intervention must involve total removal of an offending ligament, in addition to the disk itself, to relieve the clinical symptoms. Finally, because of the null signal of calcification on MR and the lack of good transaxial views with most MR scanners, we believe the current imaging method of choice should be CT myelography.

REFERENCES

1. Miyasaka K, Kiyoshi K, Ito T, Takei H, Sugimoto S, Tsuru M. Ossification of spinal ligaments causing thoracic radiculomyelopathy. *Radiology* 1982;143:463–468
2. Omojola MF, Cardoso ER, Fox AJ, Drake CG, Durward QJ. Thoracic



A

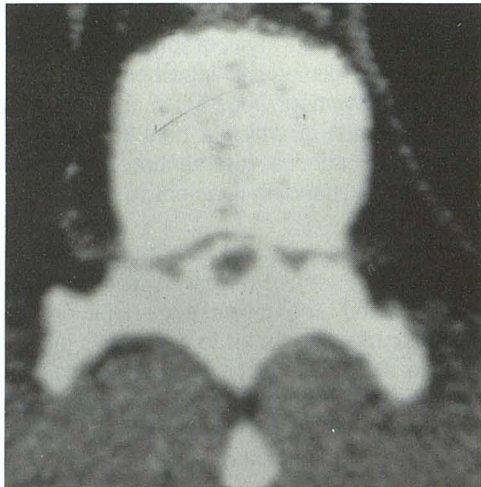


B

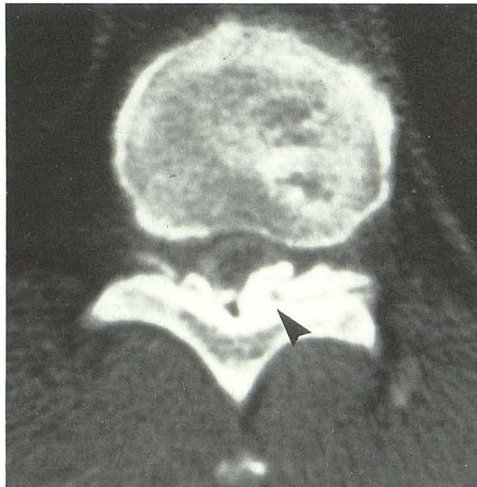
Fig. 3.—Case 5.

A, Lateral film of myelogram shows posterior impression on dural tube at L4-L5 level (arrows).

B, Axial postmyelogram CT scan through L4-L5 disk space shows marked enlargement of right half of ligamentum flavum (arrows). Associated mucoid swelling and hyalinization of ligamentum flavum may account for its relative radiolucent appearance. Productive bony change off facet joints are directed mainly posteriorly (arrowheads) rather than medially into spinal canal.



A



B

Fig. 4.—Case 3. Axial CT scans on two different occasions at approximately the same level with intermediate (A) and extended (B) windows show the importance of wide window settings in differentiating ossified ligament (arrowhead) from intrathecal metrizamide.

myelopathy secondary to ossified ligamentum flavum. *J Neurosurg* 1982;56:448-450

3. Chintapalli K. Progressive myelopathy in a 32 year old man. *JAMA* 1985;253:2255-2257
4. Ramsey RH. The anatomy of the ligamentum flavum. *Clin Orthop* 1966;44:129-140
5. Braus H. *Anatomie des Menschen*, Vol 1, Auflage 3. Berlin: Springer-Verlag, 1954
6. Herzog W. Morphologie und Pathologie des Ligamentum Flavum. *Frankfurter Z Pathol* 1950;61:250-267

7. Dockerty MD, Love JG. Thickening and fibrosis (so called hypertrophy) of the ligamentum flavum. *Mayo Clin Proc* 1940;15:161
8. Elsberg CA. Experiences in spinal surgery. *Surg Gynecol Obstet* 1913;16:117
9. Yamaguchi M, Tamagake S, Fujita S. A case of the ossification of the ligamentum flavum with spinal cord tumor symptoms (in Japanese). *Seikeigeka (Orthop Surg)* 1960;11:951-956
10. Kubota M, Baba I, Sumida T. Myelopathy due to ossification of the ligamentum flavum of the cervical spine: a report of two cases. *Spine* 1981;6(6):553-559