



## Get Clarity On Generics

Cost-Effective CT & MRI Contrast Agents

 FRESENIUS  
KABI

WATCH VIDEO

# AJNR

**Vacuum phenomenon as a sign of an ununited, unstable dens fracture.**

A L Williams, G F Carrera, J P Grogan and D P Ullrich

*AJNR Am J Neuroradiol* 1987, 8 (6) 1144-1145

<http://www.ajnr.org/content/8/6/1144.citation>

This information is current as  
of August 17, 2025.



## Vacuum Phenomenon as a Sign of an Ununited, Unstable Dens Fracture

Alan L. Williams,<sup>1</sup> Guillermo F. Carrera,<sup>1</sup> John P. Grogan,<sup>1</sup> and Donald P. Ullrich<sup>2</sup>

Gas within a degenerated intervertebral disk (vacuum phenomenon) or within a synovial joint subjected to traction is a common radiographic finding [1–6]. Gas produced by bacterial action has been described as a sign of osteomyelitis or soft-tissue infection [7]. Intraosseous gas as a physical phenomenon has also been identified in patients with ischemia or malignancy [8–10]. The purpose of this report is to describe gas within an ununited dens fracture and to suggest that this "vacuum phenomenon" represents radiographic evidence of instability.

### Case Report

A 45-year-old man presented with neck pain after a minor accident in which his automobile was struck from the rear by another car. Aside from mild cervical muscle spasm, physical examination was normal. Cervical spine radiographs suggested an oblique fracture through the inferior dens. When questioned, the patient recalled being in a severe automobile accident 25 years earlier in which he sustained a cervical spine injury that was treated with body-jacket immobilization. A CT scan of the craniocervical junction confirmed an oblique dens fracture with sclerotic margins and gas within the fracture defect (Fig. 1). Lateral cervical radiographs in flexion demonstrated 3-mm anterior displacement of the dens upon the body of C2. Because the patient was symptomatic and had radiographic evidence of an unstable, ununited fracture, a C1–C2 stabilization procedure (wiring of the posterior arch of C1 and vertebral arch of C2) was performed. On a postoperative CT scan gas was no longer present at the fracture site (Fig. 2). Flexion and extension radiographs demonstrated no movement of the dens upon the body of C2. Two months after surgery the patient was asymptomatic.

### Discussion

Gas is frequently seen radiographically in degenerated intervertebral disks (vacuum phenomenon) [1], in normal joints under stress [1–4], and in degenerated facet joints [11]. This intradisk or intraarticular gas is composed primarily of nitrogen (90–92%) as well as oxygen, carbon dioxide, and other trace gases [1]. It has been suggested that when opposing joint surfaces are distracted, the intraarticular pressure is reduced,

causing dissolved gases in the surrounding extracellular or synovial fluid to leave solution and enter the joint space [1, 3, 4]. Although gas has also been described in necrotic femoral heads [5], collapsed vertebral bodies [9, 10], and acute traumatic avulsion of a cervical disk from adjacent endplate [12], a literature search failed to yield a description of gas associated with an ununited spinal or long-bone fracture. Vacuum phenomena have been described in association with pseudoarthroses in a failed lumbar fusion [13].

A clinically stable fracture may exist in the absence of radiographic evidence of bony union [14]. Thus, the radiographic demonstration of a nonacute fracture line does not necessarily indicate instability. However, gas in a fracture line suggests distraction forces similar to those recognized with a "vacuum joint," and thus instability. The detection of intraosseous gas by CT has been described as a sign of osteomyelitis [7]. In most cases osteomyelitis is accompanied by fever, bone destruction, and adjacent soft-tissue mass. Penetrating injury and iatrogenic introduction as well as infection should be considered when gas within an osseous or soft-tissue structure is identified radiographically.

In summary, this case describes a "vacuum phenomenon" associated with a chronic, ununited, unstable dens fracture. When gas is observed radiographically in association with a nonacute fracture, additional evaluation including dynamic studies may be indicated. Patients with an unstable dens fracture are at risk for severe neurologic injury and must be managed cautiously.

### REFERENCES

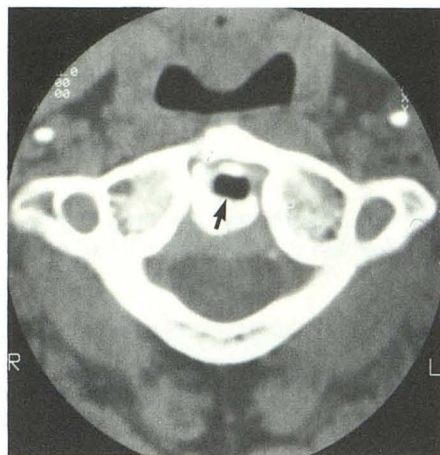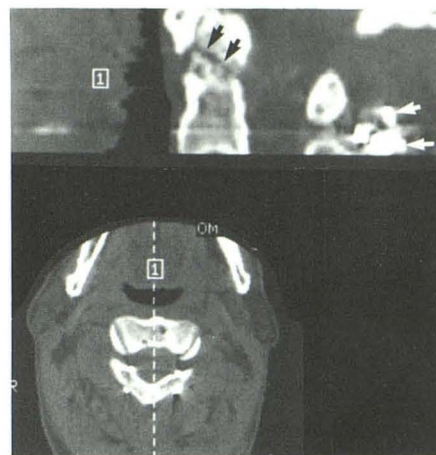
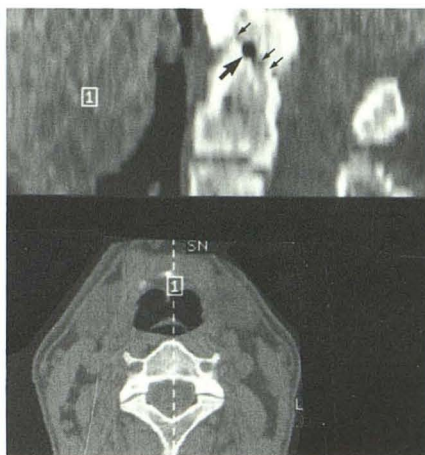
1. Ford LT, Gilula LA, Murphy WA, Gado M. Analysis of gas in vacuum lumbar disc. *AJR* 1977;128:1056–1057
2. Rubin EL. The delineation of articular cartilage by x-rays without the aid of contrast media. *Br J Radiol* 1939;12:649–657
3. Evans WA. The roentgenological demonstration of the true articular space with particular reference to the knee joint and the internal semilunar cartilage. *AJR* 1940;43:860–864
4. Fuiks DM, Grayson CE. Vacuum pneumarthrography and the spontaneous occurrence of gas in the joint spaces. *J Bone Joint Surg* 1950;32:933–938

Received September 23, 1985; accepted after revision December 10, 1985.

<sup>1</sup> Department of Radiology, Medical College of Wisconsin, Froedtert Memorial Lutheran Hospital, 9200 West Wisconsin Ave., Milwaukee, WI 53226. Address reprint requests to A. L. Williams.

<sup>2</sup> Neurosurgical Specialists, S.C., Milwaukee, WI 53210.



**A****B**

**Fig. 1.**—A, Axial 1.5-mm-thick CT section through atlas demonstrates gas collection (arrow) associated with dens.

**B,** Sagittal reformatted image shows oblique fracture (small arrows) through dens and gas (large arrow) within fracture line.

**Fig. 2.**—Reformatted sagittal CT image from scan obtained 2 months after operative stabilization shows persistent fracture line (black arrows) through lower dens. However, no gas is identified within fracture line. Note stabilizing wires posteriorly (white arrows).

- Martel W, Poznanski AK. The effect of traction on the hip in osteonecrosis. A comment on the "radiolucent crescent line." *Radiology* 1970;94:505-508
- Vegter J, Van Den Broek JAC. The diagnostic value of traction during radiography of diseases of the hip. *J Bone Joint Surg* 1983;65(B):428-432
- Ram PC, Martinez S, Korobkin M, Breiman RS, Gallis HR, Harrelson JM. CT detection of intraosseous gas: a new sign of osteomyelitis. *AJR* 1981;137:721-723
- Jacobs P. Intra-epiphyseal gas in osteochondritis. *Clin Radiol* 1970;21:318-319
- Maldague BE, Noel HM, Malghem JJ. The intravertebral vacuum cleft: a sign of ischemic vertebral collapse. *Radiology* 1978;129:23-29
- Schabel SI, Moore TE, Rittenberg GM, Stanley JH, Javid LH. Vertebral vacuum phenomenon: a radiographic manifestation of metastatic malignancy. *Skeletal Radiol* 1979;4:154-156
- Carrera GF, Haughton VM, Syvertsen A, Williams AL. Computed tomography of the lumbar facet joints. *Radiology* 1980;134:145-148
- Reymond RD, Wheeler PS, Perovic M, Block B. The lucent cleft, a new radiographic sign of cervical injury or disease. *Clin Radiol* 1972; 23:188-192
- Mall JC, Kaiser JA, Heithoff KB. Postoperative spine. In: Newton TH, Potts DG, eds. *Modern neuroradiology, vol. 1, Computed tomography of the spine and spinal cord*. San Anselmo, CA: Clavadel Press, 1983:198
- Rogers LF. *Radiology of skeletal trauma*. New York: Churchill Livingstone, 1982:117-125