



## Get Clarity On Generics

Cost-Effective CT & MRI Contrast Agents

 FRESENIUS  
KABI

WATCH VIDEO

# AJNR

## CT of acquired hyperopia with choroidal folds.

G K Stimac, R P Mills, R A Dailey, W T Shults and R E Kalina

*AJNR Am J Neuroradiol* 1987, 8 (6) 1107-1111

<http://www.ajnr.org/content/8/6/1107>

This information is current as  
of August 21, 2025.

# CT of Acquired Hyperopia with Choroidal Folds

Gary K. Stimac<sup>1</sup>  
 Richard P. Mills<sup>2</sup>  
 Roger A. Dailey<sup>3</sup>  
 W. Thomas Shults<sup>4</sup>  
 Robert E. Kalina<sup>2</sup>

Seven patients with an ophthalmologic diagnosis of acquired hyperopia with choroidal folds were evaluated by high-resolution axial CT of the orbits. Coronal, oblique coronal, and parasagittal reformations were obtained and the thickness of the optic nerve and morphologic appearance of the globes were assessed by measurement and subjective appearance. Flattening of the globe, which caused the globe to assume an ellipsoid shape, was seen in all 11 affected eyes. Mild to moderate optic nerve enlargement was also demonstrated in most patients. In six of 11 affected eyes a visible space was noted between the optic nerve and its sheath, implying expansion of the subarachnoid perineural compartment. These findings were not demonstrated in a control group of five patients scanned in a similar manner. Scans of a phantom revealed no evidence of CT-generated distortion.

These findings may help to identify hyperopia with choroidal folds as a benign disease and eventually help to establish its cause.

Acquired hyperopia with choroidal folds is a benign condition characterized clinically by the acute development of a unilateral or bilateral hyperopic shift in refractive error, causing some patients to experience blurred vision. Only 13 cases of this rare disease, which affects primarily middle-aged men, have been reported [1, 2].

Visual acuity is improved to normal or near normal by plus lenses, and both the refractive error and ophthalmoscopic findings tend to remain stable over time. The ophthalmoscopic examination shows choroidal folds in the fundus (Fig. 1A). These are best demonstrated by fluorescein angiography (Fig. 1B). Sonographic measurements reveal a flattening of the globe in the anteroposterior diameter. Choroidal folds have been described extensively in the ophthalmology literature [3-14], including two reports that discussed the association of choroidal folds with acquired hyperopia [1, 2]. Recently, follow-up studies have indicated the benign course of this disease [2].

The availability of high-resolution CT scanners has greatly improved the ability to evaluate the orbit by providing thin slices, artifact reduction algorithms, and software that improves radiographic contrast of the markedly varying densities of orbital structures. Such factors enable the identification of previously undetected abnormalities in acquired hyperopia with choroidal folds.

We evaluated seven patients with acquired hyperopia with choroidal folds by high-resolution orbit CT to assess the changes in shape of the globe and to attempt to determine the cause of this disease.

## Subjects and Methods

Seven patients were diagnosed as having acquired hyperopia with choroidal folds on the basis of clinical history, ophthalmoscopy, and refraction. The patients were followed for an average of 4.5 years (range, 0-7 years), and the details of the clinical ophthalmoscopic findings were reported elsewhere [2]. Some of these patients had CT scans previously, but

Received March 31, 1986; accepted after revision April 20, 1987.

Presented at the annual meeting of the American Society of Neuroradiology, San Diego, January 1986.

<sup>1</sup> Department of Radiology, SB-05, University of Washington, Seattle, WA 98195, and First Hill Diagnostic Imaging Center, 1001 Boylston Ave., Seattle, WA 98104. Address reprint requests to G. K. Stimac at First Hill Diagnostic Imaging Center.

<sup>2</sup> Department of Ophthalmology, RJ-10, University of Washington, Seattle, WA 98195.

<sup>3</sup> Department of Ophthalmology, Oregon Health Sciences University, Portland, OR 97210.

<sup>4</sup> Good Samaritan Hospital, Neurological Sciences Center, Portland, OR 97210.

**AJNR 8:1107-1111, November/December 1987**  
 0195-6108/87/0806-1107

© American Society of Neuroradiology



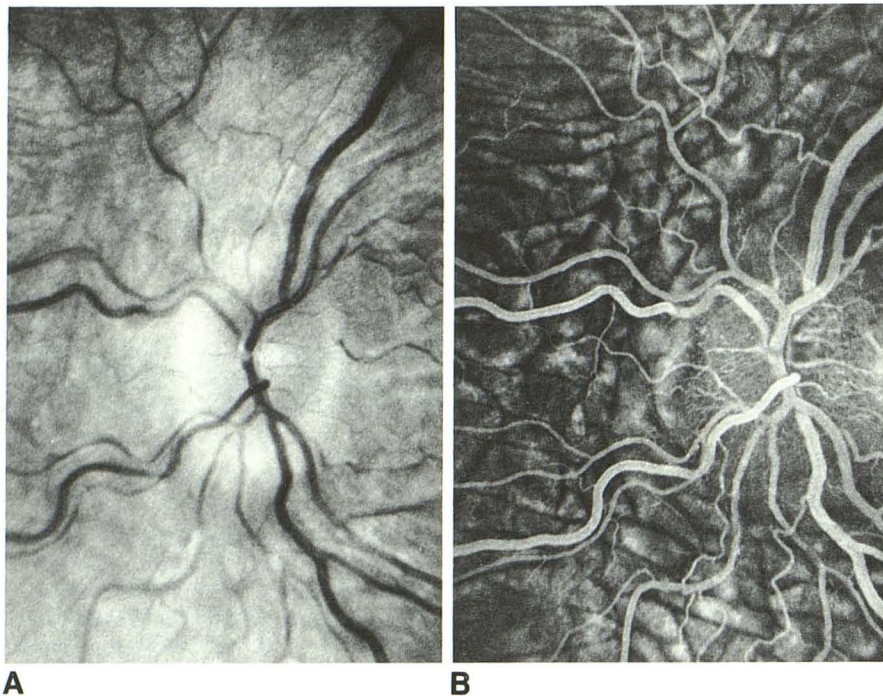


Fig. 1.—Case 3. Choroidal folds in newly acquired hyperopia in right eye only.

A, Fundoscopic view. Folds are alternating dark and light bands radiating from optic disk.  
B, Fluorescein angiography best shows choroidal folds as alternating dark and light lines.

thin-slice technique was not available and no abnormalities were demonstrated. Five control patients were also evaluated. These control patients were scanned to evaluate trauma (two patients), possible tumor (one patient), photophobia (one patient), and orbital pseudotumor (one patient).

Patients, controls, and a specially constructed phantom were scanned using 1.5-mm contiguous axial slices without IV contrast material on a GE 9800 CT scanner (five patients) or with contrast on a GE 8800 (two patients) CT scanner. Coronal reformations were obtained at the level of the globe and at midcone. Parasagittal reformations were obtained along the axes of the optic nerves, and oblique coronal reformations were obtained perpendicular to each optic nerve at its midpoint. For the majority of patients, the head was tilted back about 10° beyond the inferior orbitalmeatal line to place the petrous ridges below the level of the scan and to present the entire optic nerve within the axial plane. To maximally stretch the optic nerve [15], half the patients were instructed to look superiorly about 30°.

Subjective impressions of flattening of the globe, thickening of the optic nerve image, visualization of the subarachnoid space along the optic nerve, and scleral thickening were made by two observers. Scans of a constructed phantom globe and nerve were also obtained in the same manner to ensure that no artifactual changes in size or shape were created by the different reformations used.

Scoring of the subjective findings were as follows: flattening of the pole of the globe was graded as 0 (normal), 1 (flattened but convex), 2 (flat), 3 (concave indentation of the globe). Widening of the nerve head at the globe was graded as 0 (uniform nerve, no widening), 1 (fusiform dilatation), 2 (clubbed). Visualization of low density in the perineural space was graded as 0 (low density, not seen), 1 (possibly seen), 2 (definite visualization of perineural low density as contrasted to the nerve). Uveoscleral thickening was graded as 0 (not seen), 1 (possibly seen), 2 (definite thickening).

## Results

Our CT observations are summarized in Table 1. We found flattening of the posterior globe, mild to moderate optic nerve enlargement, and, in six of 11 affected eyes, a discernible space between the sheath and nerve, suggesting fluid accumulation in the subarachnoid space. Such abnormalities were not seen in five control patients and an orbit phantom.

In the seven patients with a diagnosis of hyperopia with choroidal folds, flattening of the posterior globe was detected in all 11 affected eyes. In five of the affected eyes, the posterior globe was convex but of flatter curvature than the normal globe (Fig. 2). In six of the affected eyes, the posterior aspect of the globe was either flat or indented (Fig. 3) in the region of the optic nerve insertion. Both axial and sagittal views were effective in demonstrating these findings. In the control patients, a suggestion of slight flattening was seen in only one of nine eyes examined. Scans of the phantom showed no evidence of flattening or distortion in any projection.

Widening of the nerve head at its insertion to the globe was identified as clubbed in two of the affected eyes (Fig. 4) and as fusiform dilatation in the remaining nine. None of the control eyes suggested a finding of nerve dilatation. The axial views were slightly better than the sagittal reconstructions in identifying this finding.

A visible subarachnoid space along the optic nerve was definitely seen in two of the affected eyes (Fig. 5) and was possibly seen in an additional four. Such a visualization of subarachnoid space was not identified in any of the control



TABLE 1: CT Findings in Patients with Acquired Hyperopia

Case No.	Eye	Flat Pole		Wide Nerve Head		Enlarged Subarachnoid Space		Comment
		Axial	Sagittal	Axial	Sagittal	Axial	Sagittal	
1	R	0	0	0	0	0	0	Unaffected
	L	1	1	2	1	0	0	Affected
2	R	2	2	0	1	0	1	Affected
	L	2	2	2	2	1	1	Affected
3	R	2	2	1	1	0	0	Affected
	L	1	1	2	1	0	0	Unaffected
4	R	0	0	1	0	0	0	Previously affected
	L	0	1	1	0	0	0	Affected
5	R	3	3	1	0	1	0	Affected
	L	3	3	1	1	2	1	Affected
6	R	1	1	1	0	0	0	Newly affected
	L	0	1	1	0	0	0	Affected
7	R	2	1.5	1	1	2	1	Affected
	L	1	1	1	1	1	0	Clinically unaffected

Note.—Flat pole of globe scoring: 0 = normal; 1 = flattened but convex; 2 = flat; 3 = concave indentation of globe. Widening of nerve head at globe: 0 = uniform (no widening), 1 = fusiform dilatation, 2 = clubbed. Enlarged subarachnoid space: 0 = low density is not seen, 1 = possibly seen, 2 = definitive visualization of perineural low density as contrasted to the nerve. R = right; L = left.

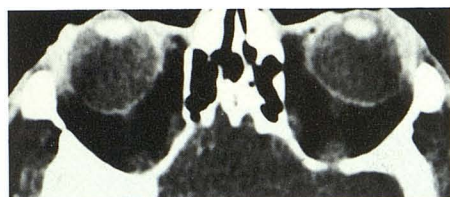

Fig. 2.—Case 1. Convex but abnormal posterior aspect of globe. Axial view of orbit in 60-year-old man who noted decreasing myopia in left eye requiring  $+1.25 +1.75 \times 90$  correction. Choroidal folds were in left eye only. Myopic right globe is round; left globe shows flattened convex curvature (grade 1).

eyes and no artifact was seen on the phantom optic nerve views to suggest the presence of a border. Axial views were slightly better than parasagittal views in identifying this enlarged subarachnoid space. Scans that placed the optic nerve exactly in the axial plane allowed more reliable interpretation of the findings.

B-mode echography was done in six of the seven patients and showed flattening of the posterior poles. A-mode echography provided axial length data in four of the seven cases. However, the  $30^\circ$  test used for detection of perineural fluid was done in only one case, and the results were equivocal.

Uveoscleral thickening was not present in any of the patients with hyperopia and choroidal folds. One control patient, with orbital pseudotumor, was identified by uveoscleral thickening on the CT scan, typical clinical symptoms of orbital pain, and response to steroid therapy. Choroidal folds were seen on ophthalmoscopy but there was no evidence of acquired hyperopia. The high-resolution scan demonstrated no

flattening of the globe and no enlargement of the subarachnoid space of the optic nerve.

## Discussion

Acquired hyperopia with choroidal folds is a benign disease that results in relatively sudden onset of significant hyperopic change in refractive error. Choroidal folds are demonstrated on ophthalmoscopic examination.

Once established, the disease does not appear to progress. In one patient the previously uninvolved eye developed hyperopia and choroidal folds at a later time. In two myopic patients, the hyperopic shift restored uncorrected vision to near normal. The cause of this disease is not known. The CT identification of flattening of the globe and possible enlargement of the subarachnoid sheath near the optic nerve head and along the nerve raises the possibility that the cause of the disease is at least initially an edematous process [16, 17]. The flattening of the globe identified in some patients was dramatic and exceeded the change expected to cause the refractive error.

The diagnostic possibilities when an abnormal shape of the globe is identified have been reported [18]. Acquired hyperopia with choroidal folds should be added to this differential list. The differential diagnoses of flattening of the posterior globe also include orbital neoplasm profound hypotony, and posterior scleritis. In hypotony (decreased intraocular pressure), the contraction of the extraocular muscles deforms the globe into a square shape. In posterior scleritis, the sclera is thickened.

The finding of CT visualization of a lucent zone between optic nerve sheath and nerve suggests an increased collection of subarachnoid fluid in the perineural space. Confirmatory






Fig. 3.—Case 5. Flat or indented posterior aspect of globe. Axial (A) and sagittal (B, right eye; C, left eye) CT views of orbit in 26-year-old man with blurred vision, hyperopia, and bilateral choroidal folds. Flattening and indentation (grade 3) of posterior poles of globes and decreased antero-

posterior diameter bilaterally. Optic nerves widen at entrance to globe. Low density peripherally along margin of left optic nerve, best seen on axial view (arrows), suggests presence of fluid in perineural space (grade 2). Reprinted with permission from *Ophthalmology* [2].

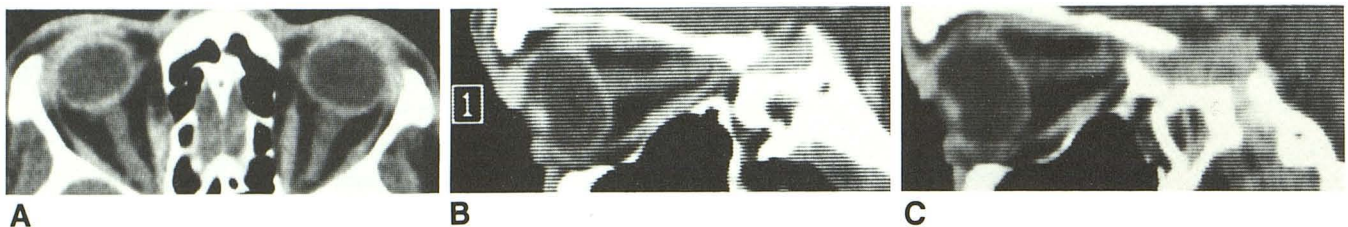

Fig. 4.—Case 2. Widening of nerve head at insertion. Axial (A) and sagittal (B, right eye; C, left eye) CT views of orbit in 47-year-old man with hyperopia and bilateral choroidal folds. Both globes show decreased

anteroposterior diameter and posterior flattening (grade 2). Left optic nerve is clubbed at insertion to globe (grade 2). Figures 4B and 4C reprinted with permission from *Ophthalmology* [2].

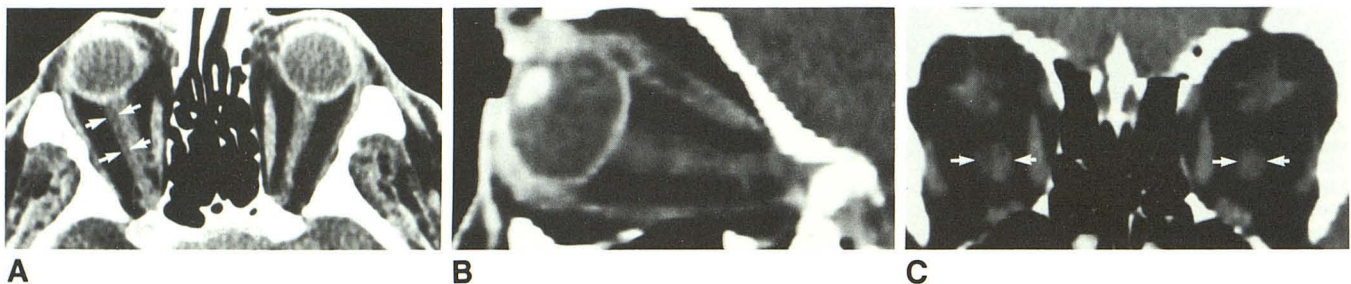


Fig. 5.—Case 7. Visible subarachnoid space. 52-year-old man with severe hyperopia in right eye with choroidal folds; mild hyperopia and no choroidal folds in left eye.

A, Axial view, and B, right sagittal view show decreased anteroposterior diameter of right globe (grade 2) and enlarged optic nerve sheath. Low density in perineural space (arrows) appears to represent fluid (grade 2).

C, Coronal view shows enlargement of right optic nerve sheath. Figures 5A and 5B reprinted with permission from *Ophthalmology* [2].

ultrasonic data were unfortunately not available on most of our patients. A 30° test using quantitative A-scan echography was equivocal (differentiation of sheath and nerve echoes was not clear) in the one patient on whom it was performed. In cases of suspected sheath enlargement due to fluid accumulation, such testing may show decreased width of the perineural subarachnoid space when the sheath is stretched during abduction of the eye. Proof of perineural subarachnoid fluid accumulation through surgical exploration was not elected because of the benign nature of the condition.

Although our observations of globe size and configuration were generally in agreement with ophthalmoscopic, sonographic, and clinical findings, they often required some inter-

pretation as to whether the corneal vault (the "cap" that protrudes from the otherwise spherical globe) was included in the scan, whether the patient had inherent facial asymmetry, and whether reformations obtained were in the optimal plane. The subjective appearance allowed a better compensation for such factors and the abnormal findings were more easily identified (Table 1) than with direct measurement. Scans of the phantom showed no artifactual changes in the shape of the nerves or globes, and demonstrated the accuracy of the measurement processes.

Hyperopia with choroidal folds is a benign disease of unknown origin. Our investigations have shown flattening of the posterior globe, enlargement of the optic nerve head, and a

discernible subarachnoid space around the optic nerve. These findings may help identify this disease as benign, and may eventually help to establish its cause.

#### ACKNOWLEDGMENT

We thank Debborah Burch for coordinating the scanning and assisting with measurements and analysis.

#### REFERENCES

1. Kalina RE, Mills RP. Acquired hyperopia with choroidal folds. *Ophthalmology* **1980**;87:44-50
2. Dailey RA, Mills RP, Stimac GK, Shults WT, Kalina RE. The natural history and CT appearance of acquired hyperopia with choroidal folds. *Ophthalmology* **1986**;93:1336-1342
3. Hyvarinen L, Walsh FB. Benign choroidal folds. *Am J Ophthalmol* **1970**;70:14-17
4. Kroll AJ, Norton EDW. Regression of choroidal folds. *Trans Am Acad Ophthalmol Otolaryngol* **1970**;74:515-525
5. Bird AC, Sanders MD. Choroidal folds in association with papilloedema. *Br J Ophthalmol* **1973**;57:89-97
6. Newell FW. Choroidal folds. *Am J Ophthalmol* **1973**;75:930-942
7. Cappaert WE, Purnell EW, Frank KE. Use of B-sector scan ultrasound in the diagnosis of benign choroidal folds. *Am J Ophthalmol* **1977**;87:375-379
8. Cangemi FE, Trempe DL, Walsh JB. Choroidal folds. *Am J Ophthalmol* **1978**;86:380-387
9. Wolter JR. Parallel horizontal choroidal folds secondary to an orbital tumor. *Am J Ophthalmol* **1974**;77:669-673
10. Bullock JD, Egbert PR. Experimental choroidal folds. *Am J Ophthalmol* **1974**;78:618-623
11. Fribert TR, Grove AS. Choroidal folds and refractive errors associated with orbital tumors. *Arch Ophthalmol* **1983**;101:598-603
12. Newell FW. Fundus changes in persistent and recurrent choroidal folds. *Br J Ophthalmol* **1984**;68:32-35
13. Ossoinig KC, Cennamo G, Frazier-Byrne S. Echographic differential diagnosis of optic nerve lesions. *Doc Ophthalmol Proc Series* **1981**;29:327-332
14. Norton EWD. A characteristic fluorescein angiographic pattern in choroidal folds. *Proc R Soc Med* **1969**;62:119-128
15. Unsold R, Newton TH, Hoyt WF. CT examination technique of the optic nerve. *J Comput Assist Tomogr* **1980**;4:560-563
16. Hupp SL, Buckley EG, Byrne SF, et al. Post-traumatic venous obstructive retinopathy associated with enlarged optic nerve sheath. *Arch Ophthalmol* **1984**;102:254-256
17. Rothfus WE, Curtin HD, Slamovitis TL, Kennerdell JS. Optic nerve/sheath enlargement. *Radiology* **1984**;150:409-415
18. Osborne DR, Foulks GN. Computed tomographic analysis of deformity and dimensional changes in the eyeball. *Radiology* **1984**;153:669-674