



Get Clarity On Generics

Cost-Effective CT & MRI Contrast Agents



FRESENIUS
KABI

WATCH VIDEO

AJNR

Modified scalp vein needle for arterial puncture in infants.

J W Yeakley, K F Lee and L L Patchell

AJNR Am J Neuroradiol 1986, 7 (3) 517-518

<http://www.ajnr.org/content/7/3/517.citation>

This information is current as
of August 11, 2025.

Modified Scalp Vein Needle for Arterial Puncture in Infants

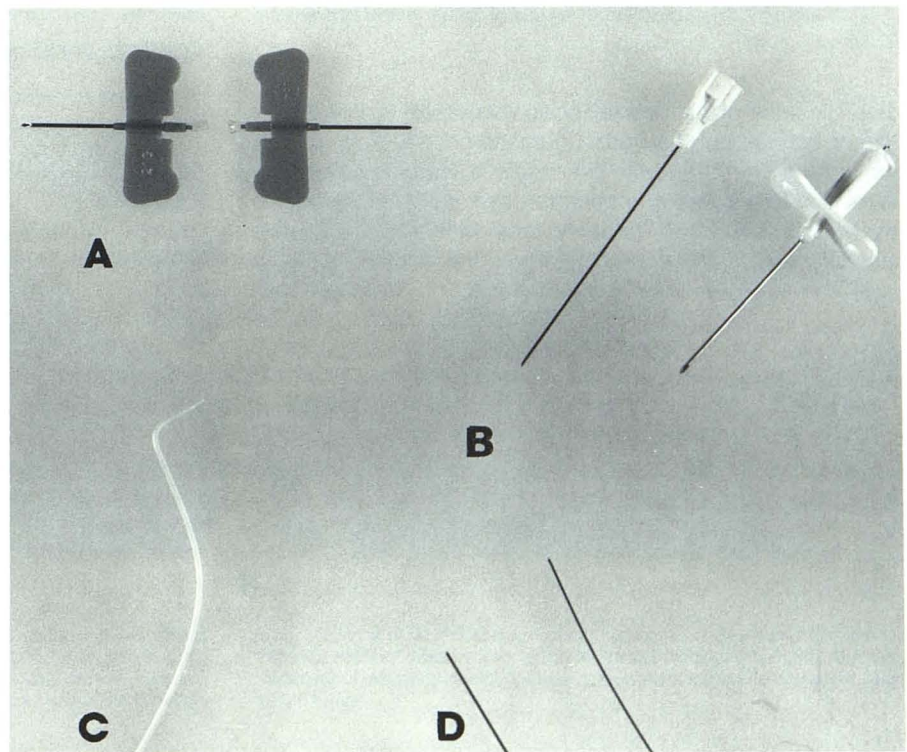
Joel W. Yeakley,¹ K. Francis Lee, and Larry L. Patchell

Occasionally the need arises for selective femorocerebral catheter studies in infants, and the 21-gauge (G) Cournand needles required for this procedure are not always readily available. Instead, the 20-G 1.5-in. Potts-Cournand arterial needle (Fig. 1B) that is provided with the commercially available B-D White pediatric percutaneous catheterization set is used. We have found the White pediatric arterial needle both difficult to manipulate and large in comparison to the tiny infant patient. In addition, the double-wall puncture technique commonly used with this needle may predispose the artery to spasm with failure of passage of the guidewire or subintimal passage of the guidewire. Therefore, multiple puncture attempts are often required.

As an alternative method, we have modified a 21-G scalp vein needle (Figs. 1A and 2) for arterial puncture. These needles are usually available in most hospitals and can be easily modified for arteriography.

The plastic tube of a 21-G scalp vein needle is severed with a scalpel a few millimeters behind the metallic portion of the needle. The severed portion is then flared with a hot plate in the same manner in which a flare is produced in catheter material before hub attachment. This permits easy insertion of guidewire even in the presence of arterial backflow through the needle. A 0.021-in. guidewire must be used with this technique because the 0.025-in. wire permissible with the White needle will not pass through the scalp vein needle (Fig.

Fig. 1.—Equipment used for arterial puncture. **A**, 21-G scalp vein needle without and with flaring of hub. **B**, Potts-Cournand 20-G 1.5 in. needle and stylet. **C**, 3.6-French Fierstien catheter with simple primary curve and secondary "aortic" curve. **D**, 0.025-in. and 0.021-in. guidewires.



Received February 22, 1985; accepted after revision October 4, 1985

¹ All authors: Department of Radiology, The University of Texas Health Science Center at Houston, 6431 Fannin, 2130 MSB, Houston, TX 77030. Address reprint requests to J. W. Yeakley.

AJNR 7:517-518, May/June 1986 0195-6108/86/0703-0517 © American Society of Neuroradiology

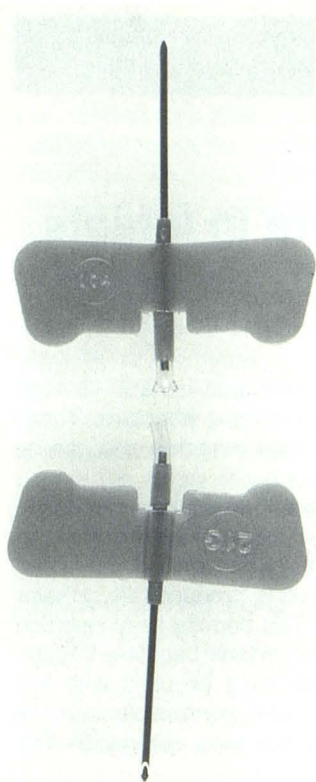


Fig. 2.—Closeup view of 21-g scalp vein needle before and after flaring of hub.

1D). The bevel of the modified scalp vein needle is only slightly longer than that of the Potts-Cournand needle. A single-wall puncture is performed with the needle in a very flat trajectory in relation to the skin. The operator then stabilizes the needle by holding the plastic butterfly tabs with one hand while inserting the guidewire with the other. We have found this to

be more effective than wire insertion by an assistant because it reduces the possibility of advancement of the needle or other motion that might dislodge it from the tiny artery. The needle may be used bevel up or bevel down according to the preference of the operator. The tip of a 3.6-French thin-walled catheter is drawn out to conform to the 0.021-in. guidewire. The catheter tip is bent with a primary curve of 1- to 1.5-cm length at approximately a right angle to the secondary aortic curve (Fig. 1C) as described by Fierstien [1]. This permits rapid catheterization of the cephalic vessels from the aortic arch.

The experience of the first author (JWY) with this technique has consisted of 14 cases over a period of 3 years, and no complications were encountered in these patients. KFL's experience has been more extensive (200 cases over a 15-year period), but these cases are not documented here because for most of them the technique was performed at another institution. None of the authors, however, has experienced an increased incidence of postprocedural complications, such as hematoma, when the scalp vein technique is compared with the use of Cournand needles. In addition, the number of needle puncture attempts necessary to achieve successful vessel catheterization has been reduced by the described technique.

The use of the modified scalp vein needle for arterial puncture is best suited for infants less than 1 year old, although it may be used in older children.

ACKNOWLEDGMENTS

We wish to express our appreciation and thanks to Ms. Margaret Young and Ms. Roz Vecchio.

REFERENCES

1. Fierstien SB. A simple catheter curve for cerebral angiography. *Radiology* 1978;126:524-525