



## Get Clarity On Generics

Cost-Effective CT & MRI Contrast Agents



FRESENIUS  
KABI

WATCH VIDEO

# AJNR

### Eye artifacts from mascara in MRI.

R M Wright, P A Swietek and M L Simmons

*AJNR Am J Neuroradiol* 1985, 6 (4) 652

<http://www.ajnr.org/content/6/4/652.citation>

This information is current as  
of August 11, 2025.

12. Cobb SR, Hieshima GB, Mehringer CM, Grinnell VS, Pribram HW. Persistent trigeminal artery variant: carotid-anterior inferior cerebellar artery anastomosis. *Surg Neurol* **1983**;19:263-266
13. Enomoto T, Sato A, Maki Y. Carotid-cavernous fistula caused by rupture of a primitive trigeminal artery aneurysm: case report. *J Neurosurg* **1977**;46:373-376

### Eye Artifacts from Mascara in MRI

During the early phases of operation of our magnetic resonance imaging (MRI) unit, distracting eye artifacts were often observed on the images (fig. 1A), and a subtle but definite soiling of the inner surface of the magnet was noted. The offending agent was suspected to be mascara, many brands of which contain iron oxides. A small

amount of mascara on a piece of tape placed on a phantom confirmed our suspicions (fig. 1B). Also, a plastic container of mascara was found to be attracted into the magnet. The mascara artifact is not significant with routine cerebral imaging but does degrade orbital detail.

We now ask all outpatients to remove their mascara before coming to the imaging center. In addition, we have mascara-removal materials available for those who are unable to make the trip without eye makeup.

Robert M. Wright  
Peggy A. Swietek  
Michael L. Simmons  
*Saint Francis Medical Center*  
Peoria, IL 61637

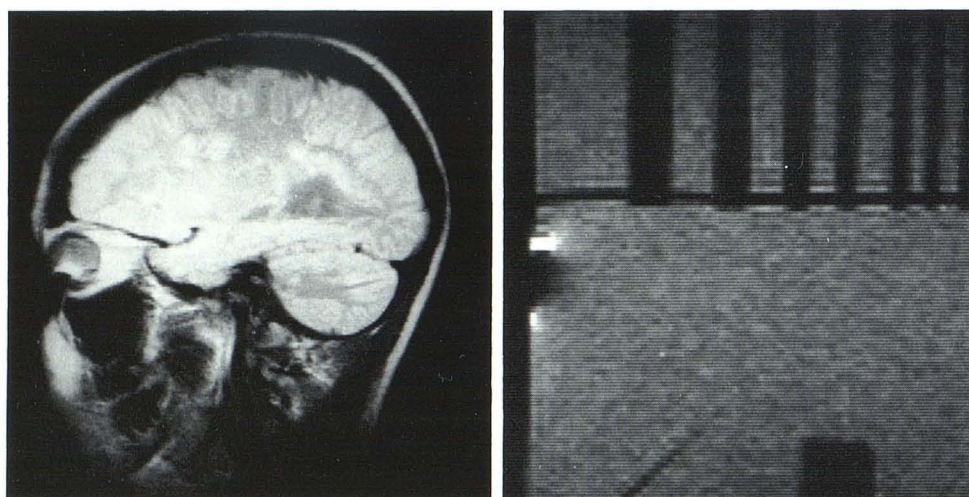
**A****B**

Fig. 1.—A, Artifact over anterior orbit on MRI for multiple sclerosis. B, Similar artifact on phantom after application of short length of tape coated with mascara.