



Get Clarity On Generics

Cost-Effective CT & MRI Contrast Agents



FRESENIUS
KABI

WATCH VIDEO

AJNR

Dynamic study of supratentorial gliomas with L-methyl-11C-methionine and positron emission tomography.

A Lilja, K Bergström, P Hartvig, B Spännare, C Halldin, H Lundqvist and B Långström

This information is current as of August 23, 2025.

AJNR Am J Neuroradiol 1985, 6 (4) 505-514
<http://www.ajnr.org/content/6/4/505>

Dynamic Study of Supratentorial Gliomas with L-methyl- ^{11}C -methionine and Positron Emission Tomography

Anders Lilja¹
Kjell Bergström¹
Per Hartvig²
Bo Spännare³
Christer Halldin⁴
Hans Lundqvist⁵
Bengt Långström⁴

The regional kinetics of intravenously injected L-methyl- ^{11}C -methionine (^{11}C -L-methionine) in the brain was investigated by positron emission tomography (PET) in 14 patients with gliomas. In both tumor and unaffected brain the tracer uptake reached a nearly constant level in 5 min or less. The ratio between the uptake of ^{11}C -L-methionine by high-grade tumors and the uptake by unaffected brain was 1.9–4.8. In two cases of low-grade astrocytoma the ratio was 0.8–1.0. High uptakes of ^{11}C -L-methionine occurred in gliomas even in the absence of blood-brain barrier defects as observed by other methods. This indicates that besides active transport of amino acid, a larger extracellular space in tumor as compared with unaffected brain tissue may also contribute to the increased uptake of ^{11}C -L-methionine-derived radioactivity. In some patients delineation of the tumors was improved by use of PET with ^{11}C -L-methionine as compared with computed tomography, angiography, and, in some instances, PET with ^{68}Ga -EDTA. PET with ^{11}C -L-methionine permits better evaluation of the tumor extent and may affect preoperative grading.

Computed tomography (CT) has greatly improved the possibility of diagnosing gliomas. Serious limitations have been demonstrated, however, in the ability of CT to delineate the tumors with exactness [1, 2] before and after tumor treatment. Contrast-enhanced CT does not always allow correct histologic grading [3].

Several investigations have been reported concerning patients with gliomas examined by positron emission tomography (PET). Di Chiro et al. [4] observed high uptakes of ^{18}F -fluorodeoxyglucose in high-grade astrocytomas, whereas the glucose utilization in low-grade gliomas was significantly lower, of the same order as in normal white matter. Similar results were obtained by Rhodes et al. [5], who in a correlative study found an uncoupling between the relatively low regional oxygen consumption and the nondepressed regional glucose consumption in gliomas, verifying *in vivo* the experimental evidence of increased anaerobic glycolysis [6]. Wide variations in local blood volume and flow have been shown even in brain tumors of similar grade and type [7].

The observation of high relative uptakes of the amino acids methionine, histidine, valine, and isoleucine in gliomas compared with normal brain was of importance for an investigation by Hübner et al. [8], who used DL-1- ^{11}C -valine and DL-1- ^{11}C -tryptophan in studying brain tumors. Thirteen of their patients had high-grade gliomas. The observed intraindividual differences between the tumor uptake of the two amino acids could not be explained solely by defects in the blood-brain barrier, but were considered to indicate that active amino acid transportation contributed at least partly to the uptake.

The amino acid metabolism in normal individuals and in patients with phenylketonuria, dementia, and schizophrenia has been investigated with L-[methyl- ^{11}C] methionine by Comar et al. [9] and Bustany et al. [10, 11].

The aims of our investigation were fourfold: (1) to localize and delineate gliomas with PET after intravenous administration of L-methyl- ^{11}C -methionine (^{11}C -L-methionine) in patients; (2) to compare the results of the PET examinations with

Received October 4, 1984; accepted after revision March 15, 1985.

Presented in part at the annual meeting of the American Society of Neuroradiology, San Francisco, June 1983.

¹ Department of Diagnostic Radiology, University Hospital, Uppsala University, S-751 85 Uppsala, Sweden. Address reprint requests to A. Lilja.

² Department of Pharmacy, University Hospital, University of Uppsala, S-751 21 Uppsala, Sweden.

³ Department of Neurosurgery, University Hospital, University of Uppsala, S-751 21 Uppsala, Sweden.

⁴ Department of Organic Chemistry, Institute of Chemistry, University of Uppsala, S-751 21 Uppsala, Sweden.

⁵ Department of Physical Biology, Gustaf Werner Institute, University of Uppsala, S-751 21 Uppsala, Sweden.

AJNR 6:505–514, July/August 1985

0195–6108/85/0604–0505

© American Roentgen Ray Society

TABLE 1: Age, Gender, Diagnosis, and Survival in Patients with Gliomas

| Diagnosis: Case No. (age, gender) | Means of Diagnosis | Survival after Initial PET Study (months) |
|-----------------------------------|------------------------------|---|
| Astrocytoma, grade III: | | |
| 1 (43, M) | Surgery | 8 |
| 2 (61, M) | Surgery | 1 |
| 3 (53, M) | Autopsy | 10 |
| 4 (64, M) | Surgery | 8 |
| 5 (43, M) | Surgery | 14* |
| 6 (48, M) | Surgery | 7 |
| 7 (65, M) | Surgery | 10 |
| 8 (35, M) | Surgery | 10* |
| Astrocytoma, grade IV: | | |
| 9 (77, M) | Autopsy | 2 |
| High-grade glioma: | | |
| 10 (56, M) | Radiologic/clinical criteria | 17* |
| 11 (64, M) | Radiologic/clinical criteria | 5 |
| 12 (65, F) | Radiologic/clinical criteria | 6 |
| Astrocytoma, grade I: | | |
| 13 (23, M) | Surgery | 6* |
| Astrocytoma, grade I-II: | | |
| 14 (33, M) | Surgery | 6* |

* Patient still alive at this time.

information obtained from CT and/or angiography; (3) to use the kinetics of ^{11}C -L-methionine as an aid to grading or otherwise biologically characterizing the tumors; and (4) to evaluate if alterations of the result of PET examinations occurred after radiotherapy and/or surgery.

Subjects and Methods

The study group originally comprised 15 patients, of whom one was excluded. This patient had an astrocytoma grade III about 6 cm in diameter in the right temporal region, clearly discernible on ^{11}C -L-methionine PET examination, but the obtained and injected radioactivity was too low at 0.16 mCi (6 MBq) to allow closer analysis. Thus, the investigation was performed on 14 patients. They were 23–77 years of age (mean, 52) and were being treated as inpatients at the neurosurgical or neurological department of the University Hospital in Uppsala. The diagnosis of supratentorial glioma was based on clinical findings and radiological examinations, including CT (14/14 patients) and cerebral angiography (13/14 patients). In nine of the 14 patients the diagnosis was verified by surgical biopsy and in two additional cases at autopsy (table 1). The specimens were fixed in formalin, paraffin-embedded, and stained with hematoxylin-eosin. As seen in table 1, nine of these cases showed all the histopathologic criteria characteristic of astrocytoma grade III or IV according to the Kernohan classification. In two gliomas, biopsy specimens about $1.5 \times 3 \times 7$ mm (case 13) and $1.5 \times 1.5 \times 2$ mm (case 14) showed the presence of astrocytoma grade I and grade I-II, respectively. The morphologic diagnoses were made at our hospital by the same two neuropathologists who conducted the pathologic studies.

Thirteen of the 14 patients underwent cerebral angiography. The oldest patient was not subjected to angiography. No patient had received any specific tumor treatment before the first PET examination, but eight patients were on steroid medication (table 2). The patients were treated according to established clinical routines. The

treatment in nine of 14 patients is summarized in table 3. The two patients with low-grade astrocytomas did not receive any specific treatment nor did one other patient (case 2), whereas two patients (cases 9 and 12) were treated by irradiation. For survival data, see table 1.

The procedure and the administered amount of radioactivity at PET examinations had been evaluated and approved by the Ethical Committee of the Medical Faculty and by the hospital Isotope Committee. The patients' informed consent was a prerequisite for participation in the study. Women of childbearing age were not included in the study, but otherwise there was no deliberate selection of patients.

CT

In every patient CT was performed before and after intravenous injection of contrast medium (metrizoate 280 mg I/ml, 1.5 ml/kg body weight) 4–83 days (mean, 16.5 days) before the initial PET examination with ^{11}C -L-methionine. The long interval of 83 days occurred in a patient with a low-grade astrocytoma. The CT scanner used was either an EMI CT 1010 or a Siemens Somatom 2 or DR2. In those patients who underwent follow-up PET, CT was also repeated, except in two patients who were not available for CT reexamination. The first and second CT examinations were performed in a similar manner.

Angiography

Of the 13 patients subjected to carotid angiography, 12 underwent selective internal carotid catheterization, usually by puncture of and catheterization via the common carotid artery, but in a few patients by the transfemoral route. The contrast medium used was either metrizoate or iohexol (280 mg I/ml or 300 mg I/ml, respectively, Nyegaard), 7 ml injected in the internal carotid artery, and in one case, 10 ml injected in the common carotid. Magnification technique was employed in 10 of 13 cases.

PET

The PET scanner used (PC 384-3B, with two detector rings, one cross-plane, Instrument AB Scanditronix, Uppsala, Sweden) produced three simultaneous adjacent image slices 13–14 mm thick (full-width half-maximum) with a resolution of about 8 mm. The level and angulation of the PET scans were adjusted to resemble the individual CT examination as closely as possible by referring to the canthomeatal line. Centering was usually kept constant for at least 30 or 40 min to allow dynamic evaluation of the radioactivity; in a few cases supplementary images were obtained in lower or higher image planes. In all cases the examination started at the time of intravenous bolus injection of the radionuclide. A continuous dynamic investigation was begun with four or five 12–20 sec image recordings followed by four 40 sec recordings and then 200 sec exposures until the end of the examination.

PET with ^{68}Ga -EDTA. In eight patients with high-grade tumors, PET with an intravenous bolus injection of ^{68}Ga -EDTA not exceeding 5 mCi (185 MBq) was performed to study the extent and degree of any blood-brain barrier defect. In six of these patients the radioactivity was evaluated as a function of time. The uptake was followed in regions of interest representing a large venous sinus and the supposedly viable part of the tumor, attempts being made to avoid inclusion of any central necrosis or cyst, and in corresponding areas on the contralateral side or in the hemisphere least affected by the tumor.

PET with ^{11}C -L-methionine. ^{11}C produced at the Tandem Acceler-

TABLE 2: Results of Initial Examination in Patients with Supratentorial Gliomas

| Enhancement Pattern: Case No. | Edema | Steroid Medication | | Angiographic Vascularity | PET, Uptake of ^{11}C -L-Methionine | | | | |
|-------------------------------|-------|--------------------|--------|--------------------------|--|-------|---------------------------|-----------------------------------|-------------------|
| | | At CT | At PET | | Relative to CT | Ratio | To 90% of Max Ratio (min) | Slope $\times 10^{-2}$ Uptake/Min | Gray + White Mean |
| Homogeneous: | | | | | | | | | |
| 1 | ++ | — | — | 0 | = | 2.7 | 1.8 | 1.7 | 1.0 |
| Broad ring: | | | | | | | | | |
| 2 | ++ | + | + | + | = | 2.5 | 2.0 | 1.1 | 1.1 |
| 3 | +++ | — | + | +++ | = | 2.4 | 0.5 | -0.6 | 1.1 |
| 6 | — | + | — | ++ | = | 2.3 | 1.0 | 0.2 | 0.9 |
| 7 | +++ | + | + | + | = | 2.6 | 1.5 | 4.0 | 0.9 |
| 12 | ++ | + | + | ++ | = | 2.6 | 0.8 | 0.1 | 0.9 |
| Thin ring: | | | | | | | | | |
| 4 | ++ | + | + | + | > | 2.6 | 1.8 | -0.4 | 1.0 |
| 10 | ++ | + | + | ++ | > | 1.9 | 0.6 | 1.0 | 1.2 |
| 11 | ++ | — | — | +++ | = | 2.2 | 1.3 | -0.2 | 1.4 |
| Hypodense, no enhancement: | | | | | | | | | |
| 5 | — | — | + | + | >* | 4.8 | 1.8 | -2.8 | 0.7 |
| 13 | — | — | — | 0 | =† | 0.8 | 2.0 | 0.3 | 1.2 |
| 14 | — | — | — | 0 | ‡ | 1.0‡ | ‡ | ‡ | 0.8 |
| Thin and broad rings: | | | | | | | | | |
| 8 | ++ | + | + | 0 | = | 2.7 | 5.0 | 0.1 | 0.8 |
| Nearly homogeneous: | | | | | | | | | |
| 9 | + | — | — | § | = | 3.8 | 1.3 | 2.7 | 1.5 |

Note.—Edema grades: — = no visible edema; + = slight; ++ = moderate; +++ = extensive. Steroid medication at CT includes time of CT examination immediate preceding first ^{11}C -L-methionine PET study. At PET includes time of initial ^{11}C -L-methionine PET study. Angiographic vascularity grades: 0 = no tumor vascularization, vascular displacement only; + = angiographic blush without identifiable tumor vessels, or a shunting phenomenon; ++ = moderate tumor vascularization; +++ = richly vascular. Uptake extent compared with CT: > means uptake clearly more extensive than enhancement on CT; = means uptake comparable to or disputably greater than enhancing lesion on CT. Uptake ratio represents mean uptake ratio during 5–10 min interval after ^{11}C -L-methionine injection. Slope is defined in Results. Gray + white mean represents mean uptake in unaffected brain during 5–10 min interval after ^{11}C -L-methionine injection.

* Edema could not be discriminated from tumor tissue on CT.

† Low uptake corresponding to extent of hypodense lesion at CT.

‡ Not separable from surrounding brain.

§ No angiography.

TABLE 3: Treatment and Follow-up Examinations in Patients with High-Grade Gliomas

| Extent of Enhancing Lesion on CT: Case No. | PET Uptake of ^{11}C -L-methionine | | |
|--|---|-------------|---------------------------|
| | Change in Extent | Ratio Index | To 90% of Max Ratio (min) |
| Slight progression: | | | |
| 1 | Marked | 70 | 110 |
| 4 | Unchanged/disputable | 90 | 70 |
| 10 | Slight | 140 | 330 |
| No or disputable change: | | | |
| 5 | Unchanged/disputable | 80 | 90 |
| 6 | Unchanged/disputable | 70 | 110 |
| 8 | Slight | 60 | 60 |
| Regression: | | | |
| 3 | Unchanged/disputable | 80 | 100 |
| CT not performed: | | | |
| 7 | Unchanged/disputable | 90 | 70 |
| 11 | Slight | 90 | 60 |

Note.—Case 10 was treated with irradiation only; all other patients were treated with both surgery and irradiation. Ratio index: The uptake ratio or time to 90% of maximum ratio at the initial examination is given the value 100. Thus, an index greater than 100 at follow-up PET represents an increase, and an index less than 100 a decrease in comparison with the initial value. (See Subjects and Methods.)

ator Laboratory of Uppsala University was used for synthesis of ^{11}C -L-methionine [12]. The specific radioactivity at the end of synthesis was on the order of 10 mCi (370 MBq)/ μmol . The enantiomeric purity of ^{11}C -L-methionine was 99% or better [13] and the radiochemical purity was 98.5% or better.

No premedication was given to the patients, and their dietary routines were not altered before the examinations. After sterile filtration of ^{11}C -L-methionine, PET was started simultaneously with an intravenous bolus injection of radioactivity not exceeding 5 mCi (185 MBq) and was performed as a dynamic examination, as described above. The mean examination time was 50 min (range, 20–69 min). After image reconstruction the time course of the radioactivity was evaluated in regions of interest corresponding to (1) the whole estimated viable part of the tumor, (2) the area with the highest mean radioactivity ("hot-spot") within this tumor area, (3) the necrotic or cystic part of the tumor (if any), (4) the peritumoral edema (in those cases where it could be identified as an area of low radioactivity concentration on the PET scans), (5) areas of cortex and white matter in the contralateral hemisphere, (6) the complete area of the nontumorous hemisphere, and (7) a large venous sinus.

Evaluation of the radioactivity in tumor and peritumor areas in comparison with their anatomic counterparts in the contralateral hemisphere proved to be impossible in several of our cases of high-grade gliomas because of bilateral growth. With three PET image slices available for evaluation, corresponding gray- and white-matter areas could not be compared between different patients examined at different heights above the canthomeatal plane. Therefore, it was

chosen to relate uptakes in the tumoral and peritumoral areas to the whole contralateral hemisphere or to a region of interest, encompassing as much as possible of the hemisphere least invaded by tumor tissue. This area included both gray and white matter and the ventricular system. No patient, however, showed ventricular widening. Care was taken to avoid large venous sinuses in evaluating the radioactivity in the hemisphere. In the two cases of low-grade astrocytoma, the radioactivity uptake was compared with the morphologically corresponding area in the contralateral hemisphere. In the following the uptake levels are described as a dimensionless ratio (*uptake ratio*) between tumor/peritumor areas and the contralateral hemisphere. The time required to achieve 90% of maximum was used to characterize the early kinetics of the uptake ratio curves.

The radioactivity in whole blood was followed in five patients by sampling from a peripheral vein. Measurements were made in a well counter (NaI/Tl). The radioactivity was analyzed in the high molecular fraction (molecular weight > 5000) and the low molecular fractions of plasma, which were separated by gel filtration on Sephadex G 25 [14].

Follow-up Examinations

In nine patients follow-up examinations, including CT (in two of these CT could not be performed) and PET with ^{11}C -L-methionine, were carried out 1.5–6 months (mean, 3.3 months) after completion of tumor treatment. This time interval was chosen so that any treatment-induced barrier defect would have decreased as much as possible. The interval between initial and follow-up ^{11}C -L-methionine PET was 3.5–6.5 months (mean, 4.6 months). PET examinations were not repeated in the two patients with low-grade astrocytomas. Three patients with high-grade gliomas could not be reexamined.

Results

The principal findings in the initial CT, angiographic, and ^{11}C -L-methionine examinations are presented in table 2.

CT

Among the 12 patients with proven or suspected high-grade gliomas, the findings in two patients differed somewhat from the classic appearance of a ringlike enhancing structure. In case 1 the lesion was small, homogeneously enhancing, and lacked angiographic tumor vascularization. Case 5 had a predominantly right-sided bifrontal tumor of low attenuation and not exhibiting contrast enhancement, but with a vague angiographic blush at its cranial margin. This tumor had progressed since a CT examination 15 months earlier (fig. 1).

PET with ^{68}Ga -EDTA

PET with ^{68}Ga -EDTA demonstrated defects in the blood-brain barrier in all tumors displaying contrast enhancement on CT, in case 10 (fig. 2) with better precision than did CT. In case 5 only a minimal patch of high uptake was noted on CT in a small part of the margin of the large, low-attenuating, nonenhancing expanding lesion (fig. 1). The other six examinations with ^{68}Ga -EDTA in patients with high-grade gliomas showed a good correlation between the extent of the radioactivity uptake and the enhancing lesion as seen on CT.

^{11}C -L-methionine; Analysis of Blood and Plasma Samples

After the intravenous bolus injection of ^{11}C -L-methionine, the radioactivity in whole blood decreased rapidly. In the patients in whom blood samples were not collected, the radioactivity in the blood was estimated from regions of interest corresponding to large venous sinuses. This showed a similar time course to that in blood samples, but in several cases the final level exceeded that noted in samples, owing to partial-volume averaging from adjacent cortical structures. Analysis of the fate of the radioactivity in the separated plasma fractions (fig. 3) revealed rapid incorporation of radioactivity into the high molecular fraction (proteins) from 20 min after injection. The radioactivity in the low molecular fractions, containing free amino acids, thus declined more quickly than was apparent from the total blood radioactivity. This is of utmost importance with regard to quantification of the *in vivo* use of the present amino acid [10, 11, 14].

PET with ^{11}C -L-methionine

The radioactivity in the hemisphere contralateral to the tumor rose rapidly to a slightly increasing level within 2–3 min. In the area of viable tumor tissue the radioactivity invariably also showed a rapid increase (fig. 4), the length of time taken to reach 90% of the maximum uptake ratio varying from 0.6 to 5 min (mean, 1.6 min; SD, 1.2) in high-grade gliomas, with the same range in the two low-grade gliomas (table 2). There was a tendency toward shorter times up to 90% of the maximum uptake ratio in the more vascular tumors among the 11 patients with high-grade gliomas who underwent angiography. The tumor uptake ratio (mean of the viable tumor area) during the 5–10 min interval after the ^{11}C -L-methionine injection was no different in these angiographic subgroups, ranging from 1.9 to 4.8 (mean, 2.7). The uptake ratio in the tumor "hot spot" was usually 5%–40% above this figure and its time course was parallel to that in the whole viable tumor. In most of the high-grade gliomas the uptake exhibited a sluggish increase 5–45 min after injection. The slope for this time interval, estimated by linear regression, was -0.6×10^{-2} to 4.0×10^{-2} (mean, $[0.9 \pm 1.4] \times 10^{-2}$) uptake/min in 11 of 12 patients with high-grade tumors, excluding case 5 (described below). The 5–45 min uptake curve for most tumors was flatter or showed a slight downward slope compared with that for unaffected brain. Case 6 (figs. 4 and 5) exhibited the most common appearance of a high-grade glioma on CT and ^{11}C -L-methionine PET with a ring-shaped configuration and an uptake ratio of 2.3.

In three patients (cases 4, 5, and 10), the methionine examination demarcated the tumor considerably better than did CT (table 2). The most striking illustration of this is case 5 (figs. 1 and 4), in which CT showed a mass of low attenuation without significant contrast enhancement, whereas ^{68}Ga revealed only a marginally located small defect in the blood-brain barrier. PET with ^{11}C -L-methionine, on the other hand, depicted considerable and extensive uptake centrally. The markedly descending 5–45 min course of the uptake and ratio curves differed from those seen in the other malignant

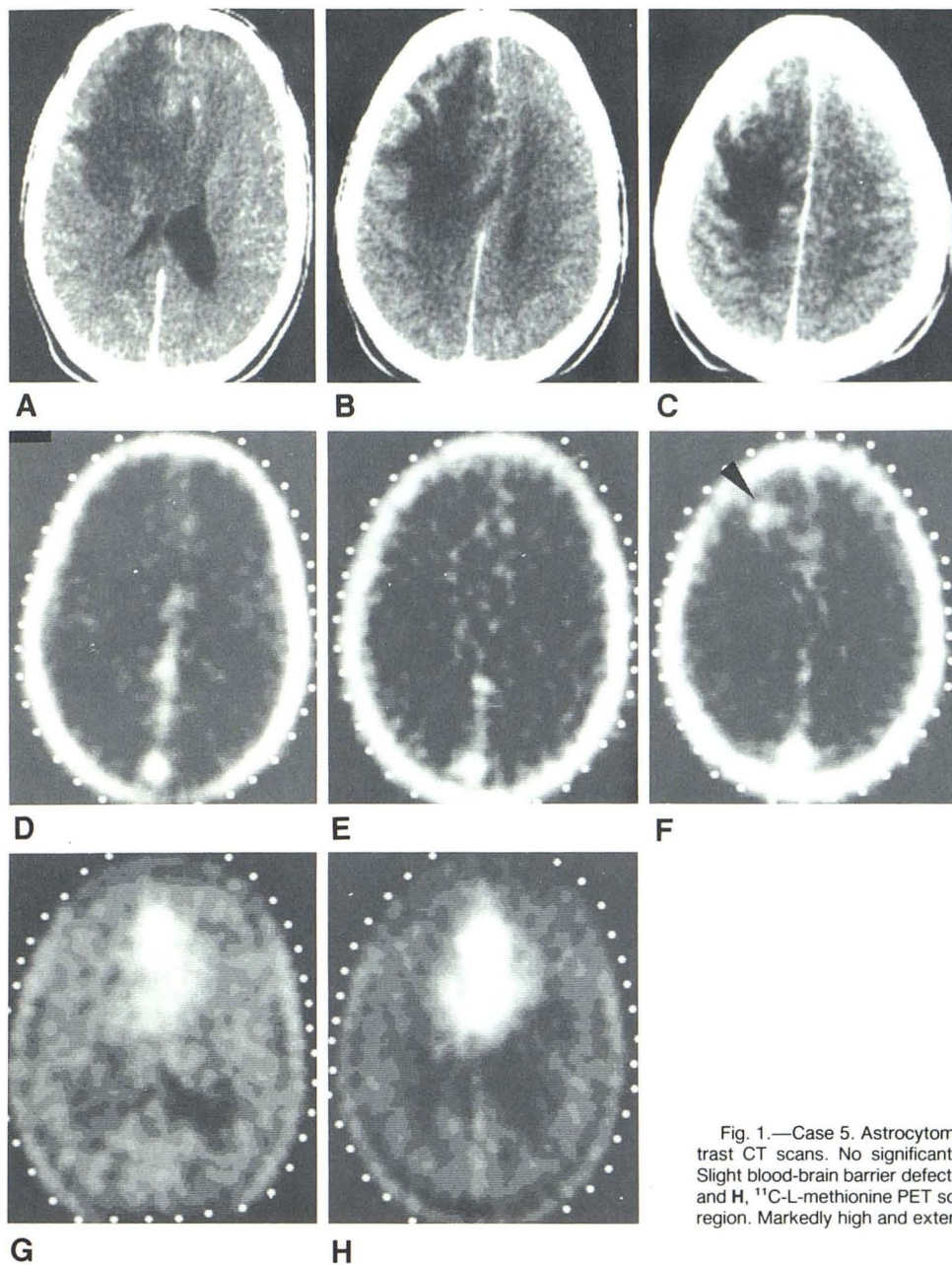


Fig. 1.—Case 5. Astrocytoma grade III. Initial examinations. A–C, Postcontrast CT scans. No significant enhancement. D–E, ⁶⁸Ga-EDTA PET scans. Slight blood-brain barrier defect at margin of low-density lesion (arrowhead). G and H, ¹¹C-L-methionine PET scans covering basal two-thirds of supratentorial region. Markedly high and extensive tumor uptake. (Modified from [15].)

gliomas (table 2). In case 10 (fig. 2), PET with ⁶⁸Ga-EDTA and ¹¹C-L-methionine showed intense uptake in a probable superficial extension of the tumor that was not apparent on CT until 6 months later.

In the high-grade tumors with a ring configuration the uptake corresponding to the central necrosis or cyst was usually considerably lower than in normal brain. Owing to partial-volume averaging and patient motion, these relatively small areas could not be evaluated more closely.

Peritumoral low attenuation has been shown often to represent not only edema but also diffusely growing, nonen-

hancing tumor tissue [1, 2]. In three patients (cases 3, 10, and 11) with high-grade gliomas, decreased radioactivity was seen in the peritumoral area, resembling the extent of the edema on CT.

Of the two low-grade gliomas, the grade I–II astrocytoma exhibited the same uptake as its anatomic counterpart in the opposite hemisphere, and was thus not discernible on PET images. Uptake dynamics revealed no apparent change. The grade I tumor displayed homogeneous moderately low uptake (fig. 6), with an uptake ratio (fig. 4) slightly exceeding that of white matter (tumor/white-matter ratio ≈ 1.3).

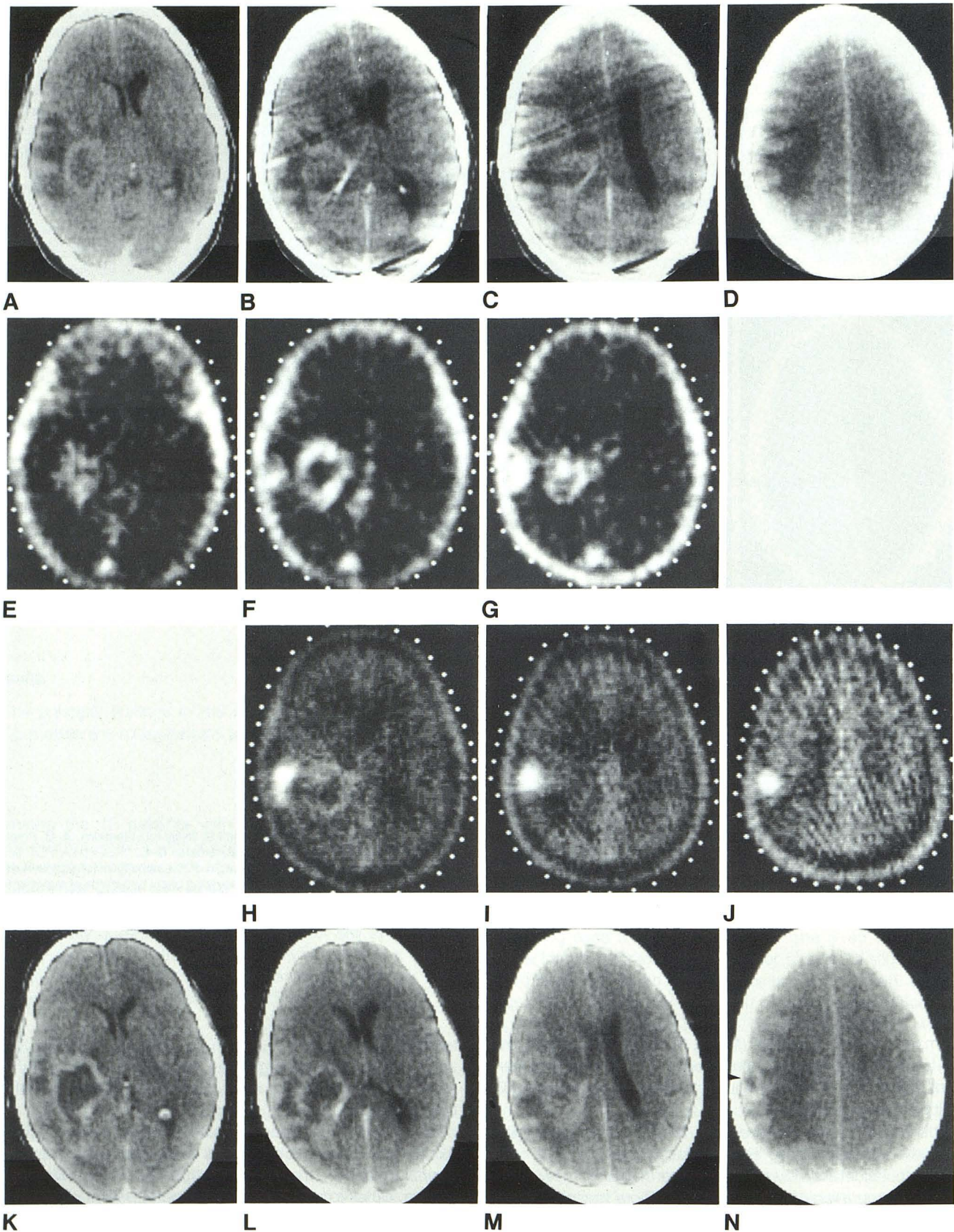


Fig. 2.—Case 10. Probable high-grade glioma adjacent to posterior part of sylvian fissure. **A–D**, Initial enhanced CT scans. Initial ^{68}Ga -EDTA (**E–G**) and ^{11}C -L-methionine (**H–J**) PET scans show superficial area of high uptake lateral to and more intense than "tumor ring." **K–N**, Enhanced CT scans 6 months later. Ringlike lesion (arrowhead) corresponds to region lateral to tumor ring.

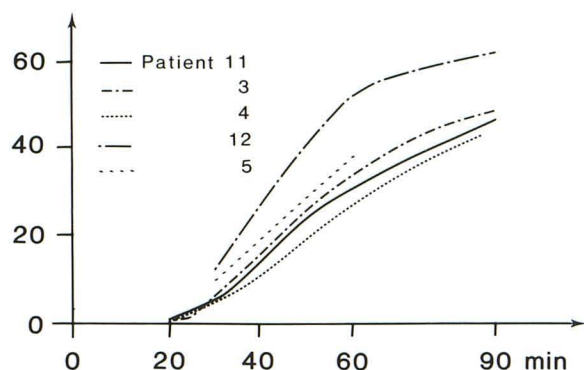


Fig. 3.— ^{11}C activity in plasma (sampled from peripheral venous blood) from time of bolus injection of ^{11}C -L-methionine. Y axis represents radioactivity in high molecular plasma fraction (molecular weight > 5000). Values are corrected for physical decay of ^{11}C .

Follow-up PET with ^{11}C -L-methionine

After completion of tumor treatment, follow-up PET was performed in nine of 12 patients with high-grade gliomas (table 3). Three patients showed a slight and one patient a marked increase in the volume of the radioactivity uptake, which was interpreted as progression. Two of these patients also displayed signs of progression on the CT image. Three of these four patients are still alive, including the patient with marked progression. At the follow-up examinations only minor changes were seen in the tumor uptake ratio. In three patients there was a moderate decrease, in five there was a slight decrease, and in one there was an increase; the mean change in the nine patients was not significant ($-14\% \pm 22\%$). The alterations in the length of time up to 90% of the maximum uptake ratio were also usually small, except in case 10.

Discussion

The complex fate of intravenously injected ^{11}C -L-methionine makes it difficult to estimate local protein synthesis in normal brain or tumor tissue [14]. It remains to be elucidated to what extent diffusion and/or active transportation affects the tracer uptake in brain tumors of different grades of malignancy.

The three high-grade tumors with the highest ^{11}C -L-methionine uptake ratios were all nearly homogeneous at CT, either with respect to enhancement (cases 1 and 9) or in showing a uniform lack of enhancement throughout the tumor (case 5). These high uptakes might thus be attributable to a lack of partial-volume averaging from necroses at the PET examination. The tendency toward somewhat lower uptake ratios among the high-grade gliomas with a thin ring configuration compared with those with a broad rim is probably due to partial-volume effects. A defective blood-brain barrier was obviously not a prerequisite for high ^{11}C -L-methionine uptakes. The time course of the uptake, which was nearly constant and considerably higher than in the case of an even distribution in the body from 5 min postinjection in most patients, tends to support the view that active amino acid

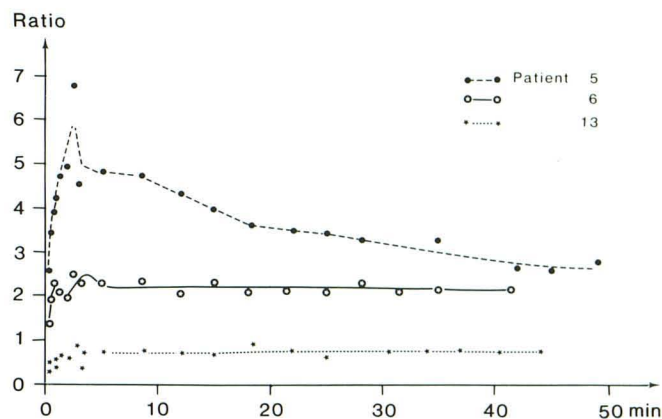


Fig. 4.—Tumor/contralateral hemisphere uptake ratio from time of ^{11}C -L-methionine injection in two patients with astrocytoma grade III (cases 5 and 6) and one patient with astrocytoma grade I (case 13). Near constancy of ratio in cases 6 and 13 with time after initial 5 min contrasts with unusual and marked downslope of ratio curve in case 5.

transportation is a major determinant for the uptake (fig. 7). A large fraction of passive diffusion resulting solely from a defective blood-brain barrier would not be expected to yield a tumor uptake of such considerable and constant magnitude. This concept is further supported by the uptake dynamics in the two patients with low-grade glioma, in whom the ^{11}C -L-methionine uptake followed a similar time course on a lower level.

It is reasonable to suggest that a larger extracellular space in a tumor may contribute to the increased uptake relative to unaffected brain tissue. The change of the slope in the uptake time curves indicates that an equilibrium between blood and tissue is attained some 5 min postinjection. The time course of the ^{11}C -L-methionine-derived radioactivity after equilibrium reflects the sum of the uptake, including the incorporation into proteins and the elimination of the radioactivity. It is obvious that in most patients the relation between these processes is of the same order in tumor tissue and in unaffected brain. The rate of synthesis is rapid, and Bustany et al. [11] found that within 45 min 50% of the ^{11}C -methionine-derived radioactivity was incorporated into proteins in the brain tissue of baboons. In our investigations ^{11}C -L-methionine in plasma was also rapidly incorporated, as seen in figure 3.

In three patients the uptake of ^{11}C -L-methionine at PET was more extensive than was anticipated from the enhanced CT scan. One lesion was delineated equally well by ^{68}Ga -EDTA PET (case 10). In case 4 the ^{11}C -L-methionine uptake was clearly more extensive than was expected from the appearance of the tumor on CT (a ^{68}Ga -EDTA examination was not performed in this case). The finding in case 5 of a high ^{11}C -L-methionine uptake ratio in the absence of a corresponding blood-brain barrier defect is striking. No local increase in blood volume was found at the ^{68}Ga -EDTA examination. Thus, judging from the marked decline of the uptake ratio curve (fig. 4), a net efflux of ^{11}C in unknown form seems to have occurred.

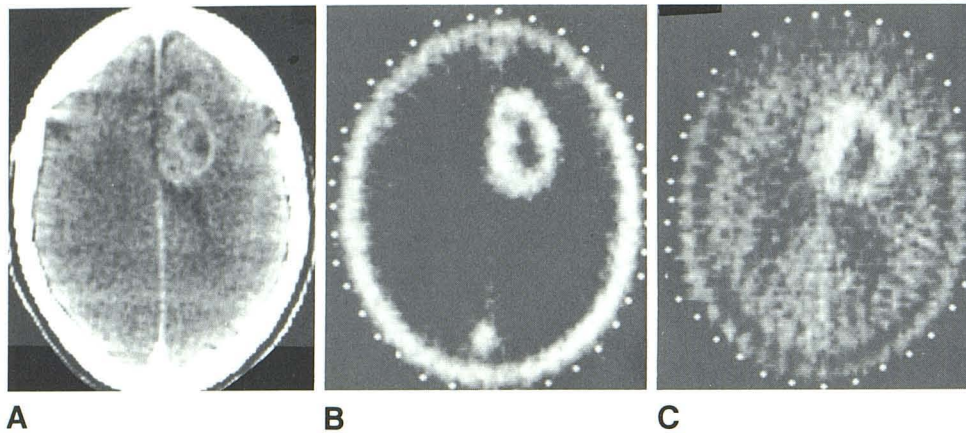


Fig. 5.—Case 6. Astrocytoma grade III. Good correspondence between enhanced CT scan (A), ^{68}Ga -EDTA PET scan (B), and ^{11}C -L-methionine PET scan (C).

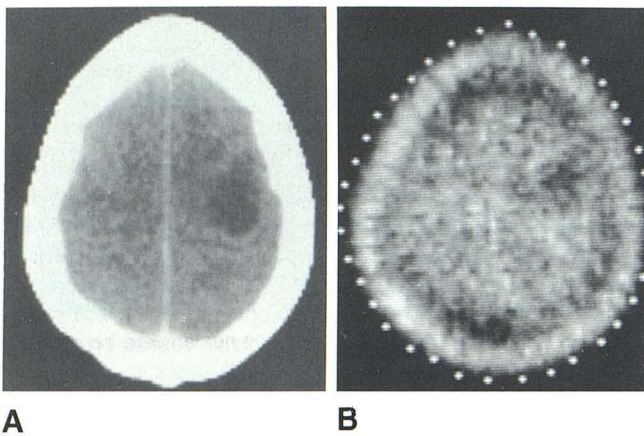


Fig. 6.—Case 13. Astrocytoma grade I. Low ^{11}C -L-methionine uptake (B) corresponds to hypodense, nonenhancing lesion on CT (A).

In the search for methods for better delineation of diffusely growing gliomas, there are obvious advantages in using physiologic tracers that cross the intact blood-brain barrier instead of relying on the relatively nonspecific phenomenon of defects in this barrier. Even with our limited clinical material, however, it is obvious that low-grade gliomas might occasionally be indiscernible when exhibiting the same methionine uptake as normal brain. This was true in case 14, where the tumor was clearly visible on CT and hypothetically might have shown a low uptake had it been studied with a glucose analog. The fact that the grade I-II astrocytoma exhibited an ^{11}C -L-methionine uptake similar to that in normal brain and higher than that in the grade I tumor suggests a potential for grading gliomas, perhaps on a level of the Kernohan scale, different from that in methods that measure glucose use [4, 5]. This aspect seems important in view of the increasing accumulation of evidence for the nonspecificity of contrast enhancement on CT with respect to tumor grade [3, 16].

In the follow-up investigations, neither survival time nor signs of tumor progression appeared to bear any correlation to the ^{11}C -L-methionine uptake dynamics or ratio. This might have been partly because of the limited number of patients

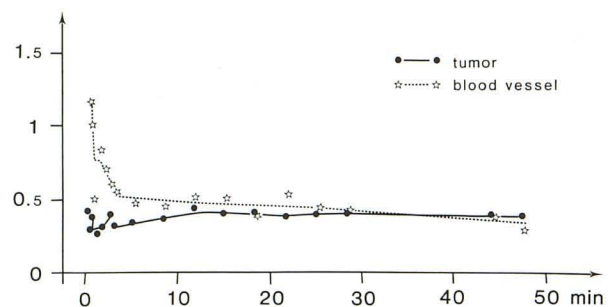
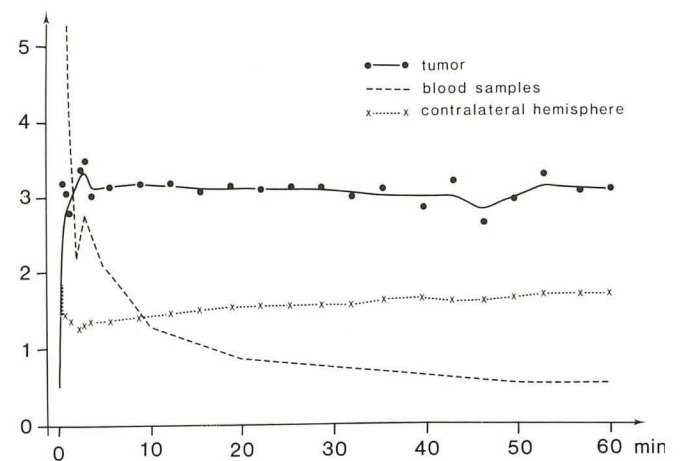


Fig. 7.—A, Case 11. High-grade glioma, ^{11}C -L-methionine examination. Parallelism between tumor uptake curve and uptake in normal hemisphere illustrates reason for usual near constancy with time of uptake ratio (cf. fig. 4). Blood radioactivity (measured in well counter) rapidly decreased. Uptakes are normalized to amount of injected radioactivity and body weight and assuming ^{11}C -L-methionine is evenly distributed in body. (Uptake 1.0 equal to even distribution). B, Case 6. Astrocytoma grade III, ^{68}Ga -EDTA examination. Tumor uptake gradually approached radioactivity level in sagittal sinus. Blood-borne radioactivity was probably underestimated, in view of small region of interest. Uptakes are normalized to amount of injected radioactivity and assuming that ^{68}Ga -EDTA is distributed in extracellular part of the body volume. (Modified from [15].)

studied. The usually minimal changes in uptake ratios seen on follow-up PET with ^{11}C -L-methionine might reflect the shortcomings of the present treatment of high-grade gliomas or they may be from a lack of relation between the methionine

uptake and tumor activity.

As most of the patients with high-grade tumors showed an extensive blood-brain barrier defect, the local blood volume in tumor areas could not be calculated from the results of ^{68}Ga -EDTA examinations. This lack of correction for blood volume does not seriously affect the analysis of the late part of the ^{11}C -L-methionine uptake curve, as ^{11}C blood radioactivity declines rapidly [14].

At present we know little about the events occurring in the tumors within the first minutes after ^{11}C -L-methionine injection. In the angiographically more vascular gliomas, the tendency toward shorter time up to the attainment of 90% of the maximum uptake ratio seemed significant ($p < 0.05$) compared with the less vascular tumors. The lack of correction for local blood volume, however, would be expected to affect not only the length of time up to 90% of maximum radioactivity uptake, but also the interval up to the 90% maximum uptake ratio. In 10 patients in whom the radioactivity in the blood could be estimated, the error in determining the time up to 90% of the maximum uptake and ratio was estimated by using different hypothetical values for local blood volumes within the range described by Lammertsma et al. [7]. These estimations verified that the errors in evaluating the 0–5 min postinjection time course of uptake curves were considerable. The errors in the ratio curves were less pronounced but still sufficiently large to be suspected to account for the differences between the two patient groups, as the time up to 90% of the maximum uptake ratio tended to be underestimated in the patients with more vascular gliomas and overestimated in those with less vascularized tumors. Moreover, the time required for equilibrium between blood and tissue is largely determined by the blood flow, which is highly variable in gliomas [7]. In our study, no attempts were made to estimate local blood flow.

The influence of steroid medication in several of the patients with high-grade gliomas is unclear, although theoretically it is possible that the uptake might have been reduced by steroid effects on the blood-brain barrier defects and/or on the tumor itself, through an effect on protein metabolism [6, 17, 18]. We found no correlation between steroid treatment and ^{11}C -L-methionine tumor uptake kinetics. It is unclear whether steroid medication in the usually short interval between CT and PET might have obscured any previously existing change in methionine uptake in the peritumoral edema. The possibility that ^{11}C -labeled products may have leaked into the peritumoral region during the examination, thus masking the edema, seems less probable, judging from the uptake kinetics in these areas, although influences by the nearby high tumor uptakes and occasional motion artifacts made evaluation somewhat difficult. Diffusely growing tumor in areas where CT indicated the presence of edema could be a more plausible explanation for the lack of peritumoral low ^{11}C -L-methionine uptakes in several cases [1, 2].

Despite the uncertainty concerning the physiologic interpretation of the uptake values for ^{11}C -L-methionine, the method yields images that seem to outline well the morphologic extent of gliomas. To elucidate the mechanisms of ^{11}C -L-methionine uptake in normal brain and in tumors and their surroundings, further experimental work in animal and in vitro tumor models

is required. PET with ^{11}C -L-methionine already seems to be a valuable tool for achieving better delineation of gliomas from surrounding secondary changes such as edema and, with some limitations, also from normal brain. Findings in two patients with low-grade gliomas raise the question whether the method could aid in distinguishing between different grades within the low-grade part of the Kernohan scale. This indicates a difference compared with methods that measure glucose utilization or simply reveal defects in the blood-brain barrier.

REFERENCES

1. Lilja A, Bergström K, Spännare B, Olsson Y. Reliability of computed tomography in assessing histopathological features of malignant supratentorial gliomas. *J Comput Assist Tomogr* **1981**;5:625–636
2. Burger PC, Dubois PJ, Schold SC, et al. Computerized tomographic and pathologic studies of the untreated, quiescent and recurrent glioblastoma multiforme. *J Neurosurg* **1983**;58:159–169
3. Silverman C, Marks JE. Prognostic significance of contrast enhancement in low-grade astrocytomas of the adult cerebrum. *Radiology* **1981**;139:211–213.
4. Di Chiro G, De La Paz RL, Brooks RA, et al. Glucose utilization of cerebral gliomas measured by ^{18}F /fluorodeoxyglucose and positron emission tomography. *Neurology (NY)* **1982**;32:1323–1329
5. Rhodes CG, Wise RJS, Gibbs JM, et al. In vivo disturbance of the oxidative metabolism of glucose in human cerebral gliomas. *Ann Neurol* **1983**;14:614–626
6. Kirsch WM, Tucker WS, Tabuchi K, Fink LM, van Buskirk JJ, Low M. The metabolism of the glioblastoma: pathobiological correlates. *Clin Neurosurg* **1978**;25:310–325
7. Lammertsma AA, Wise RJS, Jones T. In vivo measurements of regional cerebral blood flow and blood volume in patients with brain tumours using positron emission tomography. *Acta Neurochir (Wien)* **1983**;69:5–13
8. Hübner KF, Parvis JT, Mahaley SM, et al. Brain tumor imaging by positron emission computed tomography using ^{11}C -labeled amino acids. *J Comput Assist Tomogr* **1982**;6:544–550
9. Comar D, Saudubray JM, Duthilleul A, et al. Brain uptake of ^{11}C -methionine in phenylketonuria. *Eur J Pediatr* **1981**;136:13–19
10. Bustany P, Henry JF, Sargent T, et al. Local brain protein metabolism in dementia and schizophrenia: in vivo studies with ^{11}C -L-methionine and positron emission tomography. In: Heiss W-D, Phelps ME, eds. *Positron emission tomography of the brain*. Berlin: Springer-Verlag, **1983**:208–211
11. Bustany P, Henry JF, Cabaris E, Soussaline F, Crouzel M, Comar D. Incorporation of L- (^{11}C) -methionine in brain proteins studied by P.E.T. in dementia. In: Raynaud C, ed. *World congress of nuclear medicine and biology III, Paris: nuclear medicine and biology advances*. Oxford: Pergamon, **1983**:2216–2219
12. Långström B, Lundqvist H. The preparation of ^{11}C -methyloide and its use in the synthesis of ^{11}C -methyl-L-methionine. *Int J Appl Radiat Isot* **1976**;27:357
13. Lundqvist H, Långström B, Malmkvist M. Determination of enantiometric purity in biogenic ^{11}C -labelled amino acids by aminoacylation of t-RNA. *J Radioanal Chem* (in press)
14. Lundqvist H, Stålnacke CG, Långström B, Jones B. Labelled metabolites in plasma after i.v. administration of ^{11}C -L-methionine. In: Grietz T et al, eds. *The metabolism of the human brain studied by positron emission tomography*. New York: Raven, **1985**:233–240

15. Lilja A, Bergström K, Spännare B, et al. Dynamic study of supratentorial gliomas by positron emission tomography (PET) with ^{11}C -L-methionine. In: *Proceedings of the third symposium on the medical application of cyclotrons*, June 13–16, 1983, Turku, Finland. (in press)
16. Patronas NJ, Brooks RA, De La Paz RL, Smith BH, Kornblith PL, Di Chiro G. Glycolytic rate (PET) and contrast enhancement (CT) in human cerebral gliomas. *AJNR* **1983**;4:533–535
17. Hatam A, Bergström M, Yu Z-Y, Granholm L, Berggren BM. Effect of dexamethasone treatment on volume and contrast enhancement of intracranial neoplasms. *J Comput Assist Tomogr* **1983**;7:295–300
18. Crocker FF, Zimmerman RA, Phelps ME, Kuhl DE. The effects of steroids on the extravascular distribution of radiographic contrast material and technetium pertechnetate in brain tumors as determined by computed tomography. *Radiology* **1976**;119:471–474