



Get Clarity On Generics

Cost-Effective CT & MRI Contrast Agents



FRESENIUS
KABI

WATCH VIDEO

AJNR

Chymopapain Chemonucleolysis: Correlation of Diagnostic Radiographic Factors and Clinical Outcome

Lindell R. Gentry, Charles M. Strother, Patrick A. Turski, Manucher J. Javid and Joseph F. Sackett

This information is current as of August 6, 2025.

AJNR Am J Neuroradiol 1985, 6 (3) 311-320
<http://www.ajnr.org/content/6/3/311>

Chymopapain Chemonucleolysis: Correlation of Diagnostic Radiographic Factors and Clinical Outcome

Lindell R. Gentry^{1,2}
Charles M. Strother¹
Patrick A. Turski¹
Manucher J. Javid³
Joseph F. Sackett¹

The therapeutic response to treatment of lumbar disk herniation with chymopapain chemonucleolysis is significantly influenced by the criteria used for patient selection. Although careful clinical selection of patients reduces the frequency of treatment failure, some patients do not achieve satisfactory relief of pain with chemonucleolysis. In an attempt to identify objective pretreatment radiographic findings that might refine selection criteria and further reduce the failure rate of chemonucleolysis, a retrospective correlation of pretreatment radiographs and clinical responses was made of 200 consecutive chemonucleolysis patients. Marked improvement in sciatica occurred in 79.9% and 79.3% of patients at early and late follow-up, respectively. There was a significantly higher response rate, however, in patients who had definite radiographic evidence of focal disk herniation and in those patients with definite radiographic evidence of nerve-root compression (marked nerve-root deviation, nerve-root flattening or edema, root-sleeve amputation) by disk material. Those patients with a preinjection disk height greater than the mean had a slightly better response rate (91.1%) than those whose disk height was smaller than the mean (80.0%). Most cases of treatment failure could be attributed to an incorrect radiographic diagnosis, treatment of patients with equivocal diagnostic studies, the presence of "free" disk fragments, and causes of nerve-root compression unresponsive to chymopapain.

Chymopapain, a proteolytic enzyme derived from papaya latex, catalyzes the rapid hydrolysis of the chondromucoprotein part of the nucleus pulposus of the intervertebral disk. In 1964, Smith [1] first demonstrated the possibility of using chymopapain to enzymatically treat lumbar disk herniations (chymopapain chemonucleolysis). Clinical trials designed to establish the safety and efficacy of this procedure quickly followed.

By 1975, over 17,000 people had been treated with chymopapain chemonucleolysis in 75 centers [2, 3]. Wide variations were reported in the frequency of successful results, ranging from 50% to 80%, and controversy concerning its effectiveness abounded [4–8]. The first double-blind study comparing chymopapain with placebo, completed in 1976, found no statistically significant difference in response rates [4]. This protocol, however, was not well designed and the results are generally agreed to be inconclusive [9–11]. Two recent double-blind studies have described favorable results in 73% [12] and 80% [13], respectively, of the patients treated with chymopapain compared with 42% [12] and 57% [13] of those treated with placebo. While these studies, in our opinion, demonstrate the overall efficacy of chymopapain chemonucleolysis, questions remain concerning optimal patient selection for this procedure.

The influence that clinical selection parameters for chemonucleolysis have on clinical outcome is well known [2, 3, 14–17]. Some reports have suggested that radiographic selection parameters may influence response [14, 15, 18–20], but there has not been any in-depth study of these relations. We retrospectively analyzed the diagnostic radiographs of 200 consecutive patients treated with chymopapain chemonucleolysis at the University of Wisconsin to identify: (1)

This article appears in the May/June 1985 issue of *AJNR* and the August 1985 issue of *AJR*.

Received December 27, 1983; accepted after revision May 3, 1984.

Presented in part at the annual meeting of the American Society of Neuroradiology, San Francisco, June 1983.

¹ Department of Radiology, University of Wisconsin Hospital and Clinics, Madison, WI 53792.

² Present address: Department of Radiology, University of Iowa Hospitals and Clinics, 7006 Carver, Iowa City, IA 52242. Address reprint requests to L. R. Gentry.

³ Division of Neurosurgery, University of Wisconsin Hospital and Clinics, Madison, WI 53792.

AJNR 6:311–320, May/June 1985

0195–6108/85/0603–0311

© American Roentgen Ray Society

pretreatment radiographic selection criteria predictive of therapeutic response, (2) the temporal radiographic changes that occur after chemonucleolysis, and (3) the most frequent causes of treatment failure.

Materials and Methods

A retrospective correlative analysis of all radiographic studies and the clinical responses was performed for 200 consecutive patients treated with chymopapain chemonucleolysis. All available radiographic studies (spine radiographs, diskograms, conventional and metrizamide-enhanced spine CT scans, myelograms) of these patients were reviewed by three neuroradiologists (L. R. G., C. M. S., P. A. T.), none of whom had knowledge of the patient's eventual clinical outcome. Radiographic findings were then correlated with response. The first 144 patients underwent chemonucleolysis with Discase (Baxter Travenol Labs.) between November 1972 and July 1981, while the last 56 had chemonucleolysis with Chymodiactin (Smith Labs.) between December 1982 and May 1983. In all instances, the prechemonucleolysis clinical evaluation, chymopapain injection, and all postchemonucleolysis clinical evaluations were performed by the same neurosurgeon (M. J. J.).

All patients were selected for chemonucleolysis on the basis of strict, predefined clinical criteria that remained constant throughout the course of the study. These criteria were the same as those used by the neurosurgeon to select patients for surgical discectomy. All patients had intractable sciatica with radicular pain equal to or greater in severity than any associated low-back pain. All had objective abnormalities on neurologic examination, as well as the reproduction of sciatica on straight-leg raising.

The types and frequencies of diagnostic tests used for the pretreatment evaluation of the study population varied considerably over the 11 year study interval. Greater reliance was placed on clinical and electromyographic evidence of a disk herniation during the initial phase of the study (cases 1–45). Eight of these patients did not have a pretreatment myelogram, and seven had only equivocal or suspicious myelographic abnormalities. During this period, because of the protocol, the three lower lumbar interspaces were studied with diskography. All disks confirmed to be abnormal by diskography were injected with chymopapain, whether or not there was an associated myelographic defect. In the latter part of the study (cases 45–200), increasing reliance was placed on radiographic evidence of disk herniation. This was primarily due to the marked improvements in imaging techniques for disk disease as the study progressed. In this part of the study, chemonucleolysis was performed only at the levels of myelographic or CT abnormalities, provided that they corresponded with the clinical evaluation.

Pretreatment anteroposterior and lateral lumbar spine films were obtained in all patients. Myelography was performed in 192 of 200 patients, 75 of whom were studied with metrizamide as the contrast medium. Thirty-four patients had prechemonucleolysis CT scans; one-third of these were obtained shortly after a metrizamide myelogram. With few exceptions, all CT scans were obtained with either a General Electric 8800 or a Siemens Somatom DR-3 scanner.

Two hundred patients had 287 disks treated with chymopapain chemonucleolysis. Most patients who had more than one disk injected were treated during the first part of the study (cases 1–45). With the patient in the lateral decubitus position, chemonucleolysis was performed under either general anesthesia (124 patients) or local anesthesia supplemented by intravenous sedation (76 patients). Using the lateral extradural approach and fluoroscopic guidance, an 18 gauge spinal needle was placed within the nucleus pulposus of the appropriate intervertebral disk space. Positive contrast diskography was

used to confirm the correct needle placement within the nucleus pulposus, to exclude intrathecal entry of contrast material, and to document the abnormal character of the disk. After diskography, 2000–4000 U of chymopapain was injected.

Posttreatment diagnostic studies were performed in a number of asymptomatic as well as symptomatic patients. Lumbar spine radiographs were obtained in the first 124 patients at 5 days, 6 weeks, and 6 months after chemonucleolysis. Those who continued to have sciatica or those who developed new symptoms after chemonucleolysis had repeat spinal radiographs at various intervals. Twenty patients underwent repeat lumbar myelography after chemonucleolysis. Nine were evaluated because of persistent pain, nine were reexamined to evaluate symptoms that developed after a significant pain-free interval (2–6 years), and two were studied, incidentally, at the time of subsequent cervical myelography.

The nature of clinical responses after chemonucleolysis was determined by the same neurosurgeon who had performed the pretreatment clinical evaluations. At follow-up, each patient was assigned to either a marked improvement (satisfactory outcome) or to a slight/no improvement (unsatisfactory outcome) group. The marked improvement group was subdivided into those who were symptom-free, those with an excellent response (at least 85% relief of pain), and those having a good response (50%–85% relief of pain). The slight/no improvement group was further divided into those having a fair response (25%–50% pain relief) and those having only slight or no improvement (less than 25% relief). Posttreatment clinical evaluation was performed at 6 weeks, 6 months, 12 months, and 24 months after chemonucleolysis in the first 124 patients. The next 20 patients were examined at 3 weeks, 6 weeks, 3 months, and 6 months after treatment. The last 56 patients were evaluated at 6 weeks and 6 months after chemonucleolysis. A questionnaire was sent to the first 124 patients, providing a 3–6 year follow-up in the 114 patients who responded [2]. For purposes of statistical analysis, end points were defined for early and late follow-up. Early response was defined at follow-ups of 3 months or less, while late response was determined as the longest follow-up available for each patient (up to 6 years).

Statistical analyses of the relations between clinical outcomes and various radiographic parameters were made at both early and late follow-up by chi-square analysis. All *p* values of statistical significance are one-sided, reported to three decimal places, and use Yates correction for sample size. For small sample sizes, the Fisher exact probability test was used.

To determine factors associated with an unsatisfactory outcome, the medical records and diagnostic tests of those patients not responding to chemonucleolysis were analyzed separately. Pre- and posttreatment radiographic studies of these symptomatic patients were reviewed to determine the most likely cause of chemonucleolysis failure.

Results

The overall results of chymopapain chemonucleolysis in our series are shown in table 1. Marked improvement in sciatica was noted in 79.9% of the patients at the time of early follow-up and in 79.3% at the time of late reevaluation. Over time, an important change occurred in the distribution of patients within the subgroups of the marked improvement group. The percentage of those classified as being either asymptomatic or having excellent relief of pain changed from 40.9% at early follow-up to 84.1% at late follow-up.

Patients who had a previous laminectomy were found to have a significantly lower response rate ($p < 0.001$) than were those without such prior surgery. The outcome was

TABLE 1: Pain Relief in Patients Treated with Chymopapain Chemonucleolysis

Level of Improvement: Degree of Pain Relief	No. of Patients (%)	
	Early Follow-up	Late Follow-up
Marked:		
Asymptomatic	41 (25.8)	77 (49.1)
Excellent (>85%)	24 (15.1)	55 (35.0)
Good (50%–85%)	94 (59.1)	25 (15.9)
Subtotal	159 (79.9)	157 (79.3)
Slight/none:		
Fair (25%–50%)	20 (50.0)	16 (39.0)
None (<25%)	20 (50.0)	25 (61.0)
Subtotal	40 (20.1)	41 (20.7)
Total	199	198

Note.—Early follow-up was less than 3 months; late follow-up was 3 months to 6 years.

significantly more favorable ($p < 0.005$) in the group of patients who did not have a workers' compensation claim pending. During the 11 year study, as experience was gained in both patient selection and performance of the procedure, there was a statistically significant improvement in the favorable response rate at early ($p < 0.01$) and late ($p < 0.001$) follow-up (table 2). The clinical outcome was not significantly associated with the patient's age, gender, or the number of intervertebral disks injected.

Influence of Pretreatment Radiographic Selection Parameters on Clinical Response

The radiographs of all patients, except those who had prior surgery or a pending workers' compensation claim, were analyzed to identify the relations between clinical responses and diagnostic radiographic variables. Early and late follow-up was available in 153 and 152 patients, respectively, who met these inclusion criteria. On the basis of all available preinjection radiographic studies, each patient was placed into one of two groups based on the degree of confidence that the reviewers had that a disk herniation was present. The myelograms and CT scans were also analyzed individually to assess the probability of disk herniation.

The myelographic criteria [21, 22] used to define the high-probability group included: (1) angular extradural deformity of the thecal sac centered at the interspace; (2) anterolateral location of the extradural compressive defect, typically accentuated on the oblique projection; and (3) myelographic evidence of nerve-root compression (root-sheath amputation, marked nerve-root deviation, distal-nerve-root flattening/widening/edema). The patients placed into the lower-probability group invariably had myelographic abnormalities, but these were much less characteristic of a disk herniation. The abnormalities on the myelograms of these patients were more typical of diffusely bulging disk, mild to moderate spinal stenosis, osteophytic root-sleeve compression due to lumbar spondylosis, or nonspecific root-sleeve asymmetry.

The CT criteria [23] used to define the high-probability group included: (1) a focal abnormality in the contour of the

TABLE 2: Correlation of Demographic Data and Response in Patients Treated with Chymopapain Chemonucleolysis and Showing Marked Improvement

Demographic Parameter	% of Patients with Marked Improvement	
	Early Follow-up	Late Follow-up
Overall results	79.9	79.3
Prior laminectomy:		
Yes	46.2	41.7
No	82.7*	86.3†
Workers' compensation claim pending:		
Yes	58.3	52.9
No	81.7‡	86.6*
Study interval:		
First 45 patients	64.4	57.8
Last 155 patients	84.4§	84.5†
Age:		
<45 years	79.5	81.5
>45 years	81.4	83.7
Gender:		
Male	81.7	85.7
Female	77.6	76.9
No. of interspaces treated:		
One	83.5	87.8
More than one	74.3	75.8

* $p < 0.005$.

† $p < 0.001$.

‡ $p < 0.025$.

§ $p < 0.01$.

TABLE 3: Radiographic Probability of Disk Herniation and Response in Patients Treated with Chymopapain Chemonucleolysis

Probability: Time of Response	No. of Patients (%)		
	Marked Improvement	Slight/No Improvement	Total
Higher:			
Early	96 (90.6)	10 (9.4)	106
Late	100 (95.2)	5 (4.8)	105
Lower:			
Early	35 (74.5)	12 (25.5)	47
Late	34 (72.3)	13 (27.7)	47

posterior disk margin; (2) displacement, compression, or deformity of the thecal sac or nerve-root sheaths; (3) displacement of epidural fat; and (4) extension of material of disk density above or below the interspace. Patients placed into the lower-probability group on CT (nine patients) had either a diffusely bulging anulus (two patients), very minimal focal contour abnormalities of the disk margins (five patients), or root-sheath compression due to lumbar spondylosis (two patients).

On the basis of all diagnostic studies, 106 patients were placed in the higher-probability group and 47 were placed in the lower-probability group. At early follow-up, marked improvement of sciatic pain was noted in 90.6% of patients believed to have a high probability of disk herniation, but in only 74.5% of those whose studies were judged to be less characteristic of disk herniation (table 3). At late follow-up, marked improvement was noted in 95.2% and 72.3% of those

TABLE 4: Correlation of Myelographic Selection Criteria and Clinical Response in Patients Treated with Chymopapain Chemonucleolysis and Showing Marked Improvement

Myelographic Criteria	% of Patients with Marked Improvement	One-sided p Value
Probability of herniation:		
Higher	89.1	<0.05
Lower	68.0	
Root-sleeve amputation:		
Yes	87.3	<0.025
No	65.4	
Nerve-root flattening/edema:		
Yes	91.1	<0.005
No	71.2	
Nerve-root deviation:		
Yes	89.4	<0.1
No	76.5	

in the higher- and lower-probability groups, respectively. This difference in response was statistically significant at early ($p < 0.025$) and late ($p < 0.001$) follow-ups.

Evaluation of pretreatment myelograms revealed a significant ($p < 0.05$) correlation between a marked-improvement response and a high probability of disk herniation (table 4). A satisfactory outcome was noted in 89.1% of those patients with higher probability of disk herniation but in only 68.0% of those with lower probability. Slightly better response rates were also noted in patients who had metrizamide myelography, larger disk herniations, lateral or centrolateral herniations, and a low probability of free disk fragments. These trends, however, were not statistically significant. Those patients who had definite, objective, myelographic evidence of nerve-root compression (root-sleeve amputation, nerve-root edema or flattening, nerve-root deviation) (figs. 1 and 2) had significantly

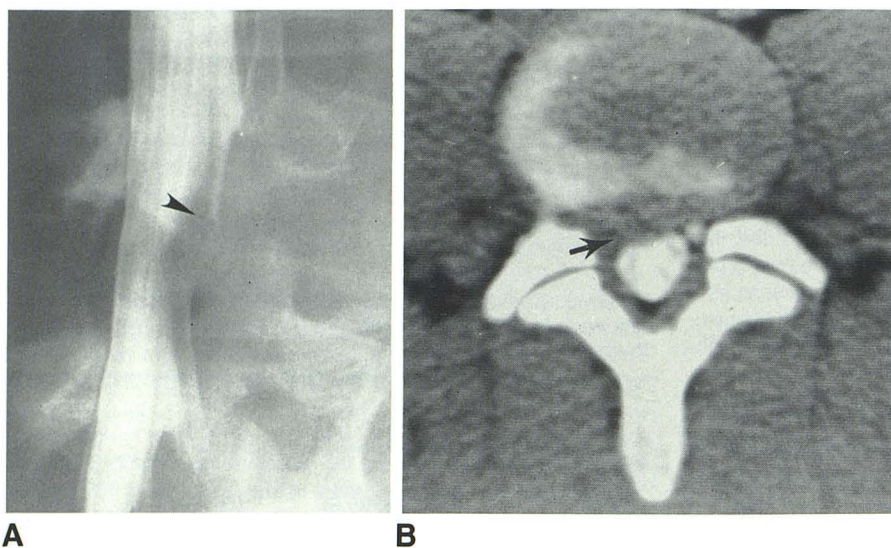


Fig. 1.—29-year-old man with probable L4–L5 disk herniation. Definite evidence of nerve-root compression. **A**, Oblique myelogram. Marked flattening and edema of right L5 nerve root (arrowhead) and amputation of its associated root sheath. **B**, CT scan. Lack of opacification of right L5 root sheath due to compression by disk material (arrow). Clinical response: asymptomatic at 6 month follow-up.

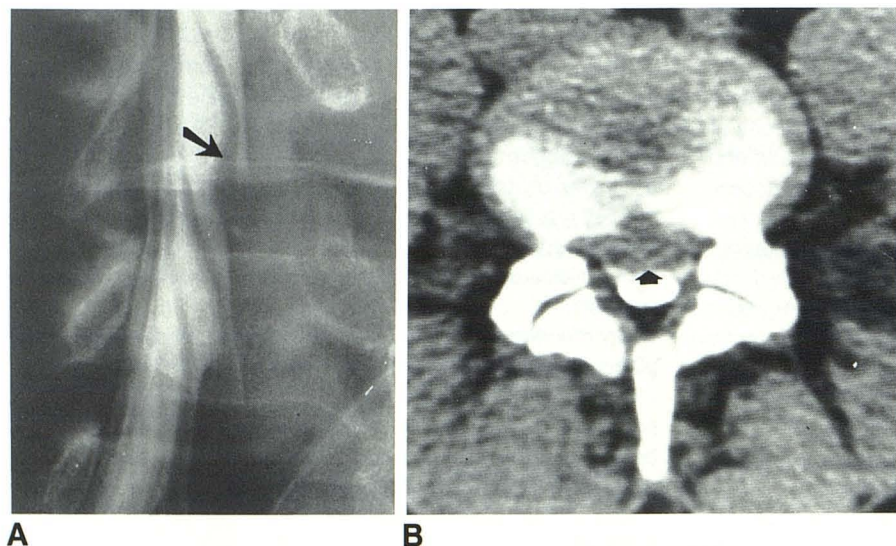


Fig. 2.—25-year-old man with probable L4–L5 disk herniation. **A**, Oblique myelogram. Evidence of significant nerve-root compression with amputation of right L5 root sheath and significant flattening of associated nerve root (arrow). **B**, Metrizamide-enhanced CT scan. Very large central and bilateral disk herniation causing posterior displacement of thecal sac (arrow) and posterolateral splaying of both L5 root sheaths. Clinical response: marked improvement of sciatica.

Fig. 3.—Two patients thought to have definite CT evidence of L4–S1 disk herniations resulting in significant nerve-root compression. **A**, Metrizamide-enhanced CT scan. L5–S1 disk herniation causes marked posterior displacement of right S1 root sheath (arrow). Clinical response: asymptomatic at 6 month follow-up. **B**, CT scan. Calcified L5–S1 disk herniation (arrow) causes compression of thecal sac and obliteration of epidural fat adjacent to left S1 root sheath. Clinical response: marked improvement.

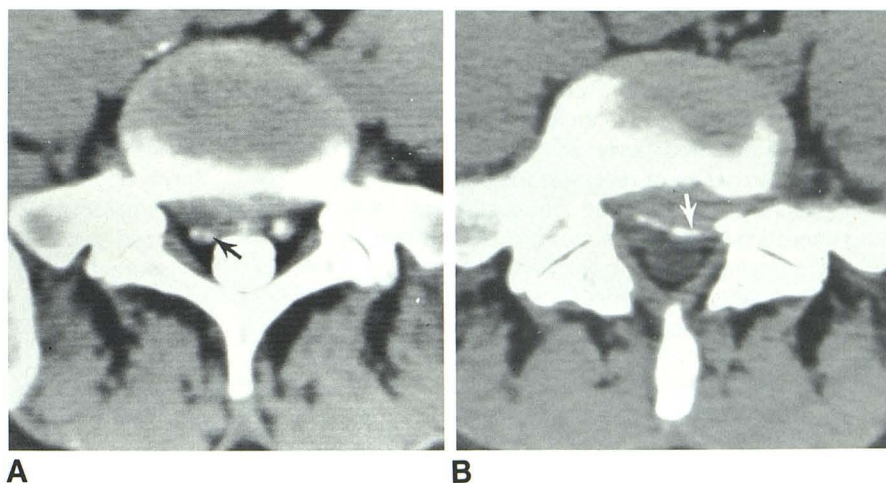
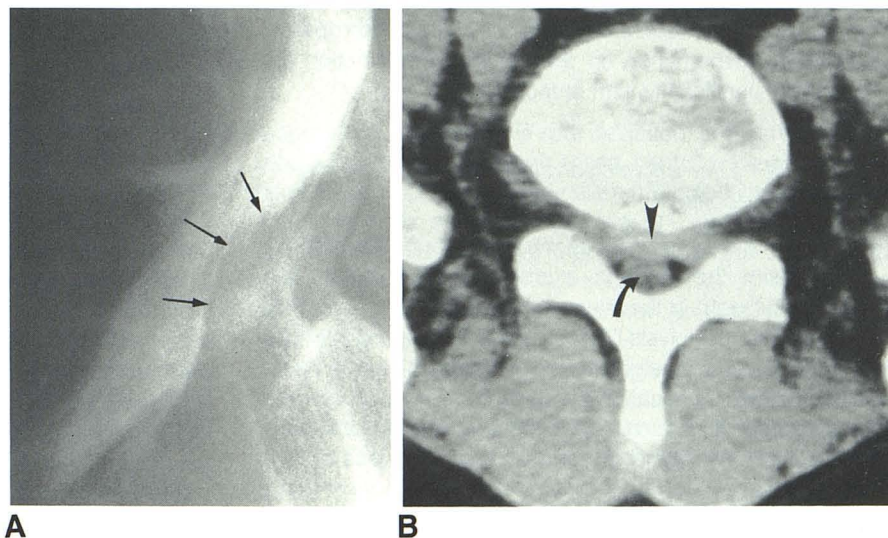


Fig. 4.—45-year-old man with unsuccessful chymopapain chemonucleolysis. Surgery confirmed L5–S1 disk herniation with free fragment 3 weeks after treatment. **A**, Myelogram. Extradural compression of thecal sac centered at L5–S1 interspace but extending above and below (arrows) level of disk space. **B**, CT scan confirms L5–S1 disk herniation (arrowhead) displacing thecal sac (arrow) posteriorly.



better response rates than those in whom such criteria were absent (table 4).

Eleven patients had myelographic findings suggestive of an extruded disk herniation [19, 22] with migration of disk fragments away from the interspace. The myelograms of these patients revealed extradural defects that extended substantially (1–2 cm) above or below the interspaces. In three patients, the extradural abnormalities were lobulated and laterally placed. Ten of these patients, however, had satisfactory therapeutic responses at follow-up. One patient required surgical discectomy 3 weeks after chemonucleolysis because of persistent pain, at which time a “free” disk fragment was identified.

A high probability of a disk herniation at CT was also significantly associated with a favorable clinical response. Satisfactory response to chemonucleolysis was noted in 88.7% of those patients thought to have a higher probability of disk herniation on CT (figs. 1–3), but only in 44.5% of those

with a lower probability of disk herniation ($p = 0.02$). The size, location, and attenuation value of the disk herniation had no observable relation to clinical response. The presence of associated facet arthropathy, vacuum phenomenon, chondrocalcinosis, calcification within the disk herniation, degenerative spondylosis, and spondylolisthesis did not significantly relate to the nature of clinical response.

Changes suggestive of free disk fragments [23, 24] were found in eight of the 34 patients who had CT scans. Each patient had evidence of disk herniation at the level of the interspace as well as a soft-tissue mass of disk density located from 5 mm to 1 cm above or below the interspace. In each case there was displacement of the thecal sac or root sheath. Only one of these eight patients had an unsatisfactory response to chemonucleolysis. In this patient an extruded disk herniation with a free fragment, remote from the interspace, was confirmed at surgery 3 weeks after treatment (fig. 4).

Diskography was of no value in predicting treatment response. Abnormalities were present in 99.0% of the disks injected with chymopapain. Protrusion of the annulus, leakage of contrast medium through an annular tear, and disk degeneration were detected easily, but their presence did not correlate with the nature of response to chemonucleolysis.

The height of each treated interspace was measured on the preinjection lateral spine radiographs and then correlated with the response. Disk height was measured as a ratio to allow correction for differences in magnification between sequential examinations. The disk height ratio (DHR) is defined as the ratio of the height of the disk at its midpoint, to the anteroposterior length of the vertebral body end-plate just above the disk space. Using this method, the mean L4–L5 preinjection DHR was found to be 0.30 ± 0.05 and that of L5–S1 was 0.25 ± 0.07 . The successful response rate was 91.1% when the L4–L5 and L5–S1 preinjection DHRs were larger than the mean and 80.0% when they were smaller than the mean ($p < 0.25$). The presence of degenerative osteophytosis, spondylolysis, chondrocalcinosis, facet arthropathy, and vacuum phenomenon on the baseline examination did not correlate significantly with response.

Correlation of Postchemonucleolysis Radiographic Studies and Clinical Responses

Postchemonucleolysis spinal radiographs were directly compared with the baseline examination to evaluate the change in the height of the injected interspace over time. Pre- and postchemonucleolysis DHRs were directly measured and the change in the disk height was expressed as a percentage. For each follow-up evaluation the patient was placed into one of three groups: (1) less than 5% loss of disk height; (2) 5%–15% loss of disk height; or (3) greater than 15% loss of disk height (table 5).

A significant loss of the height of the intervertebral disk was a common finding after chemonucleolysis. The degree of narrowing varied with time but became maximal at about 8 weeks after treatment. It was notable that a significant (>5%) loss of disk height occurred in 23.3% of patients after 1 week, 73.7% after 8 weeks, and 81.3% after 2–4 months. By 8 weeks, 47.4% of patients had lost at least 15% of their intervertebral height. Those patients with a loss of disk height of greater than 15% had a slightly better response rate than those with less severe interspace loss, but this difference was not statistically significant at early and late follow-ups.

TABLE 5: Temporal Changes in Disk Height after Chymopapain Chemonucleolysis

Time Period	% of Patients by Extent of Disk Height Loss		
	5%	5%–15%	>15%
<1 week ($n = 103$)	76.7	17.5	5.8
1–8 weeks ($n = 19$)	26.3	26.3	47.4
2–4 months ($n = 16$)	18.7	43.8	37.5
>4 months ($n = 38$)	36.8	30.0	34.2

Twenty patients (10.0%) had repeat myelography after chemonucleolysis. Nine patients were studied for persistent pain (1–9 months after chemonucleolysis); nine patients for recurrent pain (2–6 years), and two patients incidental to cervical myelography. In those patients with persistent pain, the myelogram was unchanged in six, the myelographic defect was smaller in one, and new abnormalities were found in two. In those patients studied for late recurrence of pain, the myelogram was unchanged in four, the myelographic defect had diminished in three, and new myelographic abnormalities were found in two. Both patients who had repeat lumbar myelography at the time of a cervical study had no change in the size of the myelographic defect, even though they had successful responses.

Radiographic Analysis of Treatment Failures

Twenty-one (10.5%) of the 200 patients treated with chymopapain chemonucleolysis had recurrent or persistent symptoms of sufficient severity to lead to surgical exploration 2 weeks to 6 years after chemonucleolysis.

Symptoms in 13 patients were not believed to have been caused by failure of chemonucleolysis. Six of these 13 did have disk herniations identified at surgery. Three patients had recurrent disk herniations after pain-free intervals of 2–6 years, two patients had new disk herniations at levels that had not been treated with chymopapain, and one patient had a new disk herniation causing sciatica in the opposite extremity. Seven patients who had surgical explorations did not have disk herniations. Two patients had lateral-recess stenosis, one had acquired central spinal stenosis, and one had a fusion for spinal instability. An arachnoid adhesion involving the symptomatic nerve root was found in one patient, and the cause of the sciatica remained undetermined in two patients.

Eight patients required surgery for persistent sciatica and were found to have disk herniations thought to be related to a failure of chemonucleolysis. In three of these cases, free disk fragments were found that had migrated away from the injected interspaces.

Discussion

Selection of Patients for Chemonucleolysis

Low-back pain and sciatica are among the most common disorders affecting people of the Western world. They occur, at some point, in the lives of 65–90% of this population [25, 26]. Since in 90% of instances the pain will subside within 2 months without specific treatment [27, 28], conservative therapy is considered to be the accepted initial method of treatment [26]. Some patients, however, may not obtain adequate pain relief with conservative measures and may require specific treatment to minimize morbidity and speed recovery.

The most specific and effective treatment of low-back pain and sciatica requires the determination of the pathologic process responsible. Just as surgical discectomy will not be effective in the treatment of all patients with back pain and

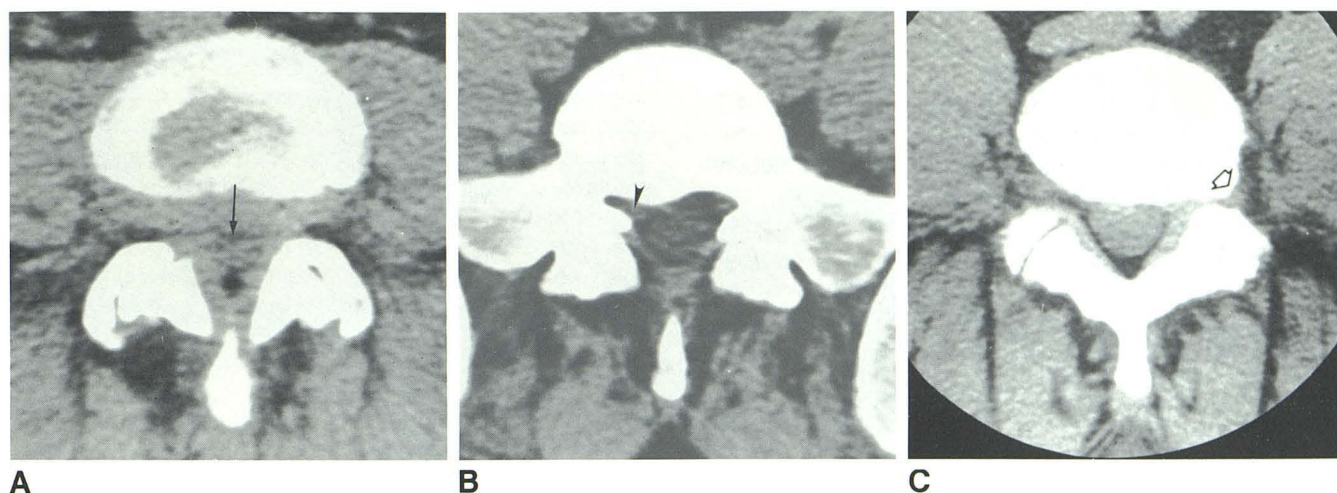


Fig. 5.—Three patients with unsuccessful chymopapain chemonucleolysis due to nonresponsive causes of nerve-root compression. **A**, Sciatica and compression of thecal sac (arrow) secondary to acquired central spinal steno-

sis. **B**, Lateral recess stenosis causing compression of right S1 root sheath (arrowhead). **C**, Foraminal stenosis due to osteophyte (arrow) displacing left L5 nerve root.

sciatica, chymopapain chemonucleolysis should not be considered a therapeutic panacea for all forms of this disorder. Indiscriminate use of chemonucleolysis can be expected to be met with suboptimal results, but careful selection of patients, by the optimization of all possible selection parameters, will achieve optimal results [2, 3, 14, 16]. Careful clinical selection of patients is known to improve the response rate for chemonucleolysis [2, 3, 14, 17]. Despite selection in this manner, however, many patients do not respond to treatment. Our data would indicate that the consideration of certain radiographic selection criteria may favorably enhance the response rates for chymopapain chemonucleolysis.

A definite radiographic diagnosis of a focal disk herniation, based on the objective CT and myelographic criteria outlined in this report, was significantly associated with a favorable outcome to chemonucleolysis. A significantly better outcome after chemonucleolysis was found in those patients with the highest probability of disk herniation on diagnostic evaluation with CT ($p = 0.02$), myelography ($p < 0.05$), or all radiographic studies available ($p < 0.001$). Since chymopapain chemonucleolysis is a specific therapeutic method for a specific disease process (focal disk herniation causing sciatica), it should not be surprising that best results are to be anticipated only in those patients likely to have a disk herniation.

Many previous studies [2, 13, 14, 16] have suggested that those patients with clinical evidence of nerve-root compression (dermatomal distribution of sciatic pain and neurologic deficit, reproduction of sciatic pain with straight leg raising) have significantly better response rates to chemonucleolysis than those without such evidence. Our data also suggest that those patients with definite radiographic evidence of nerve-root compression secondary to a disk herniation are most likely to benefit from chemonucleolysis. We found significantly better response rates for patients with specific signs of nerve-root compression on pretreatment myelograms (root-sleeve

amputation, marked nerve-root deviation, and nerve-root flattening or edema). Although these trends were also evident on analysis of CT scans, they were not statistically significant for the number of patients studied. CT was of great value, however, in substantiating that the nerve-root compression was by disk material and not secondary to other causes of nerve-root compression that are not responsive to chemonucleolysis (fig. 5).

It is of considerable interest, however, that chemonucleolysis was successful in a high percentage of patients believed to have a lower probability of disk herniation at myelography or CT. The high frequency of favorable responses in this group is most likely attributable to several factors. It is likely that some of these patients did indeed have disk herniations that were adequately treated with chymopapain chemonucleolysis. A number of patients may have had other causes of back pain that responded to additional conservative measures, rather than to any specific action of chymopapain. In addition to these factors, it is likely that a significant number of favorable responses were due to a placebo effect. Previous double-blind studies [4, 12, 13] comparing intradiskal injections of chymopapain and placebo have shown that 42%–57% of patients will respond to placebo injection alone.

Radiographic studies other than CT and myelography were of less value in the identification of patients likely to respond to chemonucleolysis. Although diskography was useful to verify the correct placement of the needle within the nucleus pulposus and to confirm that the disk was abnormal, it was of little additional value. We found diskography to be nonspecific and unreliable, if used alone, in the selection of patients for chemonucleolysis. We were unable to obtain valid prognostic information regarding the nature of clinical response on the basis of diskographic characteristics. Those patients with disk spaces greater in height (than the mean of all injected interspaces) had better response rates.

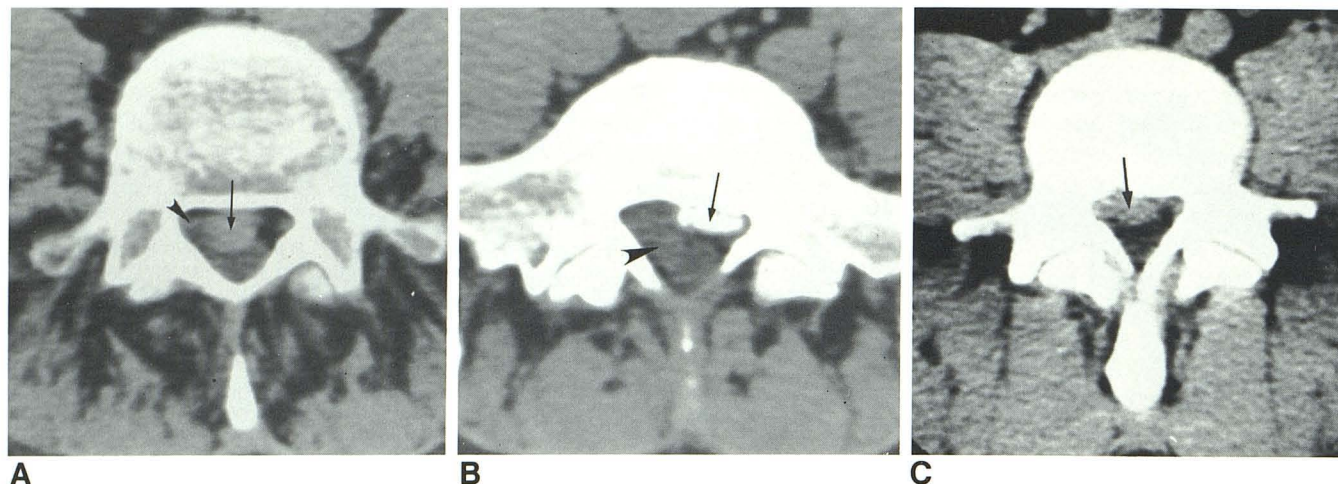


Fig. 6.—Three patients with probable sequestered disk fragments. Each patient had satisfactory response to chemonucleolysis. A, L4–L5 disk herniation and probable free fragment (arrow) causing compression of thecal sac and right L5 root sheath (arrowhead). B, Old calcified left L5–S1 disk herniation

(arrow) now with right-sided sciatica due to large fragment of disk material (arrowhead) interposed between right S1 root sheath and thecal sac. C, L4–L5 disk herniation and large fragment of disk material (arrow) substantially below interspace.

Analysis of Chemonucleolysis Failures

Eight patients (4.0%) in our study population had surgically confirmed disk herniations that were thought to be secondary to chemonucleolysis failure. Five chemonucleolysis failures were apparently secondary to unresponsive simple disk herniations. It is not certain from our analysis whether this unresponsiveness was due to inactive enzyme, inadequate exposure of the disk material to the enzyme, or resistance of the disk material to the enzyme's action. Three patients with chemonucleolysis failure had surgically confirmed free disk fragments that had migrated away from the injected interspace. The most likely explanation for therapeutic failure in these instances is inadequate exposure of these fragments to active enzyme.

We found it interesting that a number of patients, with myelographic and CT evidence [19, 22–24] of extruded disk herniations with probable free fragments, had a satisfactory response to chemonucleolysis (fig. 6). We cannot be certain why some patients with apparent free disk fragments remote from the treated interspaces respond to chemonucleolysis. In some instances active enzyme may reach the disk material and provide pain relief through direct action by chymopapain. Another possibility is postchemonucleolysis migration of the sequestered disk fragment with a reduction in nerve-root compression. It may be possible that there are other indirect effects of chymopapain that lead to a reduction of nerve-root compression [14, 29]. In view of the high frequency of sequestered disk fragments in patients with chemonucleolysis failure, in our series as well as in others [14–17, 19–20], it is likely that the response rate for treatment of this group of patients will be less favorable.

Our series and others [14–17, 19, 20] suggest that nerve-root compression from causes other than disk herniation is a common reason for chemonucleolysis failure. We found CT to be of specific value in excluding causes of nerve-root

compression unresponsive to chemonucleolysis. Accurate pretreatment radiographic evaluation could prevent treatment of patients with nerve-root compression secondary to central spinal stenosis (fig. 5A), lateral recess stenosis (fig. 5B), and foraminal stenosis (fig. 5C).

Prechemonucleolysis diagnostic studies of many patients in our series not responding to chymopapain chemonucleolysis revealed only equivocal changes without convincing evidence of disk herniation or nerve-root compression. Our impression is similar to that of others, who, on the basis of a much smaller series, found that chemonucleolysis failure appears to be common among those who had ill-defined clinical and radiologic signs of nerve-root compression [15].

From analysis of the apparent causes of chemonucleolysis failure in our operative series, it is evident that most patients (76.2%) had a definable and potentially preventable reason for failure. A more precise radiographic diagnosis, or more reliance on the radiographic findings, could have prevented the use of chymopapain chemonucleolysis in all of the patients who required surgical intervention, except for five patients with unresponsive simple disk herniations (2.5% of the treated patients).

Temporal Radiographic Changes after Chemonucleolysis

The most common morphologic change noted after chemonucleolysis was a progressive decrease in the disk height on follow-up spine films. Although there was a slightly better response in those patients with greater loss of disk height, the degree of interspace narrowing after chemonucleolysis had no statistically significant association with the response rate. Other authors [18] have found, however, significantly higher response rates for those patients exhibiting marked interspace narrowing after chemonucleolysis.

A decrease in the size of the myelographic defect after

chemonucleolysis was uncommon in those patients studied for persistent pain (11.1%) and in those studied with recurrent pain (33.3%). A lack of change in the size of the disk herniation, in patients who become symptom-free, has also been observed by others [19], including MacNab et al. [14], who used postchemonucleolysis myelography to evaluate changes in the size of the disk herniation in 10 symptom-free patients. Our study did not directly address the reasons why a satisfactory response may occur without a change in the degree of disk protrusion. This is the subject of another report [29].

Conclusions

Our data indicate that, in a properly selected group of patients with low-back pain and sciatica, chymopapain chemonucleolysis provides effective treatment. From analysis of our data and a review of the literature, we offer a number of guidelines to assist in maximizing response rates to chymopapain chemonucleolysis:

1. The technical performance of the procedure must be such that active chymopapain is introduced into the nucleus pulposus of the correct intervertebral disk. We found, in this regard, that diskography with filming in at least two projections is essential to ensure accurate placement of chymopapain.

2. Demographic factors, such as a prior laminectomy or a pending workers' compensation claim, may influence response rates. Although it may not be justified to withhold a potentially effective therapeutic method on the basis of these factors alone, it is apparent that lower response rates are to be expected in these groups.

3. Careful clinical selection of patients for treatment on the basis of objective evidence of nerve-root compression on neurological examination is accompanied by higher response rates.

4. Careful selection of patients on the basis of certain radiographic variables may influence response rates to chemonucleolysis. Major radiographic factors associated with favorable responses include a certain radiographic diagnosis of focal disk herniation, the presence of objective radiographic evidence of nerve-root compression by disk material, and a wide preinjection disk height.

5. Most causes of chemonucleolysis failure are potentially preventable and usually are attributable to the presence of extruded disk herniations with migration of free fragments away from the treated interspace; the presence of other causes of nerve-root compression (central spinal stenosis, lateral recess stenosis, foraminal stenosis); or treatment of unresponsive causes of back pain (degenerative disk disease, symmetrically bulging disk without focal herniation, facet arthropathy, instability syndromes, or neoplastic bone pain).

We believe that, in the properly selected patient who has objective clinical and radiographic evidence of nerve-root compression secondary to focal disk herniation, chymopapain chemonucleolysis is a safe and economical alternative to surgical discectomy, with similar response rates. Proper guidelines for patient selection, however, are necessary to ensure maximum response to treatment.

ACKNOWLEDGMENTS

We thank Shirley Wickum and Marla Leuty for manuscript preparation.

REFERENCES

1. Smith L. Enzyme dissolution of the nucleus pulposus in humans. *JAMA* **1964**;187:137-140
2. Javid MJ. Treatment of herniated lumbar disc syndrome with chymopapain. *JAMA* **1980**;243:2043-2048
3. Wiltse LL. Chemonucleolysis in the treatment of lumbar disc disease. *Orthop Clin North Am* **1983**;14:605-622
4. Schwetschenau PR, Ramirez A, Johnston J, Wiggs C, Martins AN. Double-blind evaluation of intradiscal chymopapain for herniated lumbar disc: early results. *J Neurosurg* **1976**;45:622-627
5. Schneider RC. Position statement on chymopapain from the American Association of Neurological Surgeons. *J Neurosurg* **1975**;42:373-375
6. Sussman B. Chymopapain, chemonucleolysis in lumbar disc disease. *JAMA* **1975**;234:271-272
7. Sussman B. Inadequacies and hazards of chymopapain injections as treatment for intervertebral disc disease. *J Neurosurg* **1975**; 42:389-396
8. Shealy CN. Dangers of spinal injections without proper diagnosis. *JAMA* **1966**;197:1104-1107
9. Massaro TA, Javid M. Chemonucleolysis. *J Neurosurg* **1977**;46:696-697
10. Brown MD, Daroff R. The double blind study comparing Discase to placebo—an editorial comment. *Spine* **1977**;2:233
11. Nordby EJ, Brown MD. Present status of chymopapain and chemonucleolysis. *Clin Orthop* **1977**;129:79-83
12. Javid MJ, Nordby EJ, Ford LT, et al. Safety and efficacy of chymopapain (Chymodiactin) in herniated nucleus pulposus with sciatica: results of a randomized, double-blind study. *JAMA* **1983**;249:2489-2494
13. Fraser RD. Chymopapain for the treatment of intervertebral disc herniation: a preliminary report of a double-blind study. *Spine* **1982**;7:608-612
14. MacNab I, McCulloch JR, Weiner DS, Hugo EP, Galway RD, Dall D. Chemonucleolysis. *Can J Surg* **1971**;14:280-289
15. Rarichandran G, Mulholland RC. Chymopapain chemonucleolysis: a preliminary report. *Spine* **1980**;5:380-384
16. McCulloch JA. Chemonucleolysis. *J Bone Joint Surg [Br]* **1977**;59:45-52
17. Onofrio BM. Injection of chymopapain into intervertebral disc: preliminary report on 72 patients with symptoms of disc disease. *J Neurosurg* **1975**;42:384-388
18. Bitz MD, Ford LT. An evaluation of narrowing following intradiscal injection of chymopapain. *Clin Orthop* **1977**;129:191-195
19. Benoist M, Deburge A, Heripret G, Busson J, Rigot J, Cauchoix J. Treatment of lumbar disc herniation by chymopapain chemonucleolysis: a report on 120 patients. *Spine* **1982**;7:613-617
20. Drouillard J, LaVignolle B, Philippe JC, et al. Scanographie et chemonucleolyse des hernies discales. *J Radiol* **1982**;63:267-272
21. Kieffer SA, Sherry RG, Wellenstein DE, King RB. Bulging lumbar intervertebral disk: myelographic differentiation from herniated disk with nerve root compression. *AJNR* **1982**;3:51-58, *AJR* **1982**;138:709-716
22. Shapiro R. *Myelography*. Chicago: Year Book, **1975**:348-412
23. Williams AL, Haughton VM. Disc herniation and degenerative disc disease. In: Newton TH, Potts DG, eds. *Modern neuroradiology. Computed tomography of the spine and spinal cord*, vol. 1. San Anselmo, CA: Clavadel, **1983**:231-250

24. Dillon WP, Kaseff LG, Knackstedt VE, Osborn AG. Computed tomography and differential diagnosis of the extruded lumbar disc. *J Comput Assist Tomogr* **1983**;7:969-975
25. Kelsey JL. Epidemiology: natural course of the disease. In: White AA, Gordon SL, eds. *American Academy of Orthopaedic Surgeons: symposium on idiopathic low back pain*. St. Louis: Mosby, **1982**:1-8
26. Davis CH Jr. Extradural spinal cord and nerve root compression from benign lesions of the lumbar area. In: Youmans JR, ed. *Neurological surgery*, vol 4. Philadelphia: Saunders, **1982**:2535-2561
27. Nachemson AL. The natural course of low back pain. In: White AA, Gordon SL, eds. *American Academy of Orthopaedic Surgeons: symposium on idiopathic low back pain*. St. Louis: Mosby, **1982**:46-51
28. Bywaters EG. The pathological anatomy of idiopathic low back pain. In: White AA, Gordon SL, eds. *American Academy of Orthopaedic Surgeons: symposium on idiopathic low back pain*. St. Louis: Mosby, **1982**:46-51
29. Gentry LR, Turski PA, Strother CM, Javid MJ, Sackett JF. Chymopapain chemonucleolysis: temporal CT changes after treatment. *AJNR* **1985**;6:321-329, *AJR* **1985**;145 (in press)