



## Get Clarity On Generics

Cost-Effective CT & MRI Contrast Agents



FRESENIUS  
KABI

WATCH VIDEO

# AJNR

## Magnetic resonance imaging in multiple sclerosis: results in 32 cases.

J A Jackson, D R Leake, N J Schneiders, L A Rolak, G R Kelley, J J Ford, S H Appel and R N Bryan

*AJNR Am J Neuroradiol* 1985, 6 (2) 171-176

<http://www.ajnr.org/content/6/2/171>

This information is current as  
of August 13, 2025.

# Magnetic Resonance Imaging in Multiple Sclerosis: Results in 32 Cases

J. A. Jackson<sup>1,2</sup>  
 D. R. Leake<sup>3</sup>  
 N. J. Schneiders<sup>1</sup>  
 L. A. Rolak<sup>2</sup>  
 G. R. Kelley<sup>4</sup>  
 J. J. Ford<sup>1</sup>  
 S. H. Appel<sup>2</sup>  
 R. N. Bryan<sup>1</sup>

A prospective clinical study was performed in 32 patients with multiple sclerosis (MS) to evaluate the sensitivity of lesion detection and accuracy of lesion localization by neurologic examination, delayed enhanced computed tomography (CT) with a double dose of contrast material, and proton magnetic resonance (MR) imaging. After neurologic examination patients were classified by probability of MS (possible, four patients; probable, three patients; and definite, 25 patients) and by disease activity (acute, chronic with acute exacerbation, or chronic progressive). Subsequently they underwent delayed enhanced CT scanning and MR imaging with more than one spin-echo technique. In five of seven patients with possible or probable MS, both MR imaging and delayed enhanced CT were negative. In 25 cases of definite MS, MR imaging detected pathology in 19 (76%) cases, while CT detected lesions in 15 (60%) of 25 cases. In acute lesions (acute or chronic with acute exacerbation), the two techniques were of similar sensitivity (delayed CT was positive in 65% and MR imaging in 60%), while in chronic progressive MS, MR imaging was superior in lesion detection (MR imaging positive in 75%; delayed CT in 25%). While most lesions (55%) were seen in corresponding locations in both studies, neither MR nor delayed CT correlated well with lesion localization by neurologic examination because a large number of asymptomatic lesions were imaged and many symptomatic lesions were undetected. MS plaques imaged by MR were manifested by prolongation of T2 and were of two varieties: focal, acute lesions (T2 136–260 msec at 0.14 T) and chronic, diffuse, predominantly periventricular lesions (120–231 msec T2 at 0.14 T, normal white matter T2 of 77–118 msec at 0.14 T). Because of these overlapping ranges, chronicity of MS lesions could not be determined by T2 values alone. MR was at least as sensitive as delayed CT in lesion detection, and it was more sensitive in detecting chronic MS plaques. MR imaging is a viable alternative to double-dose delayed CT in the evaluation of patients with MS, particularly in patients in whom intravenous contrast agents are prohibited or unrevealing.

Received May 16, 1984; accepted after revision September 12, 1984.

Presented in part at the annual meeting of the American Society of Neuroradiology, San Francisco, June 1983.

This work was supported in part by U.S. Public Health Service grant NS 19056.

<sup>1</sup>Department of Radiology, Baylor College of Medicine, 1200 Moursund Ave., Houston, TX 77030. Address reprint requests to J. A. Jackson.

<sup>2</sup>Department of Neurology, Baylor College of Medicine, Houston, TX 77030.

<sup>3</sup>Department of Radiology, Brackenridge Hospital, Austin, TX 79701.

<sup>4</sup>Neurology Consultants, Overland Park, KS 66211.

**AJNR 6:171–176, March/April 1985**

0195–6108/85/0602–0171

© American Roentgen Ray Society

Multiple sclerosis (MS) is a chronic relapsing inflammatory disease of central nervous system myelin (white matter) that afflicts over 250,000 Americans and is the most common disabling neurologic disease of young adults [1]. Its clinical course is characterized by acute, transient attacks of focal neurologic dysfunction (demyelination) that, after repeated attacks, result in permanent white-matter damage and chronic disability [2]. Because its symptoms are variable and often transient, early diagnosis poses a serious challenge to the clinician. The diagnosis of MS depends on the demonstration by history, physical examination, and laboratory evaluation of multifocal acute and chronic inflammatory lesions (called plaques) within the central nervous system. Computed tomographic (CT) imaging of plaques has proven to be an important diagnostic tool in MS, yet conventional examinations are positive in only 13%–49% of definite, 11%–20% of probable, and 0–22% of possible MS cases [3–8]. Double-dose delayed CT and magnetic resonance (MR) imaging are two innovative approaches that have increased the sensitivity of MS diagnosis [9–22]. As compared with routine contrast-enhanced CT, delayed enhanced CT may triple or quadruple the number of detected lesions, while MR imaging has detected five to 12 times the number of demyelinating

lesions, the extent of which appear to be better delineated by spin-echo (SE) imaging than by inversion-recovery imaging [10-17, 20]. To date, however, no study has compared delayed enhanced CT with MR imaging to determine whether the same population of lesions is being detected or whether lesions missed by one technique are detected by the other. Our present report details data comparing delayed CT with SE imaging in 32 patients with possible, probable, and definite MS. Although neither method correlated well with lesion localization by neurologic examination and neither depicted posterior fossa lesions well, MR imaging was as sensitive as delayed CT in documenting acute demyelination and more sensitive in detecting chronic demyelination.

## Subjects and Methods

### Patient Population

Forty-five MS patients referred from public and private hospitals to the Baylor College of Medicine NMR Laboratory between March 1983 and March 1984 constituted the study population. Thirteen of these were excluded: 11 were ultimately determined to have a diagnosis other than MS, and two, one with possible MS and another with definite MS, had inadequate MR data. The other 32 patients are reported here.

All patients had a complete neurologic history and physical examination by a neurologist involved in the study. On the basis of this examination, the patients were classified as possible MS (four patients), probable MS (three patients), or definite MS (25 patients) by the criteria of McAlpine et al. [23]. The 11 men and 21 women were 23-66 years old and had disease durations ranging from a few days to 30 years. The temporal course of each patient's disease was also defined as either acute (a discrete attack with no underlying chronic disability), chronic with acute exacerbation (underlying chronic disability currently having an attack), or chronic progressive (slowly progressive chronic disability with no recent attack). The neurologist also indicated the anatomic site of clinical lesions so that the clinical localization could be compared with delayed CT and MR localization. After the neurologic examination, each patient underwent proton MR imaging and delayed enhanced CT scanning; these were performed as close together as possible, usually within 24 hr.

### CT Scanning

CT scanning was performed on a Philips 310 scanner. Each sequence comprised 10 contiguous, 9-mm-thick slices, and was performed 1 hr after intravenous administration of iodinated contrast material (Vascoray, 80 g I/200 ml). The images were reviewed by two neuroradiologists for focal or diffuse areas of abnormally increased or decreased attenuation or contrast enhancement. Atrophic changes were also noted but were not considered definitive in the diagnosis of MS.

### MR Imaging

All proton MR images were obtained using a Bruker whole-body imaging system consisting of a 0.14 T air-core resistive magnet operating at a proton resonant frequency of 6 MHz and controlled by a modified CXP console. Images were collected using a modified Carr-Purcell-Meiboom-Gill (CPMG) pulse sequence. The slice selection radiofrequency pulse was designed to leave the spins within an approximately 1-cm-thick slice unexcited, while spins outside the slice were saturated. Slice selection was followed by the CPMG sequence of a 90° pulse and 16 180° pulses spaced by 9 msec (9

msec echo time [TE] and about 1200 msec repetition time [TR]). Each 180° pulse produced an SE that was a projection through the slice. Our slice selection technique results in the summation of two sets of 16 echoes for each of 120 projections at 1.5° increments, covering a total angle of 180° degrees. Each set of 16 SEs decays in intensity due to spin-spin or T2 relaxation effects. Thus, it would have been possible to reconstruct a sequence of 16 images reflecting T2 decay. However, to improve the signal-to-noise ratio, sequential SEs were averaged in groups of four, resulting in a sequence of four T2-dependent images (effective 22.6, 58.8, 94.9, and 131.1 msec TEs). Reconstruction was of a 253<sup>2</sup> pixel matrix using a standard convolution-filtered back-projection algorithm. For each patient, data were collected for a minimum of six slices.

Using the sequence of four T2-dependent images, calculated T2 and initial signal strength images were generated by following the technique described by Schneiders et al. [24]. Briefly, corresponding pixels from the four images were semilogarithmically plotted versus time and a least-squares-fit straight line was calculated. The slope and y intercept are related to T2 and initial signal strength, respectively, of the tissue represented by that pixel. The initial signal strength image is related to the extrapolated intensity of the signal at the time of the initial 90° pulse. Thus, this value should be independent of T2, containing only information about spin density and T1 (from TR-related partial saturation). When T2 values have been calculated for each pixel in this manner, the values may be assigned to a gray scale and a T2 image reconstructed. This method has been shown to produce calculated T2 images that are accurate to better than 9% [24]. The images were reviewed by two neuroradiologists for areas of focal or diffuse increase in T2. Region-of-interest T2 values were extracted from calculated T2 patient images as an average value over a 3 × 3 pixel area and were compared with similarly extracted T2 values from normal volunteers.

## Results

Table 1 reveals that in two patients with probable MS and three patients with possible MS, both MR imaging and de-

TABLE 1: Comparison of CT and MR Imaging in the Evaluation of Multiple Sclerosis

Type of Multiple Sclerosis	No. of Patients				
	Total	+MR/ +CT	+MR/ -CT	-MR/ -CT	-MR/ +CT
<b>Definite:</b>					
Acute	4	2	0	1	1
Chronic with acute exacerbation	13	9	0	4	0
Chronic progressive	8	3	5	0	0
Subtotal	25	14	5	5	1
<b>Probable:</b>					
Acute	0	0	0	0	0
Chronic with acute exacerbation	1	0	0	1	0
Chronic progressive	2	0	1	1	0
Subtotal	3	0	1	2	0
<b>Possible:</b>					
Acute	1	1	0	0	0
Chronic with acute exacerbation	1	0	0	1	0
Chronic progressive	2	0	0	2	0
Subtotal	4	1	0	3	0
<b>Total</b>	<b>32</b>	<b>15</b>	<b>6</b>	<b>10</b>	<b>1</b>

layed CT were negative. In one patient with possible MS, both delayed CT and MR imaging were positive, and in one patient with probable MS, MR imaging was positive while delayed CT was negative. Of 25 patients with definite MS, five had negative MR images and delayed CT studies, five had positive MR images but negative delayed CT scans, and only one patient had a negative MR study but a positive delayed CT scan. The other 14 patients had positive MR and delayed CT studies.

Calculated T2 values for normal white matter from a population of normal volunteers at the Baylor facility were 77–118 msec. Nonenhancing plaques on delayed CT scans, thought to represent more chronic lesions, had calculated T2 values on MR images of 120–231 msec. Enhancing plaques on delayed CT scans, thought to be more acute lesions, had T2 values of 136–260 msec. These data show no definite

distinction by MR between acute (enhancing) plaques and chronic (nonenhancing) plaques.

As with other studies reported, most pathology was seen in the periventricular areas on MR images [12–20]. However, plaques were seen in the white matter throughout the neuroaxis in certain patients. Of the 76 lesions imaged by either MR or delayed CT, 42 (55%) were seen in corresponding locations in both studies (21 by each study), 19 (25%) were depicted only on MR images, and 15 (20%) were seen only on delayed CT images. Thus, while most lesions were detected by both techniques, each depicted lesions not seen by the other techniques.

There was very poor correlation between neurologic examination and delayed CT and MR imaging with respect to lesion localization. Most clinically detected lesions were in the posterior fossa (66 of 142 predicted lesions), spinal cord (26

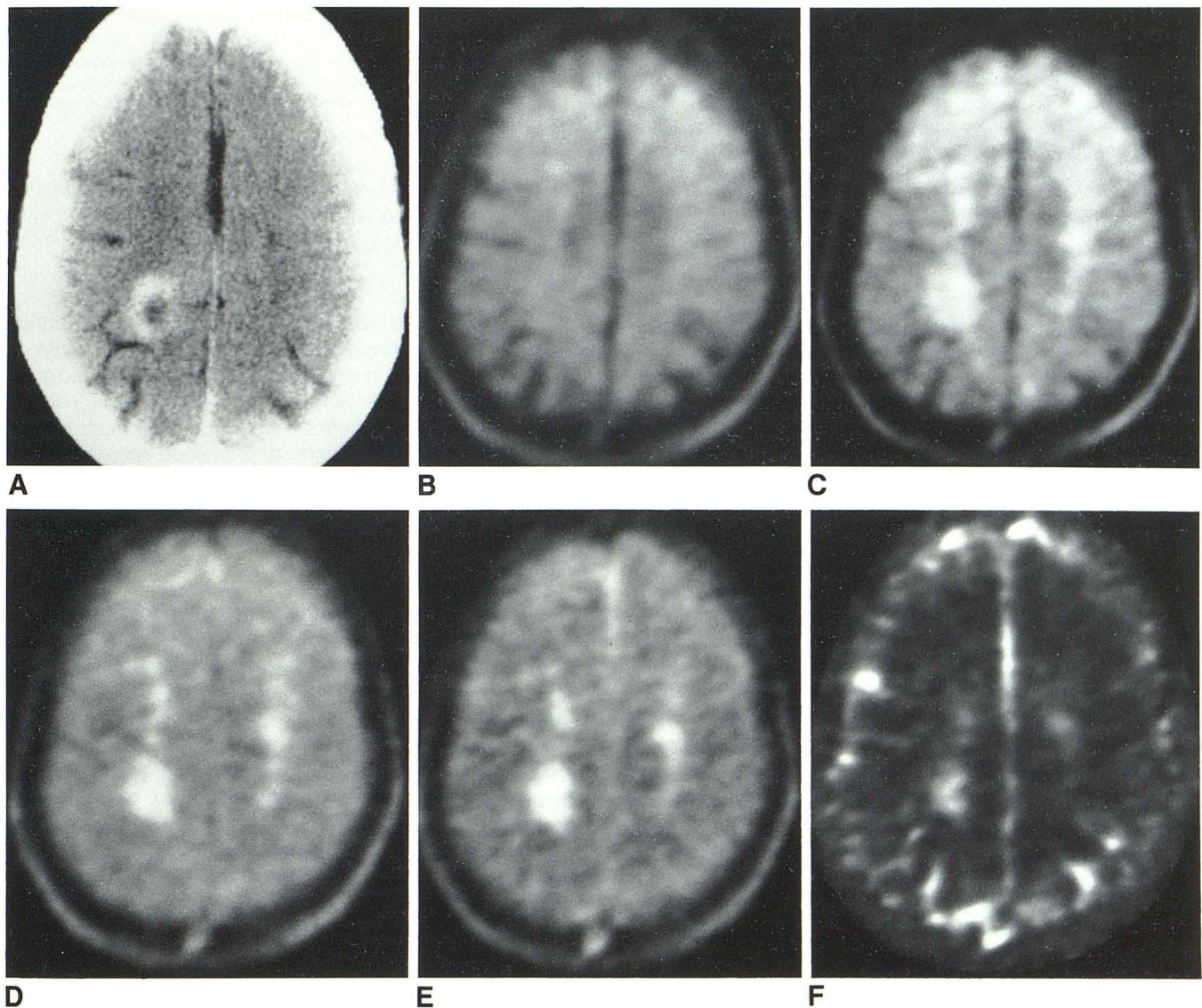


Fig. 1.—Focal and diffuse plaques, standard imaging format (duration of illness: 20 years). A, Delayed enhanced CT scan. Ring-enhancing lesion in right parietal lobe. B–E, CPMG images (from summing 16 SEs into four groups of four, thus generating four CPMG images with effective 22.6 [B], 58.8 [C], 94.9

[D], and 131.1 [E] msec TEs). Extensive prolongation of T2 in centrum semiovale bilaterally. F, Calculated T2 image (T2 of right parietal focus, 210–231 msec; T2 of diffuse white-matter demyelination, 142–196 msec).

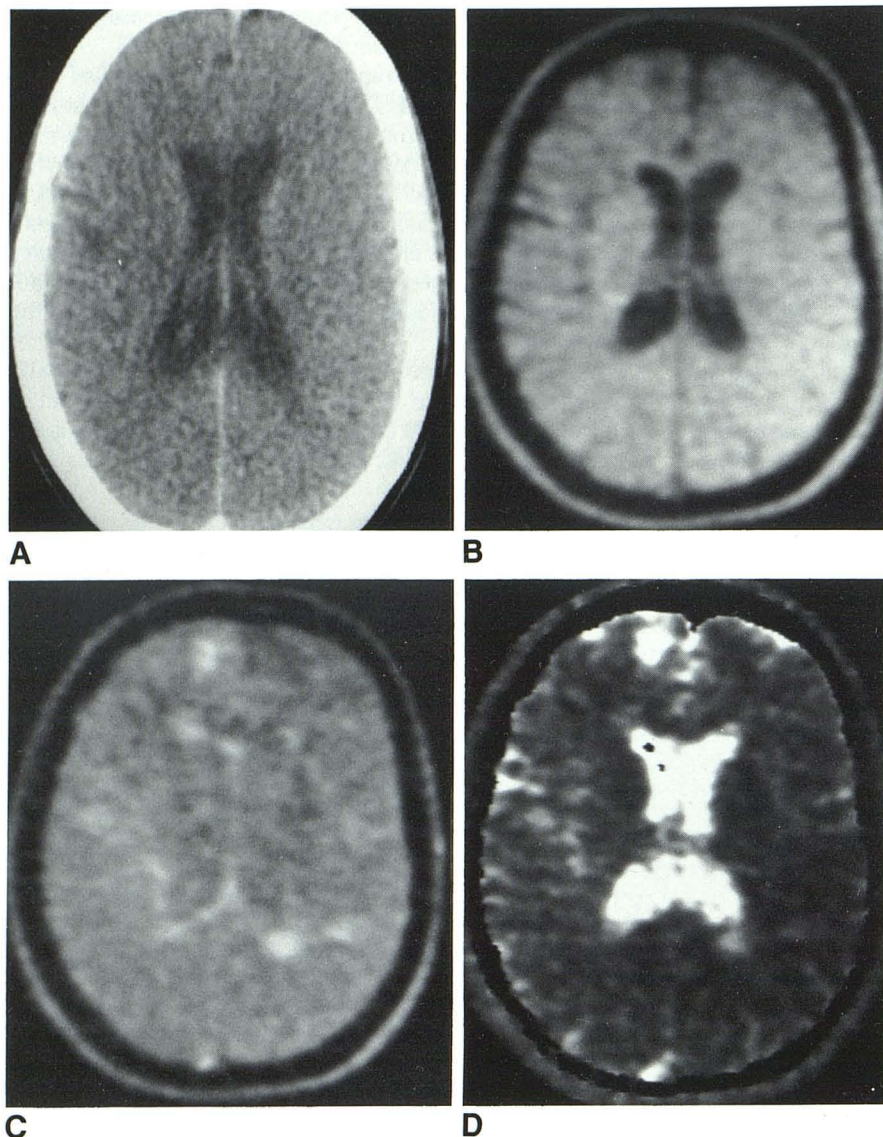


Fig. 2.—Multiple focal and periventricular plaques (duration of disease: 28 months). **A**, Delayed enhanced CT image. No significant abnormality. **B**, Early CPMG image (effective 22.6 msec TE). **C**, Late CPMG image (sum of SEs 9–16, effective 113 msec TE). **D**, Calculated T2 image. Diffuse focal and periventricular plaques manifested as prolongation of T2 (T2 of focal plaques, 139–147 msec; T2 of periventricular plaques, 198–230 msec).

of 142 predicted lesions), or optic nerves (24 of 142 predicted lesions). However, MR imaging detected only three and delayed CT only one lesion in the posterior fossa. Neither technique adequately examined the spinal cord or the optic nerves. Of the 142 lesions predicted by neurologic examination, only 22 seen on MR images (20 in the cerebral hemispheres) and 14 seen on delayed CT images (13 in the cerebral hemispheres) correlated with clinical predictions. Both techniques did, however, demonstrate a number of asymptomatic lesions (18 detected by MR imaging, 22 detected by delayed CT), predominantly in the cerebral hemispheres. Examples are shown in figures 1–3.

#### Discussion

Table 1 reveals that in all but one patient with possible or probable MS, when CT scans were negative, MR images were negative as well. Of 25 patients with definite MS, six had negative MR studies. In one patient with acute definite MS, the CT scan revealed a right parietal enhancing lesion.

However, a slice through this area was not obtained with MR, and thus this patient's study was considered negative due to sampling error. In the other five definite MS patients with negative MR studies, all had only posterior fossa lesions, spinal cord lesions, optic nerve lesions, or combinations of these.

Posterior fossa lesions are infrequently noted by MR imaging, although the yield is greater than by CT [12, 22, 25]. Only 20% of MS plaques are found in the posterior fossa at autopsy, reducing the potential yield of imageable plaques [2]. Lesions in this region need to be only a few millimeters or less to produce significant symptoms, and because of bone artifact on CT [4] and partial-volume effects on MR imaging, these small lesions can be obscured on the image. Axial spatial resolution at clinical contrast levels is about 2.5 mm on our MR unit, and spatial sampling is further limited by the relatively large slice thickness and possibly still undefined irregularities in MR slice configuration. As such, only three patients in our series had posterior fossa lesions visible on

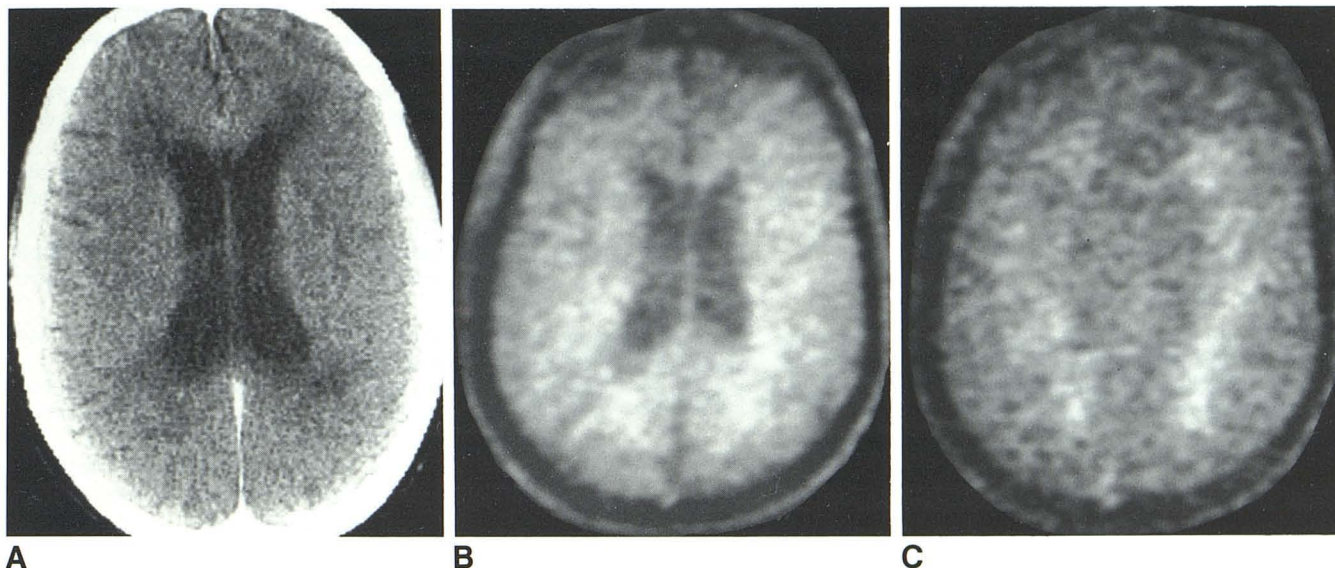


Fig. 3.—Diffuse end-stage chronic plaques. **A**, Delayed enhanced CT scan. Diffuse, bilateral, nonenhancing, low-density lesions in white matter. (Moderately severe atrophy in this patient is not seen here.) **B**, Early CPMG image

(sum of SEs 1–8; effective TE, 40.7 msec). **C**, Late CPMG image (sum of SEs 9–16; effective TE, 113 msec). Severe and diffuse prolongation of T2 throughout white matter (209–231 msec T2).

MR imaging, while 25 (78%) had pathology referable to this area by neurologic examination; this is similar to the findings of other investigators [25]. As the spinal cord was not imaged routinely in our standard head study, these lesions were missed because of sampling error. To date, no report has been published of a demyelinating optic nerve lesion imaged by MR. This was true for all 15 patients in our study who had optic neuritis. Because the optic nerve is tortuous in its course and is surrounded by fat, which has a T2 that overlaps the normal brain and MS plaque ranges, partial-volume effects make detection of demyelination difficult in this region.

The clinical examination thus correlated poorly with the distribution of lesions seen on both delayed CT and MR studies in our patient population, as has been noted by others [11, 21, 25]. This reflects both a large number of asymptomatic lesions imaged as well as many symptomatic lesions undetected because of small size, unexamined region (spinal cord), and/or technical limitations. The discrepancy between the small number of lesions (20%) found at autopsy in the posterior fossa [2] as compared with the large number (66 [46%] of 142) predicted clinically contributes to the poor correlation between the clinical and imaging examinations, reflecting the difficulty in clinical anatomic assignment when more than one lesion is present.

The sensitivity of lesion detection by MR imaging is obviously related to image quality. The prototype resistive 6 MHz system used in our study has a lower signal-to-noise ratio and other technically limiting factors when compared with newer equipment. More refined instruments might well be more sensitive in detecting lesions, particularly small ones. However, even with this prototype imager, MS lesions are detected more often than with state-of-the-art CT techniques.

Although the small size of our patient population diminished the significance of some of our conclusions, certain trends became apparent when patients were divided into acute

lesions (acute and chronic with acute exacerbation) versus chronic lesions (table 2). Of 20 patients with acute or chronic exacerbating MS, 13 (65%) had abnormalities consistent with MS on delayed CT scans as compared with 12 (60%) who had abnormalities on MR studies. Thus, for the acute lesion, the two studies appeared to be comparable in sensitivity in detecting demyelination. In the chronic group, however, delayed CT revealed pathology in only three of 12 patients, while MR revealed abnormalities in the rest, nine of 12 patients. Among all 32 patients, delayed CT documented lesions in 16 (50%), while MR imaging demonstrated pathology in 21 (65.6%). Thus, MR was at least as sensitive as delayed CT in detecting MS plaques, and was superior in defining chronic demyelinating plaques.

The prolongation of T2 in areas of demyelination in our series corroborates previous reports [13–20]. The calculated T2 values of plaques of about 120–260 msec at 0.15 T agrees well with the findings of Bailes et al. [13], despite differences in the calculation algorithms used at the two centers. Two patterns of demyelination were identified in this patient population: focal lesions, believed to represent more acute lesions that correlated with enhancing lesions on delayed CT, and diffuse, periventricular lesions, believed to represent more chronic postdemyelinative scar tissue. However, calculated T2 values for these two patterns of plaques were overlapping in their ranges, and it was not possible to predict which lesions were acute or chronic on the basis of T2 values alone. These values were determined from averaged pixel values derived from calculated T2 images. We recently reviewed our method of a four point fit calculation based upon a data set of 16 SEs, and it was shown to accurately reflect T2 values in the clinical range of 50–245 msec to within 3% of those values derived by standardized spectrometric methods (Jackson JA, Schneiders NJ, Ford JJ, Bryan RN, unpublished data).

**TABLE 2: Results of MR Imaging and Delayed Enhanced CT Scanning in Multiple Sclerosis**

Study: Finding	No. of Patients/Type of Multiple Sclerosis		
	Acute and Chronic with Acute Exacerbation	Chronic Progressive	Total
Delayed enhanced CT:			
Positive (nonenhancing, low density) . . . . .	2	2	4
Positive (focal enhancing) . . . . .	11	1	12
Negative . . . . .	7	9	16
Total . . . . .	20	12	32
MR Imaging:			
Positive . . . . .	12	9	21
Negative . . . . .	8	3	11
Total . . . . .	20	12	32

An alteration of the blood-brain barrier is one manifestation of acute demyelination, and its demonstration is particularly well suited to the administration of an intravenous contrast agent, particularly in higher doses [9–11]. However, the toxicity of such agents is prohibitive in some patients and unpleasant in most. While the appearance of lesions on delayed enhanced CT supports the diagnosis of MS, it is not specific. The ability to detect both acute and chronic pathology without the need for an intravenous contrast agent at sensitivity equaling or surpassing that of delayed CT makes MR imaging a powerful and feasible alternative in the evaluation of these patients. However, MR imaging changes, such as prolongation of T2, are probably also relatively nonspecific, particularly in older patients where diffuse and/or focal lesions are sometimes seen [13] (Jackson JA, Schneiders NJ, Ford JJ, Bryan RN, unpublished data).

#### ACKNOWLEDGMENTS

We thank Richard E. Wendt III and the Rice University Electrical Engineering Department for assistance in data management; Robert Willcott for invaluable aid in the MR technique; Michele Gable for assistance in patient scheduling and management in the MR laboratory; Susan Blair for clerical and technical assistance; and B. Cooper, H. Derman, R. Evans, J. Grotta, Y. Harati, A. Keichian, J. Killian, B. Patten, W. Riley, M. Rivera, and D. Rosenfield for referring patients for this study.

#### REFERENCES

- Johnson RT, Katzman R, McGeer E, Price D, Shooter EM, Silberberg D. *Report of the panel on inflammatory, demyelinating, and degenerative diseases*. National Institutes of Health Publ 79–1916. Washington, DC: U.S. Department of Health, Education and Welfare, 1979
- Lumsden CE. The neuropathology of multiple sclerosis. In: Vinken PJ, Bruyn GW, eds. *The handbook of clinical neurology*, vol. 9. Amsterdam: North-Holland, 1970:217–309
- Radue EW, Kendall BE. Iodine and xenon enhancement of computed tomography (CT) in multiple sclerosis (MS). *Neuroradiology* 1978;15:153–158
- Weinstein MA, Lederman RJ, Rothner AD, Duchesneau PM, Norman D. Interval computed tomography in multiple sclerosis. *Radiology* 1978;129:689–694
- Lane B, Carroll BA, Pedley TA. Computerized cranial tomography in cerebral diseases of white matter. *Neurology* (NY) 1978;28:534–544
- Mikol F, Bouchareine A, Aubin ML, Vignaud J. La tomodensitometrie dans la sclerose en plaques. *Rev Neurol* (Paris) 1980;136:481–490
- Hersey LA, Gado MH, Trotter JL. Computerized tomography in the diagnostic evaluation of multiple sclerosis. *Ann Neurol* 1979;5:32–39
- Gyldensted C. Computer tomography of the cerebrum in multiple sclerosis. *Neuroradiology* 1976;12:33–42
- Viñuela FJ, Fox AJ, Debrun GM, Feasby TE, Ebers GC. New perspectives in computed tomography of multiple sclerosis. *AJNR* 1982;3:277–281, *AJR* 1982;139:123–127
- Sears ES, McCammon A, Bigelow R, Hayman LA. Maximizing the harvest of contrast enhancing lesions in multiple sclerosis. *Neurology* (NY) 1982;32:815–820
- Ebers GC, Viñuela FV, Feasby T, Bass B. Multifocal CT enhancement in MS. *Neurology* (NY) 1984;34:341–346
- Young IR, Hall AS, Pallis CA, Legg NJ, Bydder GM, Steiner RE. Nuclear magnetic resonance imaging of the brain in multiple sclerosis. *Lancet* 1981;2:1063–1066
- Bailes DR, Young IR, Thomas DJ, Straughan K, Bydder GM, Steiner RE. NMR imaging of the brain using spin-echo sequences. *Clin Radiol* 1982;33:395–414
- Bydder GM, Steiner RE, Young IR, et al. Clinical NMR imaging of the brain: 140 cases. *AJNR* 1982;3:459–480, *AJR* 1982;139:215–236
- Buonanno FS, Kistler JP, Lehigh JR, Noseworthy JH, New PFJ, Brady TJ. <sup>1</sup>H Nuclear magnetic resonance imaging in multiple sclerosis. *Neurol Clin* 1983;1:757–764
- Lukes SA, Crooks LE, Aminoff MJ, et al. Nuclear magnetic resonance imaging in multiple sclerosis. *Ann Neurol* 1983;13:592–601
- Young IR, Randell CP, Kaplan PW, James A, Bydder GM, Steiner RE. Nuclear magnetic resonance (NMR) imaging in white matter disease of the brain using spin-echo sequences. *J Comput Assist Tomogr* 1983;7:290–294
- Bydder GM, Steiner RE. NMR imaging of the brain. *Neuroradiology* 1982;23:231–240
- Crooks LE, Mills CM, Davis PL, et al. Visualization of cerebral and vascular abnormalities by NMR imaging: the effects of imaging parameters on contrast. *Radiology* 1982;144:843–852
- Brandt-Zawadzki M, Davis PL, Crooks LE, et al. NMR demonstration of cerebral abnormalities: Comparison with CT. *AJNR* 1983;4:117–124, *AJR* 1983;140:847–854
- Li D, Mayo J, Fache S, Robertson W, Kastrukoff LF, Oger J, Paty DW. Lack of correlation between clinical manifestations and lesions of MS as seen by NMR. *Neurology* (NY) 1984;34[suppl 1]:136
- Kinkel WR, Jacobs L, Polachini I, Kinkel RP. Computerized tomography (CT) and nuclear magnetic resonance (NMR) in multiple sclerosis (MS): A comparative study. *Neurology* (NY) 1984;34[suppl 1]:136
- McAlpine D, Lumsden CE, Acheson ED. Multiple sclerosis: a reappraisal. London: Churchill Livingstone, 1972:202
- Schneiders NJ, Post H, Brunner P, Ford J, Bryan RN, Willcott MR. Accurate T<sub>2</sub> images. *Med Phys* 1983;10:642–645
- Jacobs L, Kinkel WR, Polachini I, Kinkel RP. Clinical–nuclear magnetic resonance (NMR) correlations in multiple sclerosis (MS). *Neurology* (NY) 1984;34[suppl 1]:141