



Get Clarity On Generics

Cost-Effective CT & MRI Contrast Agents



FRESENIUS
KABI

WATCH VIDEO

AJNR

Magnetic resonance imaging of the brain in Hurler syndrome.

M A Johnson, S Desai, K Hugh-Jones and F Starer

AJNR Am J Neuroradiol 1984, 5 (6) 816-819

<http://www.ajnr.org/content/5/6/816.citation>

This information is current as
of August 21, 2025.

Magnetic Resonance Imaging of the Brain in Hurler Syndrome

M. A. Johnson,¹ S. Desai,² K. Hugh-Jones,² and F. Starer³

Intracranial manifestations are a well known feature of the mucopolysaccharidoses [1]. The appearances on computed tomography (CT) have been described and include symmetric low attenuation in white matter, hydrocephalus, and enlargement of the cortical sulci and interhemispheric fissures [2, 3]. None of these features is specific. Bone marrow transplantation has been used as a method of therapy in the mucopolysaccharidoses with resultant improvements in the clinical and biochemical features of the diseases [4–6].

As significant changes in the attenuation values between pre- and posttransplant CT scans have not been demonstrated in these patients, we tried magnetic resonance imaging (MRI) as an alternative mode of assessment in two cases. The ability of MRI to recognize and follow the normal sequence of myelination and to detect abnormalities in a variety of pediatric intracranial pathology has been described [7, 8].

Our MRI findings before transplantation in one case included reduced gray-white matter contrast, ventricular and cortical sulcal enlargement, and prolonged periventricular T2. In our second case, delayed or deficient myelination, mild ventricular enlargement, and minor periventricular increase of T2 were identified.

Two serial follow-up examinations after transplant in the first case revealed improvement in gray-white matter contrast, progressive increase in myelination, and less prominent periventricular increase of T2, while the size of the ventricles and cortical sulci remained unchanged. One follow-up examination in our second case demonstrated normal myelination, while the minor increase in periventricular T2 was essentially unchanged.

Subjects and Methods

Approval for this study was obtained from the Research Ethics Committee of the Royal Postgraduate Medical School. Informed consent was obtained from a parent before examination of each child. All examinations conformed to the guidelines established by the National Radiological Protection Board [9]. The patients were sedated using oral trimeprazine (5 mg/kg) and oral chloral hydrate (30 mg/kg)

TABLE 1: MRI Scanning Sequence

MRI Pulse Sequence	Interval (msec)			Principal Image Contrast Determinant
	Repetition	Inversion	Echo	
Repeated free induction decay	1000	Proton density
Inversion-recovery	1800	600	...	T1, proton density
Spin-echo	1080	...	80	T2, proton density

30–60 min before the examination. A surface respiratory monitor was used, and care was taken to ensure that the children were kept warm during the study. No adverse effects were noted.

Each examination included up to 10 individual slices and examination times ranged from 90 to 145 min. At least one saturation-recovery (SR), inversion-recovery (IR), and spin-echo (SE) scan were obtained at ventricular level during each study. The pulse sequences used in this study are summarized in table 1 and described according to the American College of Radiology nomenclature [10].

Case Reports

Case 1

A 9-month-old girl was seen because of an enlarged head. Typical features of Hurler syndrome were noted, including corneal clouding, claw hands, lumbar gibbus, and hepatosplenomegaly. Her head circumference, 56.1 cm, was above the 98th percentile for 2 years of age.

Biochemical abnormalities supported a firm diagnosis of Hurler syndrome. There were a pronounced increase in urinary glycosaminoglycans (GAG) at 171 mg GAG/mmol creatinine (normal, 4–31) and a deficiency of leukocyte alpha-L-iduronidase at 0.05 nmol/mg protein/hr (day 0, fig. 1A).

CT at age 2 years revealed mild ventricular dilatation with expansion of the subarachnoid space in the frontal region. An IR 1800/600 scan (fig. 1B) confirmed ventricular enlargement and prominent cortical sulci. Reduced gray-white matter contrast relative to a normal child of age 20 months (fig. 1C) was noted. SE 1080/80 scans demonstrated prolonged T2 in the periventricular regions (fig. 1D).

Received February 13, 1984; accepted after revision June 13, 1984.

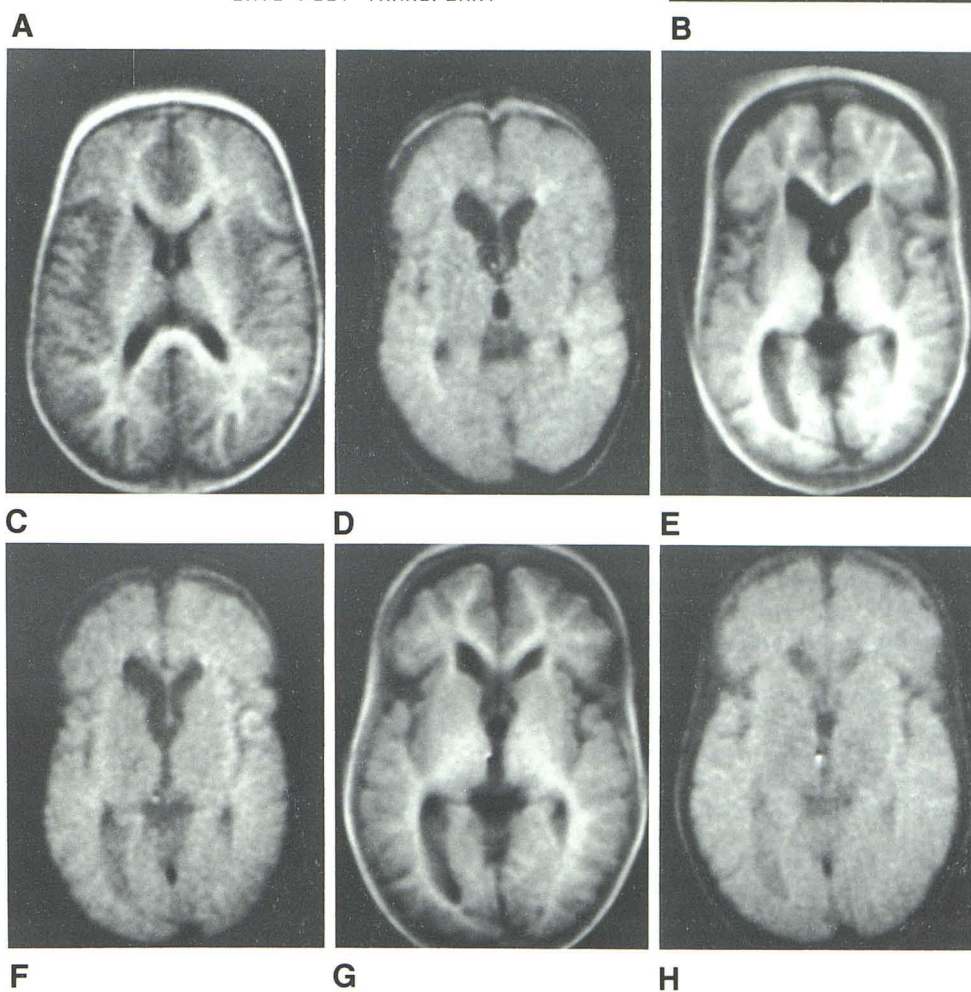
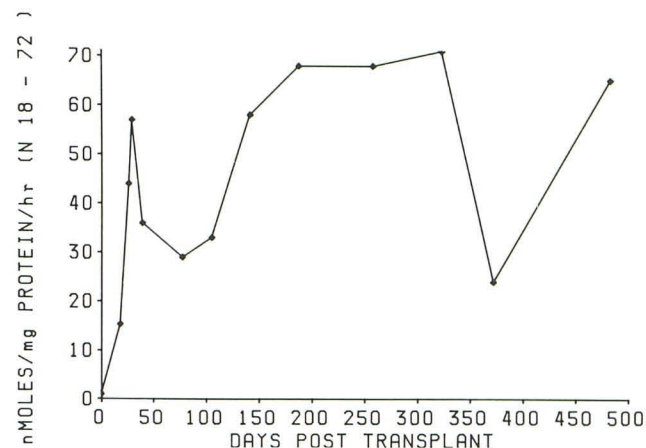
M. A. Johnson is an Alberta Heritage Foundation for Medical Research fellow.

¹ Department of Diagnostic Radiology, Hammersmith Hospital, Du Cane Rd., London W12 0HS, England. Address reprint requests to M. A. Johnson.

² Westminster Bone Marrow Team, Westminster Children's Hospital, London, England.

³ Department of Radiology, Westminster Children's Hospital, London, England.

Fig. 1.—Case 1. **A**, Leukocyte alpha-L-iduronidase levels. **B**, IR 1800/600 scan at age 2 years. Limited gray-white matter contrast, mild lateral ventricular enlargement, and prominent cortical sulci. **C**, IR 1800/600 scan of normal 20-month-old child for comparison with **B**. **D**, SE 1080/80 scan. Prolonged periventricular T2. **E**, IR 1800/600 scan at age 2½ years (6 months posttransplant). Improved gray-white matter contrast and increased myelination. **F**, SE 1080/80 scan. Less prominent prolonged periventricular T2. **G**, IR 1800/600 and **H**, SE 1080/80 scans at age 3 years (11 months posttransplant). Further improvement.



At this time, treatment with bone marrow transplant was performed using the patient's 4-month-old human leukocyte antigen (HLA) and mixed lymphocyte reaction (MLR) compatible sibling as donor. Preparation for the transplant included insertion of a Hickman catheter, a conditioning regime of busulfan (80 mg/m^2) for 4 days followed by donor buffy coat, and then cyclophosphamide (2.0 g/m^2) for 4 days and reverse barrier nursing.

Bone marrow infusion was performed using 2.4×10^8 nucleated cells/kg.

Bone marrow engraftment was confirmed by enzyme levels. Clinical follow-up showed clearance of the corneal clouding and hepatosplenomegaly and cessation of the accelerated rate of skull growth. Biochemical follow-up revealed that the leukocyte alpha-L-iduronidase level (fig. 1A) had returned to normal and urinary GAG of 28

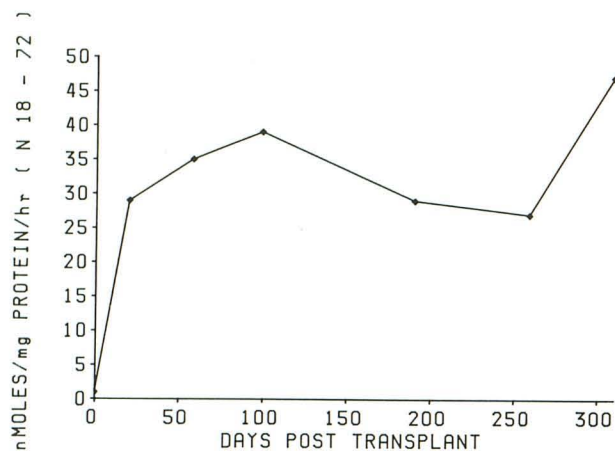
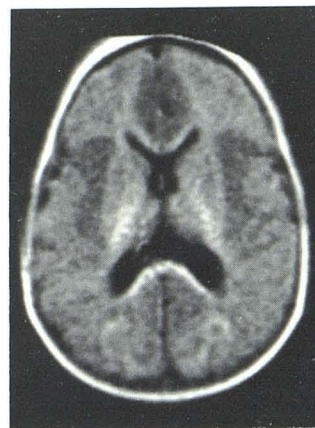
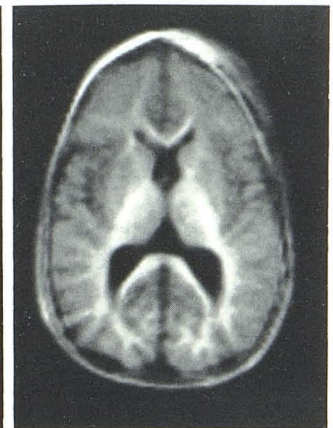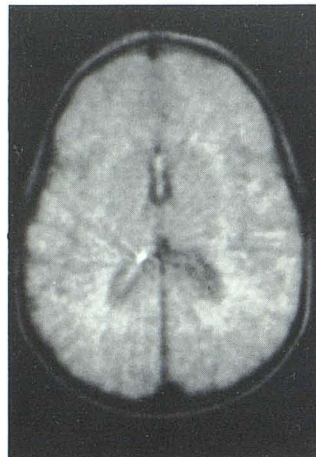
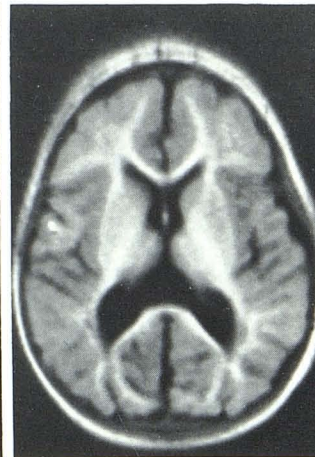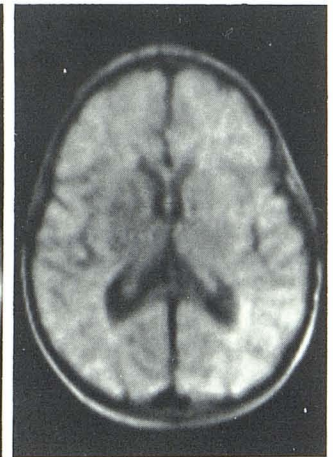
**A****B****C****D****E****F**

Fig. 2.—Case 2. **A**, Leukocyte alpha-L-iduronidase levels. **B**, IR 1800/600 scan at age 16 months. Reduced gray-white matter contrast and delayed or deficient myelination. Mild dilatation in posterior horns of lateral ventricles. **C**, IR 1800/600 scan in normal 9-month-old child for comparison with **B**. **D**, SE 1080/80 scan. Mild increase in T2 in periventricular region adjacent to posterior horns of lateral ventricles. **E**, IR 1800/600 scan at age 23 months (6½ months posttransplant). Significant improvement in image quality. Myelination now within normal limits.

mg/mmol creatinine almost returned to normal range (9–20 mg/mmol creatinine).

On follow-up IR 1800/600 scan (fig. 1E) at 2½ years of age (6 months posttransplant), increased gray-white matter contrast was evident, and myelination was noted in the forceps minor, internal capsule, thalamooccipital radiation, and hemispheres. SE 1080/80 images demonstrated less prominent periventricular increase of T2 (fig. 1F).

Further follow-up IR 1800/600 scans at age 3 years (11 months posttransplant) demonstrated increased myelination as well as continued prominence of the cortical sulci (fig. 1G). Ventricular size was essentially unchanged, allowing for differences in positioning. SE 1080/80 images failed to reveal any significant prolonged T2 in the periventricular region (fig. 1H).

Case 2

A 6-month-old girl was seen because of a lumbar gibbus. Biochemical investigation at age 8 months established the diagnosis of Hurler syndrome by demonstration of significantly increased urinary GAG at 146 mg GAG/mmol creatinine (normal, 4–31) and reduced leukocyte alpha-L-iduronidase levels of 3.1 nmol/hr/mg protein (day 0, fig. 2A). By 1 year of age, typical clinical features of Hurler syndrome were

present, including corneal clouding, hepatomegaly, and lumbar gibbus. Her head circumference of 51 cm was above the 98th percentile for 1 year of age. A development quotient (DQ) of 118, which is above the normal average DQ of 100, was scored on the Ruth Griffiths developmental scales. These assess locomotor, personal and social, hearing, speech, eye and hand coordination, performance, and practical reasoning skills.

Initial IR 1800/600 scan (fig. 2B) at age 16 months revealed reduced gray-white matter contrast by comparison with a normal child of 9 months (fig. 2C). Mild dilatation of the posterior horns of the lateral ventricles was noted, and an SE 1080/80 image (fig. 2D) revealed mildly increased periventricular T2 adjacent to the posterior horns.

Bone marrow transplant was performed at age 16½ months and preparation was performed as for case 1. Bone marrow infusion of 4.4×10^8 nucleated cells/kg from an unrelated HLA MLR-compatible donor was given. Biochemical follow-up indicated that leukocyte alpha-L-iduronidase levels reverted to normal (fig. 2A), and urinary GAG decreased to 32 mg/mmol creatinine (normal, 9–20). Head circumference remained stable at 51 cm, and hepatomegaly and corneal clouding disappeared.

Follow-up IR 1800/600 scan at 23 months of age (6½ months posttransplant) (fig. 2E) revealed improvement, especially when compared with an age-matched untreated child with Hurler syndrome (fig. 1B). Increased gray-white matter contrast was noted and myelination

was within normal limits. Slight increase in periventricular T2 was again noted on SE 1080/80 images (fig. 2F).

Discussion

MRI findings before bone marrow transplant in these two patients included reduced gray-white matter contrast, delayed or deficient myelination, prolonged periventricular T2, and enlargement of the ventricular system and cortical sulci. The reduced gray-white matter contrast may be related to the deposition of glycolipids and mucopolysaccharides in the lysosomes of neurons and astrocytes of gray and white matter that occurs in Hurler syndrome [1, 11]. As well, cavitation occurs around blood vessels with accumulation of foam cells in the Virchow-Robin spaces [12, 13]. Dilated periadventitial spaces with viscous fluid, "gargoyle cells," and mesenchymal elements have been described [14]. These would tend to increase the T1 and T2 of gray and white matter.

Hydrocephalus, a frequent finding in the mucopolysaccharidoses, if associated with periventricular edema may also result in prolonged T1 and T2 of periventricular white matter with resultant decrease in gray-white matter contrast. However, as described by Watts et al. [2] symmetric white-matter low attenuation seen on CT usually was more extensive than expected for this cause alone. It resolved only partially after successful ventricular drainage and developed with a functioning shunt in place. Periventricular edema may be a partial explanation for the reduced contrast.

Improvement in the clinical and biochemical features in the mucopolysaccharidoses after bone marrow transplant has been described [4-6].

However, significant changes in the attenuation values were not demonstrated on CT scans of the brain in our cases. MRI did identify significant changes, including increased myelination and improved gray-white matter contrast. The precise degree to which these changes can be attributed to bone marrow transplant can be ascertained only by further studies. The periventricular increase of T2 regressed in case 1 and remained minimal but unchanged in case 2. This may represent some residual periventricular edema. The ventricles and cortical sulci remained unchanged in size, allowing for differences in positioning, a factor that must be considered in serial examinations.

In summary, MRI of the brain in Hurler syndrome provides direct morphologic evidence of delayed or deficient myelination and progressive improvement after bone marrow transplant.

ACKNOWLEDGMENTS

We thank the Department of Health and Social Security and, in particular, Gordon Higson and John Williams for their continued support and encouragement.

REFERENCES

1. McKusick VA, Neufeld EF, Kelly TE. The mucopolysaccharide storage diseases. In: Stanbury JB, Wyngaarden JB, Frederickson DS, eds. *The metabolic basis of inherited diseases*, 4th ed. New York: McGraw-Hill, 1973:1282-1288
2. Watts RWE, Spellacy E, Kendall BE, et al. Computed tomography studies on patients with mucopolysaccharidoses. *Neuroradiology* 1981;21:9-23
3. Kendall BE. Symmetrical white matter low attenuation in children. In: *X-tract No. 7*. Amsterdam: Excerpta Medica, 1979:3-14
4. Hobbs JR, Hugh-Jones K, Barrett AJ, et al. Reversal of clinical features of Hurler's disease and biochemical improvement after treatment by bone-marrow transplantation. *Lancet* 1981;2:709-712
5. Hugh-Jones D, Kendra J, James DCO, et al. Treatment of Sanfilippo B disease (MPS III B) by bone marrow transplant. *Exp Hematol* 1982;10[Suppl 10]:50-51
6. Desai S, Hobbs JR, Hugh-Jones K, et al. Morquio's disease (mucopolysaccharidosis IV) treated by bone marrow transplant. *Exp Hematol* 1983;[Suppl 13]:98-100
7. Johnson MA, Pennock JM, Bydder GM, et al. Clinical NMR imaging of the brain in children: normal and neurological disease. *AJNR* 1983;4:1013-1026, *AJR* 1983;141:1005-1018
8. Levene MI, Whitelaw A, Dubowitz V, et al. Nuclear magnetic resonance imaging of the brain in children. *Br Med J* 1982;285:774-776
9. National Radiological Protection Board. *Exposure to nuclear magnetic resonance clinical imaging*. Harwell, Oxon, England: National Radiological Protection Board, 1980
10. American College of Radiology. *Glossary of NMR terms*. Chicago: American College of Radiology, 1983
11. Purpura DP, Suzuki K. Distortion of neuronal geometry and formation of aberrant synapses in neuronal storage disease. *Brain Res* 1976;116:1-21
12. Crome L, Stern J. *Pathology of mental retardation*, 4th ed. London: Churchill Livingstone, 1972:320-324
13. Winters PR, Harrod MJ, Molenich-Heetred SA, Kirkpatrick J, Rosenberg RG. Alpha-L-iduronidase deficiency and possible Hurler-Scheie genetic compound. *Neurology* (NY) 1976;26:1003-1007
14. Dekaban AS, Constantopoulos G. Mucopolysaccharidoses types I, II, IIIA and IV. Pathological and biochemical abnormalities in the neural and mesenchymal elements of the brain. *Acta Neuropathol* (Berl) 1977;39:1-7