



Discover Generics

Cost-Effective CT & MRI Contrast Agents



FRESENIUS
KABI

[VIEW CATALOG](#)

AJNR

Value of computed tomographic myelography in the recognition of cervical herniated disk.

J A Landman, J C Hoffman, Jr, I F Braun and D L Barrow

AJNR Am J Neuroradiol 1984, 5 (4) 391-394

<http://www.ajnr.org/content/5/4/391>

This information is current as
of September 2, 2025.

Value of Computed Tomographic Myelography in the Recognition of Cervical Herniated Disk

Jeffrey A. Landman¹
James C. Hoffman, Jr.¹
Ira F. Braun¹
Daniel L. Barrow²

Three patients with cervical radicular symptoms and normal metrizamide myelograms underwent thin-section high-resolution computed tomographic scanning because of a strong clinical suspicion of herniated disk. Herniated disk was demonstrated in all three cases. In two, the disk protrusions were recognized only by computed tomographic myelography, and in the third case, the diagnosis was made with plain computed tomography and confirmed by computed tomographic myelography.

Traditionally, confirmation of clinically suspected cervical disk disease has been sought by Pantopaque or plain-film metrizamide myelography [1, 2]. Recently computed tomography (CT) has been used to demonstrate cervical disk disease in patients with suspicious myelograms [3]. CT myelography is a technique in which spinal CT is combined with the intrathecal administration of metrizamide. Since its first description, this procedure has been used in a large number of disorders of the spinal canal and its contents [4, 5]. We present three patients with signs and symptoms of a cervical radiculopathy who had negative metrizamide myelograms, positive CT myelograms, and operative findings of soft herniated cervical disks at the level outlined by CT myelography.

Materials and Methods

Seventy patients referred for cervical myelography were studied with metrizamide myelograms and then followed by CT. Three patients in this group demonstrated a discrepancy between myelography and CT myelography; they are described in detail.

Metrizamide myelography was performed with a C1–C2 puncture and instillation of 6–8 ml of 250 mg I/ml metrizamide into the subarachnoid space under anteroposterior (AP) and lateral fluoroscopic control. After routine myelographic studies, 1.5 mm CT scans using a GE 8800 CT/T scanner were obtained with the gantry angled parallel to the disk space of clinical interest. One contiguous slice on either side of the disk space was obtained as were thin sections through the disks above and below the level of clinical interest. The patients subsequently underwent an anterior cervical discectomy and fusion performed by one of the authors (D. L. B.).

Case Reports

Case 1

A 43-year-old man developed left neck, shoulder, and arm pain 2½ years before this presentation. He was seen at that time by a neurologist who documented weakness of the left triceps with a diminished left triceps reflex.

A metrizamide myelogram was obtained by C1–C2 puncture. The plain films of the myelogram failed to reveal any displacement of the nerve roots, and the spinal cord was within normal limits (fig. 1A).

After the myelogram, a CT myelogram was obtained through the C6–C7 and C7–T1 spaces. A soft-tissue defect at the level of C7–T1 was identified slightly eccentric to the left

Received September 12, 1983; accepted after revision December 28, 1983.

¹ Department of Radiology, Section of Neuroradiology, Emory University School of Medicine, Atlanta, GA 30322. Address reprint requests to J. C. Hoffman, Jr.

² Department of Surgery, Division of Neurosurgery, Emory University School of Medicine, Atlanta, GA 30322.

AJNR 5:391–394, July/August 1984

0195–6108/84/0504–0391 \$2.00

© American Roentgen Ray Society

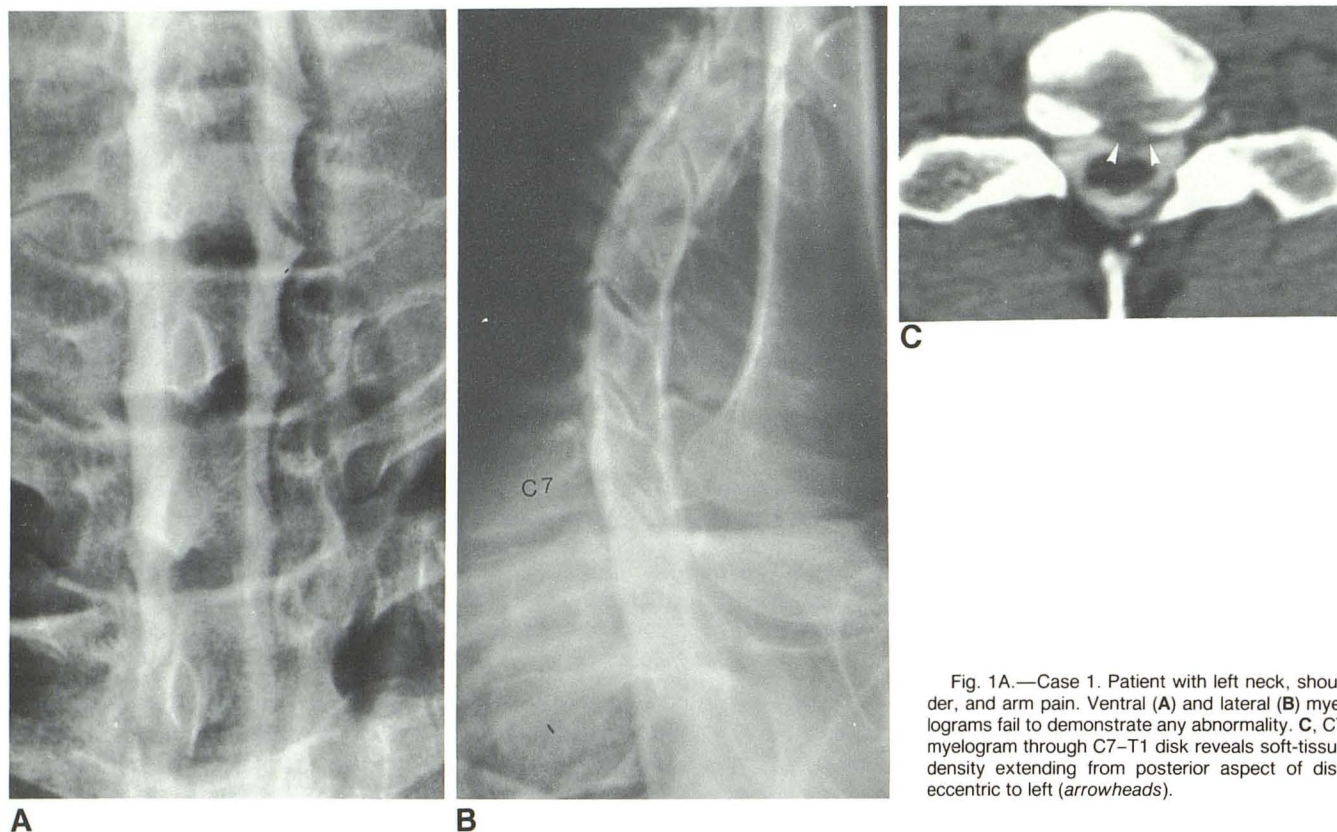


Fig. 1A.—Case 1. Patient with left neck, shoulder, and arm pain. Ventral (A) and lateral (B) myelograms fail to demonstrate any abnormality. C, CT myelogram through C7–T1 disk reveals soft-tissue density extending from posterior aspect of disk eccentric to left (arrowheads).

side and impinging on the subarachnoid space on the posterior lateral margin (fig. 1B). No displacement of the spinal cord was identified.

At operation a fragment of disk was identified and removed through a tear in the posterior longitudinal ligament at C7–T1. Its position at surgery correlated quite accurately with the defect outlined by CT myelography. The patient enjoyed immediate relief of his pain and had a normal examination 5 months after operation.

Case 2

A 39-year-old woman was seen after 6 months of gradually progressive pain in the neck radiating into the right arm and index finger. On examination she had a depressed right biceps reflex and mild right biceps weakness.

The patient underwent metrizamide myelography by way of a C1–C2 puncture. The nerve roots filled well with metrizamide and were unremarkable. No displacement of the thecal sac or cord was noted (fig. 2A). A CT myelogram immediately after the metrizamide myelogram revealed a soft-tissue density impinging on the subarachnoid space at C5–C6 on the right (fig. 2B).

At surgery, a degenerated disk was removed from C5–C6. No definite defect could be identified in the posterior longitudinal ligament. The symptoms resolved and the neurologic examination was normal 4 months after surgery.

Case 3

A 50-year-old man underwent a cervical laminectomy and discectomy 3 years before admission for right cervical radiculopathy. He developed recurrence of the pain in his neck that radiated into the left arm down to the elbow.

A CT scan without intrathecal or intravenous contrast administration was obtained through the C4–C5 disk space before myelography. A defect was seen eccentric to the left at the posterior lateral aspect of the disk (fig. 3A). The myelogram was interpreted as minimal

osteophytes at C3–C4 and C4–C5 (fig. 3B). A CT myelogram through C4–C5 confirmed the defect noted on the noncontrast CT scan (fig. 3C).

On the basis of the CT myelogram, anterior cervical discectomy at C4–C5 was planned. Disk material was removed from C4–C5, and a definite defect on the left side of the posterior longitudinal ligament was noted. Through this defect a large, free fragment of disk was retrieved. The patient was symptom-free 6 months after the procedure.

Discussion

Traditionally myelography with Pantopaque has been used for the demonstration of cervical disk disease, but it has its shortcomings. Fox et al. [2] demonstrated the nonspecificity of Pantopaque myelographic findings in many cases. They demonstrated that spondylosis often cannot be differentiated from cervical soft disk. McGinnis and Eisenbrey [6] stated that extensive disk defects can be obscured completely in the posteroanterior projection by failure of x-ray penetration of the dense Pantopaque. However, in contrast to Fox et al., McGinnis and Eisenbrey stated that the diagnosis of disk herniations was possible in 92% of their cases. But, they also stated that 18% of patients regarded as having lobulated myelographic defects consistent with disk protrusions actually had spondylotic changes at operation. Other investigators have stated that the size or shape of the defect on the root sleeve or failure of visualization of sleeves was a criterion for diagnosis of disk disease [7, 8]. Fox et al. stated that elevation of nerve rootlets was the only reliable myelographic deformity of a lateral herniated disk. These authors reported 62 examinations, of which 12 revealed this deformity; operative cor-

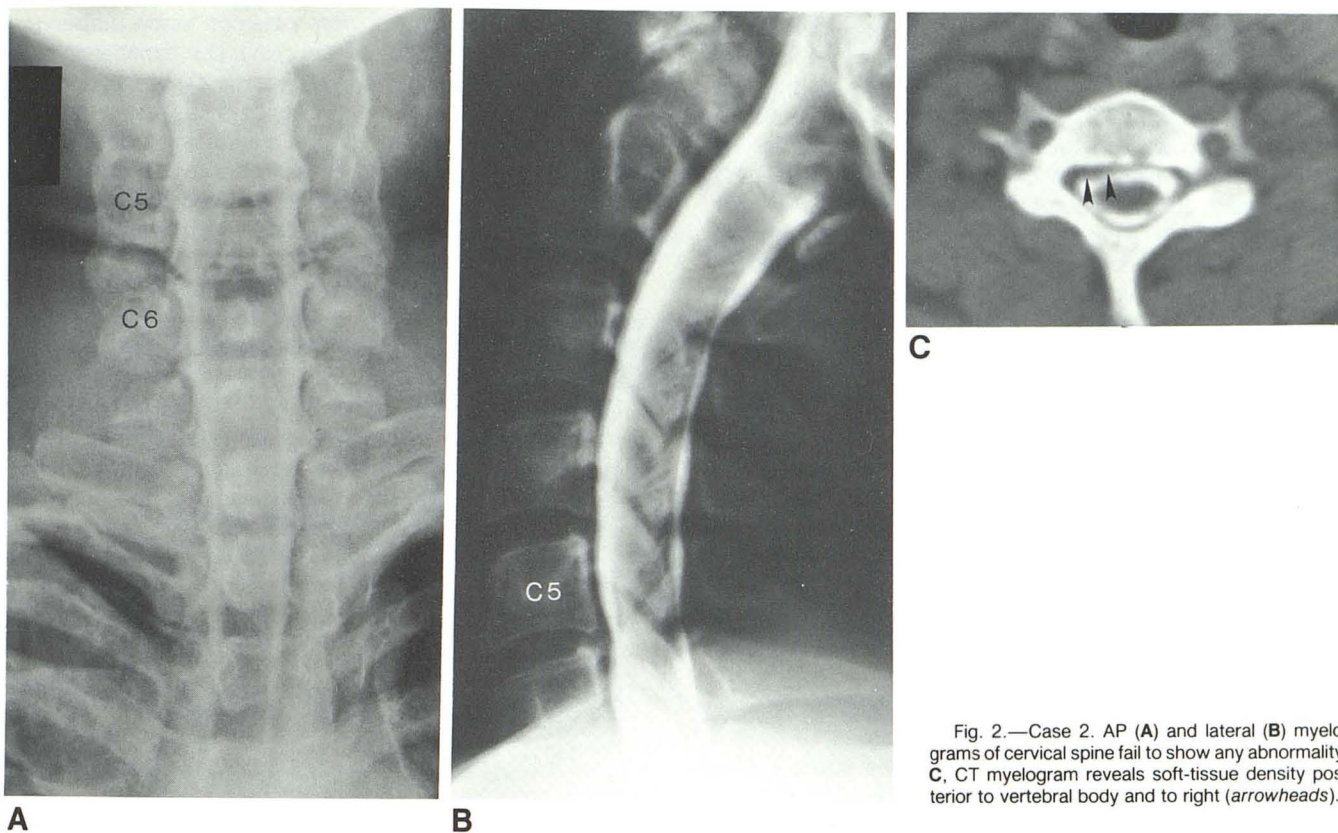


Fig. 2.—Case 2. AP (A) and lateral (B) myelograms of cervical spine fail to show any abnormality. C, CT myelogram reveals soft-tissue density posterior to vertebral body and to right (arrowheads).

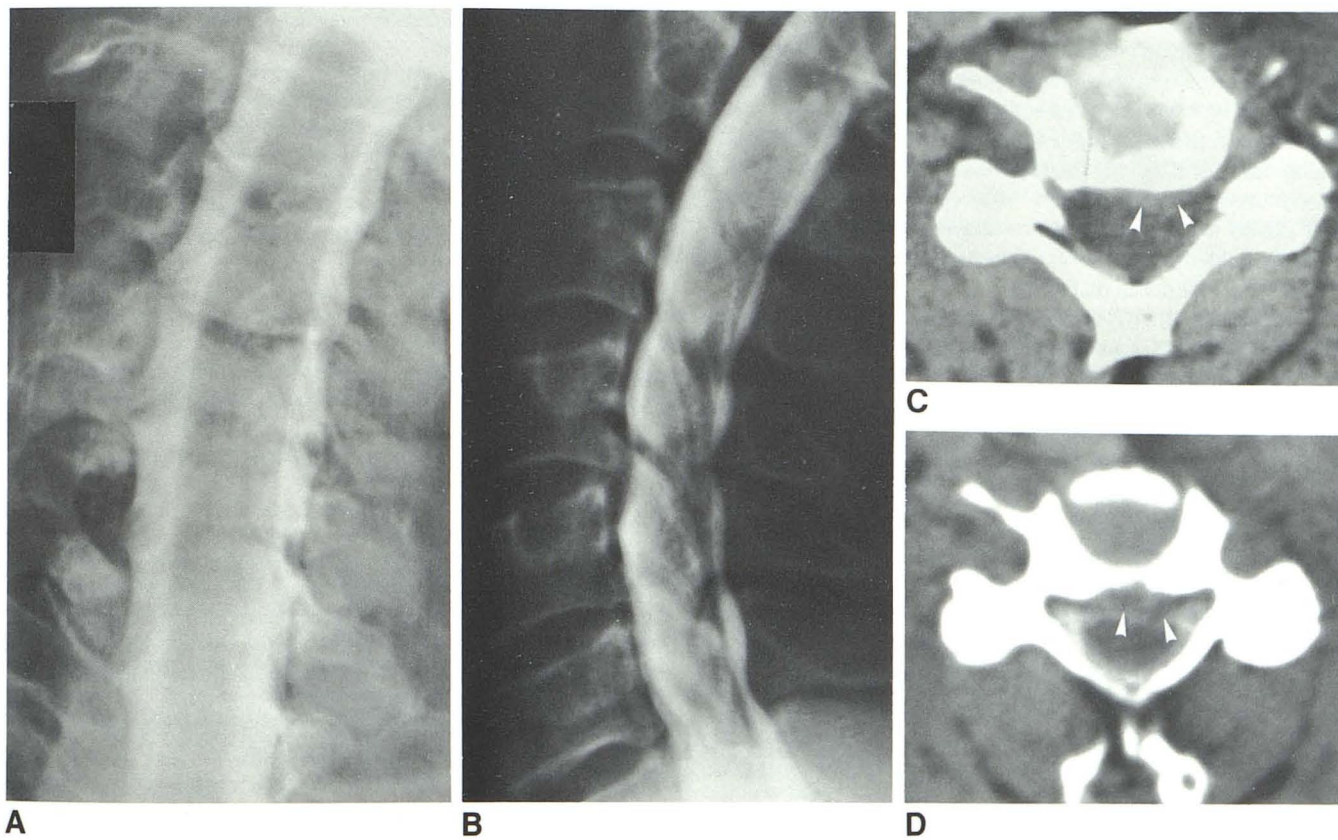


Fig. 3.—Case 3. Frontal (A) and lateral (B) cervical myelograms reveal minimal bulge at C3-C4 and C4-C5 thought secondary to osteophytes. AP film was interpreted as normal. C, Noncontrast CT scan through C4-C5 disk shows soft-tissue density posterior to vertebral body and eccentric to left.

(arrowheads). D, CT myelogram through C4-C5 reveals large soft-tissue defect posterior to vertebral body and corresponding to bulge on A and B (arrowheads).

relation was lacking in this group of patients.

Recently, metrizamide has replaced Pantopaque in many cases as a myelographic contrast agent. It has been recognized that water-soluble myelographic agents give better definition of nerve rootlets as the nerve root sleeves fill more readily. Accordingly, small lateral herniations are theoretically more readily visible [9–13]. In addition, because of the lower radiographic density of metrizamide, small anterior lesions are also theoretically easier to find. Cronqvist and Brismar [14] demonstrated 104 extradural defects in 190 metrizamide myelograms. They showed that midline protrusions were sometimes partly concealed on the AP and oblique views; however, on the lateral examination a double contour was usually present. These authors concluded that in the absence of a bony spur, the diagnosis of soft-disk herniation can be made.

In contradistinction, Amundsen [15] stated that the differentiation between spondylotic changes and disk herniation can be suggested only if there is a "very marked lesion," and even then, it may be impossible to distinguish between them. In his series of 365 patients undergoing cervical metrizamide myelography, 151 demonstrated extradural defects secondary to spondylosis or herniation. Of these, 20 proved to have operative evidence of herniated disk. However, no distinction was made of the number of herniations that were suspected preoperatively.

Since the advent of CT scanning, it is becoming common to use CT to demonstrate herniated disks. Scotti et al. [16] performed plain CT in 17 of 40 patients who subsequently underwent metrizamide film myelography and CT myelography. They stated that in 17 patients examined by plain CT there was close correspondence between pre- and postmyelographic CT studies in demonstrating narrowing of the spinal canal and neural foramina. Disk herniation was recognized in eight cases with CT myelography and only in five with plain CT. Cord compression was identified in 10 patients with CT myelography and in no patients with plain CT. From this experience they observed that intrathecal contrast enhancement allows for differentiation between compression due to osteophytes or to disk herniation when a plain CT scan may be unable to make this distinction.

Nakagawa et al. [3] and Scotti et al. [16] have shown separately that CT myelography can determine accurately whether a bony spur or soft-tissue defect exists when high-resolution CT is used. Nakagawa et al. demonstrated a discrepancy between film metrizamide myelography and CT myelography in 25% of their patients [3]. They concluded that CT myelography is superior to film myelography in the diagnosis of disk disease and especially in cases of central disk protrusions. Dublin et al. [17] studied 106 patients with metrizamide myelography followed by CT myelography. Of the 106, 32% were cervical myelographic studies. It was found that the film myelographic study was most useful in directing CT to areas of pathology. However, the data from both authors are grouped into categories such as herniated disk, spondylosis, tumor, etc. Therefore, the number of cervical disks identified by film myelography and CT myelography cannot be determined.

In recent years many surgeons have been using the anterior approach to the cervical spine for both herniated "soft" disks and osteophytes or "hard" disks. Some surgeons have continued to use the posterior approach for "soft" disks, a good

operation carrying a greater than 90% cure rate in well selected cases. Knowledge of the exact location and the nature of the lesion, for example, "soft" herniated disk versus "hard" disk or osteophyte, may influence some surgeons' operative approach to the cervical spine. Our experience and that of others indicates that metrizamide CT is superior to conventional myelography in making these assessments. Of greater importance from a surgical standpoint is the superiority of metrizamide CT in determining the level of pathology. In one of our patients the CT myelogram directed the surgeon to a level other than the one that would have been expected on purely clinical grounds (case 1).

Our three cases may be summarized: Metrizamide myelograms at the level of clinical interest were normal. Because of continuing clinical suspicion, high-resolution, thin-slice (1.5 mm) CT myelography was undertaken. We were able to demonstrate soft-tissue densities on CT myelography that were not detectable on film myelography. In addition, differentiation was easy between bony spur and soft disk. Operative correlation was obtained in all cases, and the patients' symptoms and signs all resolved after operation.

REFERENCES

1. Shapiro R. *Myelography*. Chicago: Year Book Medical, 1975: 392–406
2. Fox AJ, Lin JP, Pinto RS, Kricheff II. Myelographic cervical nerve root deformities. *Radiology* 1975;116:335–361
3. Nakagawa H, Okumura T, Sugiyama T, Iwata K. Discrepancy between metrizamide CT and myelography in diagnosis of cervical disk protrusions. *AJNR* 1983;4:604–606
4. DiChiro G, Schellinger D. Computed tomography of spinal cord after lumbar intrathecal introduction of metrizamide. *Radiology* 1976;120:101–104
5. Barrow DL, Wood JH, Hoffman JC Jr. Clinical indications for computer assisted myelography. *Neurosurgery* 1983;12:47–57
6. McGinnis K, Eisenbrey B. Diagnostic criteria for distinguishing cervical disk herniation from spondylosis in the neural compression syndrome. *Radiology* 1964;83:67–73
7. Murphey F, Pascucci LM, Meade WH, van Zwaluwenburg BR. Myelography in patients with ruptured cervical intervertebral discs. *AJR* 1946;56:27–42
8. Stoops WL, King RB. Neural complications of cervical spondylosis: their response to laminectomy and foramenectomy. *J Neurosurg* 1962;19:986–999
9. Khan A, Marc JA, Chen M, Epstein JA. Total myelography with metrizamide through the lumbar route. *AJNR* 1981;2:85–90, *AJR* 1981;136:771–776
10. Fox A, Vinuela F, Debrun G. Complete myelography with metrizamide. *AJNR* 1981;2:79–84
11. Grange B. Cervical myelography via C1/C2 lateral puncture. *Radiography* 1981;67:35–41
12. Boyd WR, Gardiner GA Jr. Metrizamide myelography. *AJR* 1977;129:481–484
13. Sackett J, Strother C. *New techniques in myelography*. New York: Harper & Row, 1979:109–123
14. Cronqvist S, Brismar J. Cervical myelography with metrizamide. *Acta Radiol [Diagn]* (Stockh) 1981;21:282–287
15. Amundsen P. Cervical myelography with Amipaque: seven years experience. *Radiologe* 1981;21:282–287
16. Scotti G, Scialfa G, Pieralli E, Boccardi E, Valsecchi F, Tonon C. Myelopathy and radiculopathy due to cervical spondylosis: myelographic-CT correlations. *AJNR* 1983;4:601–603
17. Dublin AB, McGahan JP, Reid MH. The value of computed tomographic metrizamide myelography in the neuroradiological evaluation of the spine. *Radiology* 1983;146:79–86