



Providing Choice & Value
Generic CT and MRI Contrast Agents

**FRESENIUS
KABI**

CONTACT REP

AJNR

Sarcoidosis of the orbit with bone destruction.

R B Wolk

AJNR Am J Neuroradiol 1984, 5 (2) 204-205

<http://www.ajnr.org/content/5/2/204.citation>

This information is current as
of July 20, 2025.

Sarcoidosis of the Orbit with Bone Destruction

Richard B. Wolk¹

Sarcoidosis is a multisystem disease frequently involving the skin, lymph nodes, liver, spleen, myocardium, maxillary glands, paranasal sinuses, and eyes. Ophthalmologic findings may consist of conjunctivitis, uveitis, lacrimal gland involvement, cataracts, infiltration of the eyelids, and rarely proptosis [1]. An unusual case is reported in which bone destruction associated with sarcoidosis of the orbit and paranasal sinuses was demonstrated radiographically by computed tomographic (CT) scanning.

Case Report

A 52-year-old woman entered for a routine ophthalmologic examination. She was unaware that her left eye was proptotic and deviated 8 mm from the midline. A CT scan demonstrated a mass involving the ethmoid and maxillary sinuses associated with destruction of the medial wall of the left orbit (fig. 1). Chest films showed bilateral hilar and right paratracheal adenopathy unchanged from 5 years before and consistent with sarcoidosis (fig. 2). The physical examination was otherwise normal.

Biopsy of the paranasal sinus mass revealed noncaseating granulomas. Pulmonary function tests demonstrated restrictive lung abnormalities without obstruction and a mild diffusion impairment. Serum angiotensin converting enzyme was 129 nmol/min/ml (normal, 44–125). Almost total resolution of the proptosis was noted 3 weeks after institution of therapy, consisting of prednisone, 20 mg/day. Improvement in the patient's pulmonary function was noted as follows: initial forced vital capacity of 70% rose to 80%; initial forced expiratory volume in 1 sec of 71% rose to 94%; and initial mid

maximum flow of 70% rose to 110%. The patient was maintained on a prednisone dosage of 10 mg daily, and was still asymptomatic after 7 months.

Discussion

Both paranasal sinus involvement and proptosis are unusual findings in sarcoidosis. Proptosis as an initial symptom of sarcoidosis has been reported [2, 3], although conjunctivitis, uveitis, iritis, and lacrimal gland involvement are much more typical ophthalmologic presentations [4, 5]. Bone destruction in the face was documented tomographically in a case of sarcoidosis involving the maxillary antrum [6], but no previous radiographic demonstration of orbital wall destruction in sarcoid was found.

The differential diagnosis of such facial lesions include chronic infection, primary and metastatic tumors, eosinophilic granuloma, and Wegener granuloma [7]. Histologic findings of noncaseating granuloma are nonspecific, being found in Wegener granulomatosis as well as sarcoidosis. Therefore, correlation with other parameters such as pulmonary function tests, serum angiotensin converting enzyme, and Kveim reactions, as well as correlation with the patient's clinical course, including the development of multiple system involvement, helped to confirm the diagnosis of sarcoidosis.

Although it is most unusual, sarcoidosis should be considered in the differential diagnosis of destructive lesions of the orbits and paranasal sinuses.

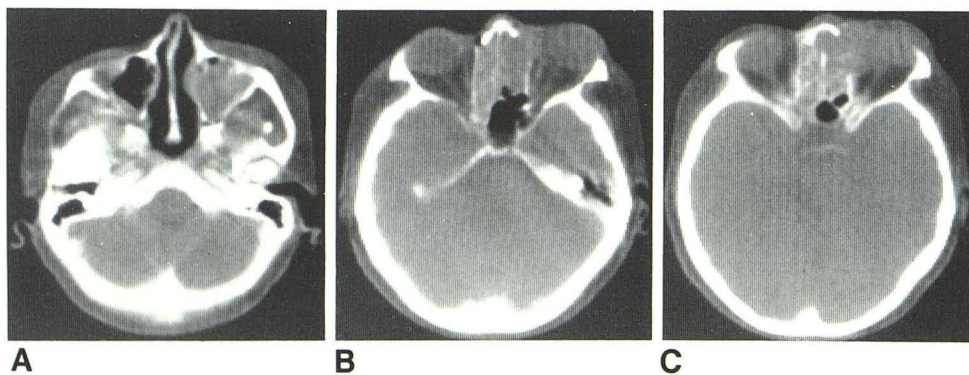


Fig. 1.—Soft-tissue mass filling left maxillary antrum (A), extending into ethmoid sinuses (B), and destroying medial wall of left orbit (C), resulting in exophthalmos.

Received November 3, 1982; accepted after revision March 28, 1983.

¹ Department of Radiology, Leonard Morse Hospital, Natick, MA 01760.

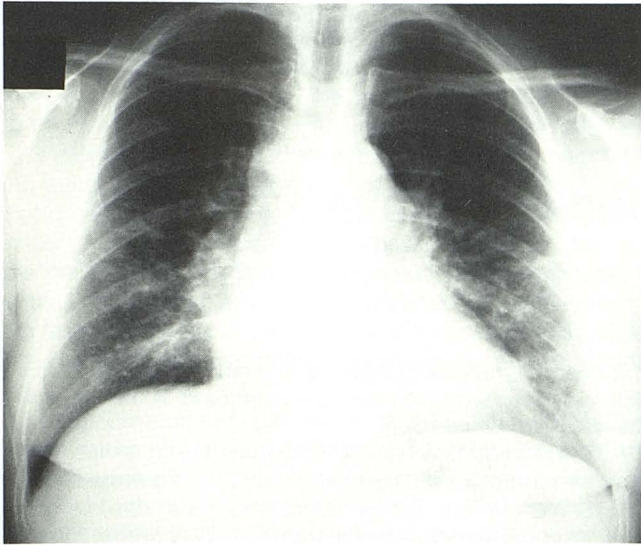


Fig. 2.—Posteroanterior chest film. Right paratracheal and bilateral hilar adenopathy.

REFERENCES

1. Ainslie D, James DG. Ocular sarcoidosis. *Br Med J* **1956**;1:954-957
2. Melmon KL, Goldberg JS. Sarcoidosis with bilateral exophthalmus as the initial symptom. *Am J Med* **1962**;33:158-160
3. Rider JA, Dodson JW. Sarcoidosis. *Am J Ophthalmol* **1950**;33:117-120
4. Stein HA, Henderson JW. Sarcoidosis of the orbit. *Am J Ophthalmol* **1956**;41:1054-1056
5. Bodian M, Lasky M. Sarcoidosis of the orbit. *Am J Ophthalmol* **1950**;33:343-353
6. Trachtenberg SB, Wilkinson EE, Jacobson G. Sarcoidosis of the nose and paranasal sinuses. *Radiology* **1974**;113:619-620
7. Resnick D, Niwayama G. Sarcoidosis. In: Resnick D, Niwayama G, eds. *Diagnosis of bone and joint disorders*. Philadelphia: Saunders, **1981**:2917-2923

Editor's Note

See also: Dubois PJ, Beardsley T, Klintworth G, et al. Computed tomography of sarcoidosis of the optic nerve. *Neuroradiology* **1983**;24:179-182