



Get Clarity On Generics

Cost-Effective CT & MRI Contrast Agents



FRESENIUS
KABI

WATCH VIDEO

AJNR

Alternative Method of Intraocular Foreign-Body Localization

Ann Watson and D. E. Hartley

AJNR Am J Neuroradiol 1984, 5 (1) 53-54

<http://www.ajnr.org/content/5/1/53.citation>

This information is current as
of August 5, 2025.

Alternative Method of Intraocular Foreign-Body Localization

Ann Watson¹ and D. E. Hartley¹

We describe a system for the localization of radiopaque ocular foreign bodies that has been in use at Royal Perth Hospital for 10 years. It has proved to be simple to use and provides a high degree of accuracy.

Intraocular Foreign Body Localizer

Anteroposterior (AP) and lateral films are obtained simultaneously, and superimposed on them is the shadow of a pair of cross wires representing the center of the pupil in the AP projection and the front surface of the cornea in the lateral projection. This is achieved by the use of a frame on which are mounted three sighting devices. Each sight is like a simple gunsight with two sets of cross hairs 80 mm apart; one of the cross hairs is radiolucent, and the other is radiopaque so as to be superimposed on the x-ray film. Two of the sights are mounted horizontally and are coaxial. These are the sights used for lateral projections; one is used for right eye localization and the other when left eye localization is required. These sights are positioned by adjusters in vertical and horizontal directions. The third sight is mounted vertically for the AP projection and can be adjusted laterally over a range covering both eyes. The center axis of this sight intersects the center axis of the lateral sights and moves with them if they are adjusted in a horizontal direction (inferior-superior movement with respect to the patient).

In use, the patient is supine, the head is positioned on a thin foam pad between the lateral sights, and the neck is extended so that the outer canthus-external auditory canal baseline is 25° to the perpendicular. The head is immobilized by means of a restraining band, and the sights are adjusted over the center of the pupil in the AP projection and to the front surface of the cornea in the lateral. The x-ray tubes are then positioned with the central ray in the axes of the sighting devices.

The AP film is placed in a tunnel beneath the patient's head, and the lateral film positioned next to the head on the contralateral side from the eye being examined (fig. 1). Simultaneous biplane exposures are taken, if possible with the patient's eyes open and looking at the light beam collimator of the overhead tube. A focus-film distance of 1200 mm is

used for both projections to provide a standard magnification factor of 1.2:1 (fig. 2).

When necessary, plotting of the foreign body on an eye localization chart is achieved by taking direct measurements of the foreign body from the reference point (the pupil and front surface of the cornea) and transposing these measurements onto the chart after making appropriate allowance for magnification.

Advantages of the Localizer

The device can be used easily on severely injured patients or those with severely traumatized eyes because the patient remains supine and very little patient participation is required. Although the eye may be lacerated or the lid swollen shut, reasonable results can still be obtained by closely approxi-

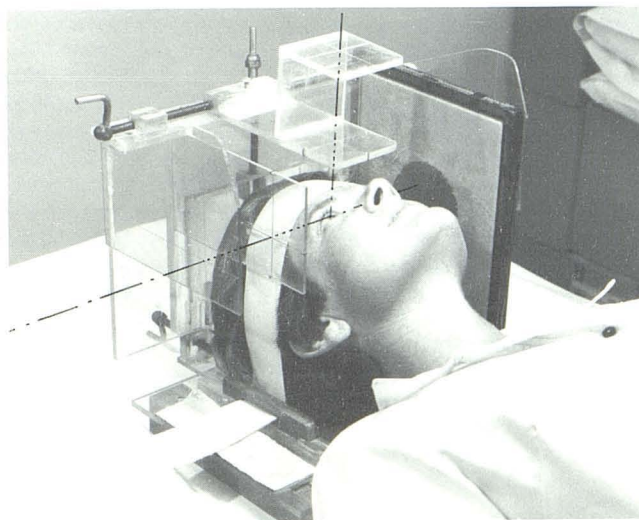


Fig. 1.—Patient positioned for localization of foreign body in right orbit, showing direction of central rays through sighting devices and position of lateral film cassette. For left eye localization, film cassette is positioned to patient's right side, and left lateral sights (obscured by the film cassette in this photograph) are used.

This article appears in the January/February 1984 issue of *AJNR* and the April 1984 issue of *AJR*.

¹ Department of Diagnostic Radiology, Royal Perth Hospital, Wellington St., Perth, Western Australia 6000. Address reprint requests to D. E. Hartley.

AJNR 5:53-54, January/February 1984 0195-6108/84/0501-0053 \$00.00 © American Roentgen Ray Society

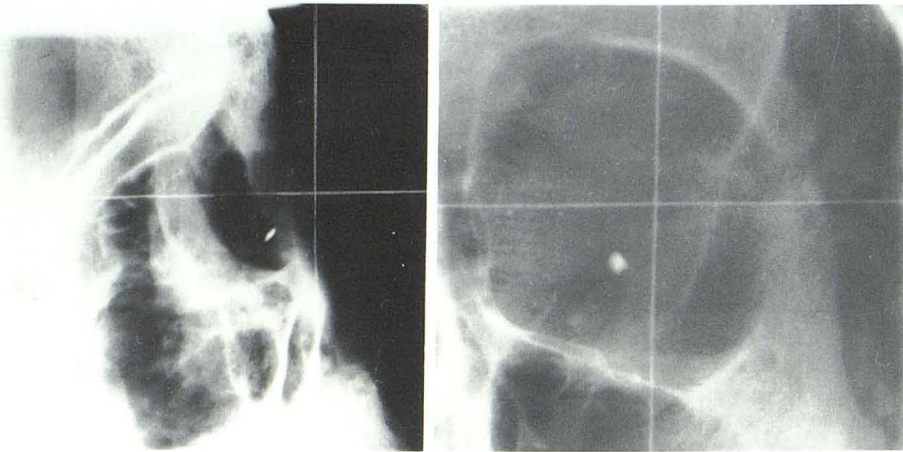


Fig. 2.—Typical pair of films showing cross wires superimposed on front surface of mid cornea.

inating the position of the pupil of the affected eye. (The patient is asked to look directly ahead with the good eye.)

An ophthalmologist can relate to the AP and lateral films without plotting the position of the foreign body on the eye localization chart. Because both films are obtained with the patient supine, the possibility of movement of the foreign body between localization and surgical removal is reduced.

After 10 years of use in about 80 examinations, there has been only one instance in which this localizer was not effec-

tive. In this case, with multiple intraocular foreign bodies of similar size and shape (shotgun pellets), it was impossible to identify individual shotgun pellets on both AP and lateral films. A stereoscopic method of localization was preferable. We recognize that CT may be of value, particularly in the localization of less dense foreign bodies (e.g., wood and glass). However, many hospitals do not have access to scanning facilities, or they may not be readily available for after-hours service.