

## Get Clarity On Generics

Cost-Effective CT & MRI Contrast Agents



FRESENIUS  
KABI

WATCH VIDEO

# AJNR

## Celebrating 35 Years of the AJNR: January 1988 edition

*AJNR Am J Neuroradiol* 2023, 44 (1) 115

doi: <https://doi.org/10.3174/ajnr.P6846>

<http://www.ajnr.org/content/44/1/115.citation>

This information is current as  
of August 21, 2025.

# Celebrating 35 Years of the AJNR

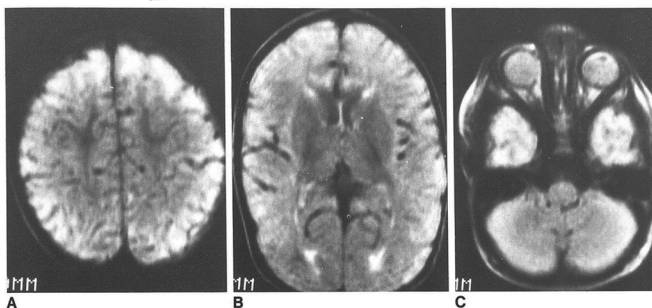
January 1988 edition

## MR Evaluation of Early Myelination Patterns in Normal and Developmentally Delayed Infants

Rosalind B. Dietrich<sup>1</sup>  
William G. Bradley<sup>2</sup>  
Edward J. Zaragoza IV<sup>1</sup>  
Ronald J. Otto<sup>2</sup>  
Ricky K. Taira<sup>3</sup>  
Gabriel H. Wilson<sup>1</sup>  
Hooshang Kangaroo<sup>1</sup>

This study demonstrates the ability of MR imaging to show progression in 64 infants and young children (ages 4 days to 36 months). T2 pulse sequences, frequently used for routine screening of intracranial lesions, were used. Gray-white matter differentiation was seen in all patients, and with age were documented. Three distinct patterns were seen, a established for each pattern in developmentally normal children: (1) normal (0-12 months); (2) isointense (8-12 months); and (3) early adult (10 months to 36 months). These data should be helpful for identifying and following sequelae of developmentally delayed children showing all three patterns. These data should be helpful for identifying and following sequelae of developmentally delayed children showing all three patterns.

Myelination is a dynamic process starting during intrauterine life and can thus be used as an index of brain maturation. True in the first 2 years, when changes are occurring most frequently when developmental delay is suspected clinically, opportunity to study myelination in vivo in normal and abnormal children and relative to a known standard. Such children are using combinations of long and short TR and long and short TE sequences. It is therefore imperative for the radiologist to be able to recognize the progression of myelination on these sequences if delay in myelination or abnormalities involving the white matter are to be detected and accurately diagnosed at the earliest possible time. It is also important that the



This article appears in the January 1988 issue of AJNR and the April 1988 issue of AJNR.

Received January 21, 1987; accepted July 15, 1987.

<sup>1</sup>Department of Radiological Sciences, School of Medicine, Los Angeles, CA. Address reprint requests to R. B. Dietrich.

<sup>2</sup>Huntington Medical Research Institute, CA 91105.

<sup>3</sup>Department of Radiology, University of California, Los Angeles, CA 90095.

© American Society of Neuroradiology

## 1.5-T MR Imaging of Pituitary Microadenomas: Technical Considerations and CT Correlation

Madan V. Kulkarni<sup>1</sup>  
K. Francis Lee<sup>1</sup>  
Craig G. McArdle<sup>1</sup>  
Joel W. Yasko<sup>1</sup>  
Floyd L. Haar<sup>2</sup>

Thirty-seven patients with suspected pituitary tumors were imaged with 1.5 T MR. MR detected a microadenoma at eight patients who underwent transphenoidal surgery, while 29 patients had no microadenoma. In only four of the eight patients clinically and endocrinologically considered to harbor a microadenoma, focal pituitary signal abnormality in 83% and CT demonstrated microadenoma in 42%. Infundibular displacement, focal gland convexity, and displacement of the infundibulum were seen equally well with CT and MR. MR imaging (T1-weighted spin-echo, coronal inversion-recovery, and coronal gated spin-echo images).

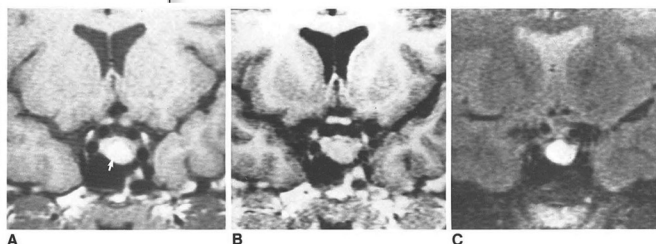
Although inversion-recovery images were superior in detecting microadenomas, coronal inversion-recovery images were better seen on T2-weighted images. MR imaging showed focal pituitary lesions better than any technique demonstrates MR's superior sensitivity to CT in detecting microadenomas.

CT has been widely used as an imaging method in the detection of pituitary tumors. High-resolution CT with IV contrast material, axial images with sagittal and coronal reformatting, and direct coronal imaging have shown the utility of CT in the imaging of the pituitary gland and its lesions [1-11]. Although indirect signs for the diagnosis of a pituitary microadenoma such as sellar floor erosion, focal convexity, and displacement of the infundibulum are well shown by CT, the detection of a focal hypo- or hyperdense lesion within the pituitary gland is the only statistically significant indicator of microadenoma [12]. However, microadenomas may reveal few or no abnormalities on CT [12, 13].

In recent years MR has also been useful in evaluating the pituitary gland [14-17]. High-resolution MR imaging has shown good results in the diagnosis of pituitary micro- and macroadenomas. However, in a recent comparative study, CT was found to be superior to MR in detecting microadenomas [18]. We prospectively evaluated patients with suspected pituitary tumors with MR and compared the results with available CT findings. The use of cardiac gated spin-echo and inversion-recovery techniques in diagnosing pituitary microadenomas was also evaluated. The imaging data were subsequently compared with clinical, endocrinological, and surgical data.

### Subjects and Methods

Thirty-seven patients with suspected pituitary tumors were examined. Six patients had pituitary lesions 10 mm or larger and were diagnosed as having pituitary macroadenomas. Of the 31 normomicroadenoma patients (27 women, four men) 22 had increased prolactin and one had elevated adrenocorticotropic hormone. Amenorrhea, infertility, and/or galactorrhea were common symptoms in female patients. One male patient with impotence and three male patients with galactorrhea were found to have elevated prolactin levels (30-500 mg/ml). Two



Received May 27, 1987; accepted after revision August 12, 1987.

Presented at the annual meeting of the American Society of Neuroradiology, New York, NY, May 1987.

<sup>1</sup>Department of Radiology, University of Texas Medical School at Houston and Hermann Hospital, 6431 Fannin, 2134 MSB, Houston, TX 77030.

Address reprint requests to M. V. Kulkarni.

<sup>2</sup>Department of Neurosurgery, University of Texas Medical School at Houston and Hermann Hospital, Houston, TX 77030.

AJNR 9:5-11, January/February 1988  
0195-6108/88/0901-0005  
© American Society of Neuroradiology