



Get Clarity On Generics

Cost-Effective CT & MRI Contrast Agents

**FRESENIUS
KABI**

WATCH VIDEO

AJNR

**Safety and Efficacy of Stent-Assisted Coiling
of Unruptured Intracranial Aneurysms Using
Low-Profile Stents in Small Parent Arteries**

J. Kim, H.J. Han, W. Lee, S.K. Park, J. Chung, Y.B. Kim
and K.Y. Park

This information is current as
of August 11, 2025.

AJNR Am J Neuroradiol 2021, 42 (9) 1621-1626

doi: <https://doi.org/10.3174/ajnr.A7196>

<http://www.ajnr.org/content/42/9/1621>

Safety and Efficacy of Stent-Assisted Coiling of Unruptured Intracranial Aneurysms Using Low-Profile Stents in Small Parent Arteries

J. Kim, H.J. Han, W. Lee, S.K. Park, J. Chung, Y.B. Kim, and K.Y. Park



ABSTRACT

BACKGROUND AND PURPOSE: Stent-assisted coiling of intracranial aneurysms arising from small vessels (≤ 2.0 mm) is a common procedure. However, data regarding its treatment outcomes are scarce. This study evaluated the clinical and radiologic outcomes of stent-assisted coiling using low-profile stents for aneurysms of small parent arteries.

MATERIALS AND METHODS: From November 2015 to October 2020, sixty-four patients with 66 aneurysms arising from parent arteries of ≤ 2.0 mm were treated with stent-assisted coiling using a Low-Profile Visualized Intraluminal Support Junior (LVIS Jr) or the Neuroform Atlas stent in a single institution. The clinical and radiologic data were retrospectively reviewed, and the risk factors for procedure-related complications were evaluated.

RESULTS: The LVIS Jr and Neuroform Atlas stents were used in 22 (33.3%) and 44 (66.7%) cases, respectively. Technical success was achieved in 66 cases (100%). Immediate postprocedural aneurysm occlusion grades assessed by the Raymond-Roy occlusion classification were I (57.6%), II (19.7%), and III (22.7%), respectively. Procedure-related complications occurred in 10 cases (15.2%), with 8 thromboembolic complications (12.1%) and 2 hemorrhagic complications (3.0%). Procedure-related morbidity was 4.5% without mortality. On multivariate analysis, current smoking (odds ratio = 7.1, $P = .021$) had a statistically significant effect on procedure-related complications.

CONCLUSIONS: Stent-assisted coiling of intracranial aneurysms with low-profile stents in small vessels (≤ 2.0 mm) had a 100% success rate and a 15.2% overall complication rate with 4.5% morbidity. Current smoking was a significant risk factor associated with procedure-related complications.

ABBREVIATIONS: PRU = P2Y12 reaction units; RR = Raymond-Roy occlusion classification; SAC = stent-assisted coiling

In the past decade, development in neuroendovascular devices and techniques has facilitated the successful treatment of intracranial aneurysms that had been previously considered challenging or uncoilable lesions.¹ Above all, stent-assisted coiling (SAC) is widely accepted as an effective and safe treatment technique for wide-neck intracranial aneurysms^{2,3} because it can also reduce recanalization and retreatment rates.⁴

However, previously used stent placement in small vessels was technically challenging due to the difficult navigation of larger (0.021- or 0.027-inch) delivery microcatheters to these small arteries.⁵⁻⁷

Recently, low-profile stents were introduced to improve the navigability and success rate of the procedure because they can be delivered via 0.0165- or 0.017-inch microcatheters to access tortuous and smaller vessels.⁸⁻¹⁰ Although the recommended use of the low-profile stents is for a parent artery with a diameter of either ≥ 2.0 or ≥ 2.5 mm, their off-label use for the treatment of aneurysms arising from smaller parent arteries has become more common.^{11,12} However, little is known about the efficacy and safety of SAC using low-profile stents in vessels smaller than 2.0 mm.

In the present study, we aimed to investigate the clinical and radiologic outcomes of SAC using low-profile stents for the treatment of unruptured intracranial aneurysms arising from small vessels with a diameter of ≤ 2.0 mm.

Received January 15, 2021; accepted after revision April 7.

From the Department of Neurosurgery (J.K., H.J.H., J.C., Y.B.K., K.Y.P.), Severance Stroke Center, and Department of Neurosurgery (W.L., S.K.P.), Gangnam Severance Hospital, Yonsei University College of Medicine, Seoul, Republic of Korea.

This study was approved by Severance Hospital institutional review board (4-2020-0765).

Please address correspondence to Keun Young Park, MD, Department of Neurosurgery, Severance Stroke Center, Yonsei University College of Medicine, 50 Yonsei-ro, Seodaemun-gu, Seoul 03722, Korea; e-mail: kypark78.md@gmail.com

Indicates article with online supplemental data.

<http://dx.doi.org/10.3174/ajnr.A7196>

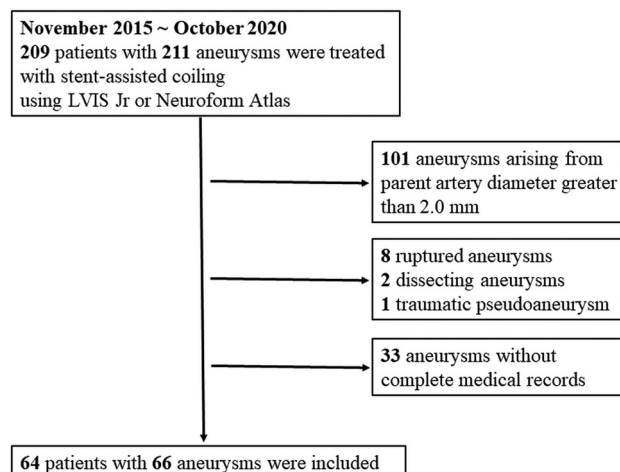


FIGURE. Inclusion and exclusion flow diagram.

MATERIALS AND METHODS

Study Design

This study was approved by our institutional review board. The need to obtain patient informed consent was waived because of the retrospective study design. The study was performed under the guidelines outlined by the Declaration of Helsinki and followed the STROBE checklist (<https://www.bmj.com/content/bmj/suppl/2021/03/10/bmj.n254.DC1/pelld062092.ww.pdf>).

Participants

In Korea, the Low-Profile Visualized Intraluminal Support Junior (LVIS Jr; MicroVention-Terumo) and the Neuroform Atlas (Stryker) stents are commercially available. Between November 2015 and October 2020, two hundred nine patients with 211 aneurysms were successfully treated by SAC with the LVIS Jr or Neuroform Atlas stents in a single institution. Data regarding aneurysms arising from parent arteries of ≤ 2 mm were extracted from a prospectively maintained aneurysm data base. Exclusion criteria were as follows: 1) patients with ruptured, traumatic, or vasculopathy-related aneurysms, and 2) patients with incomplete medical records or radiologic data. Finally, 64 patients with 66 aneurysms were included (Figure). The vessel-diameter measurements were made from postprocessed 3D rotational images. Patient and aneurysm characteristics, clinical outcomes, and radiologic follow-up results were obtained from electronic medical records and a prospectively registered aneurysm database. These data were retrospectively reviewed.

Endovascular Procedures and Antiplatelet Protocol

Therapeutic decisions were made by a multidisciplinary team of neurosurgeons and neurointerventionalists via consensus. Before the procedure, dual antiplatelet therapy with aspirin (100 mg once daily) plus clopidogrel (75 mg once daily) was administered to each patient for at least 5 days. Platelet function tests were conducted using the VerifyNow P2Y12 assay (Accumetrics) to measure the P2Y12 reaction units (PRU). Patients with PRU of >220 were considered clopidogrel hyporesponders¹³ and were administered supplementary cilostazol (100 mg twice daily). For patients without any antiplatelet premedication, a loading dose of

aspirin (300 mg) and clopidogrel (300 mg) was administered 1 day before or on the day of the procedure.

All procedures were performed with the patient under general anesthesia. The femoral artery was the primary target puncture site. The LVIS Jr and the Neuroform Atlas were delivered via either Headway 17 (MicroVention-Terumo) or Excelsior SL-10 (Stryker) microcatheters and were deployed using a standard procedure. Y-configuration stent placement was conducted at the operator's discretion. Coiling of the aneurysm was performed using the jailing technique ($n = 59$, 86.4%) or cell-through technique ($n = 7$, 13.6%). During the procedure, IV unfractionated heparin (3000 IU) was injected after the sheath was inserted into the femoral artery and a bolus of 1000 IU was administered every hour. When thrombus formation was noted during the procedure, intra-arterial tirofiban (0.3–1.0 mg) was injected for thrombolysis.

After the procedure, the dual antiplatelet therapy was maintained for at least 3 months unless contraindicated. Thereafter, aspirin monotherapy was continued indefinitely.

Clinical and Radiologic Follow-up

Clinical follow-up was routinely conducted at 1 and 3 months after the procedure. Routine imaging follow-ups were performed with either MRA or DSA, 1, 2, and 4 years after the procedure.

Outcome Measurements

Procedure-related complications were defined as any thromboembolic and hemorrhagic complications that occurred within 90 days, irrespective of the presence of symptoms. Thromboembolic complications included intraprocedural thromboembolism diagnosed when the contrast in a vessel stagnated, nonvisualization of the distal artery occurred, a luminal filling defect was noted during the procedure, or cerebral infarction or a transient ischemic attack occurred in a territory relevant to the procedure. Hemorrhagic complications were diagnosed when any sign of contrast leakage during the procedure was noted due to rupture of the aneurysm or vessels or when any immediate or delayed intracranial hemorrhage occurred. Clinical outcomes were assessed at the outpatient clinic using the mRS. Unfavorable outcomes were defined as a 90-day mRS score of ≥ 3 . Immediate and follow-up radiologic outcomes were assessed using the Raymond-Roy occlusion classification (RR), in which class I is defined as complete occlusion; class II, as a neck remnant; and class III, as a sac remnant.¹⁴ The procedural success rate and in-stent stenosis ($> 50\%$) were also evaluated.

Statistical Analysis

Statistical analysis was performed using SPSS Statistics 25.0 (IBM). Fisher exact tests or χ^2 tests were performed for categorical variables. Mann-Whitney tests or Student *t* tests were performed for continuous variables of clinical outcomes of SAC and for the univariate analysis of the risk factors for procedure-related complications. All variables with clinical importance were introduced into a multivariate analysis using the binary logistic regression method. A *P* value $< .05$ was considered statistically significant.

Table 1: Details of endovascular procedures

Variables	Values
Platelet function test	
PRU (SD)	187.7 (67.1)
Clopidogrel hyporesponder (No.) (%)	23 (34.8) ^a
Stent type (No.) (%)	
LVIS Jr	22 (33.3)
Neuroform Atlas	44 (66.7)
No. of stents (No.) (%)	
1	59 (89.4)
2	7 (10.6) ^b

^aModified with cilostazol (100 mg twice daily).^bIncluding 6 Y-stent placements.

RESULTS

Patients and Aneurysms

Sixty-four patients (mean age, 60.5 years; male/female ratio = 21:43) with 66 unruptured aneurysms (61 incidental and 5 recurrent) were treated. The aneurysms were located in the anterior cerebral artery ($n = 46$, 69.7%), MCA ($n = 15$, 22.7%), and vertebrobasilar artery ($n = 5$, 7.6%). The median aneurysm size was 4.59 mm (interquartile range, 3.74–6.85 mm). The median parent artery diameter was 1.78 mm (interquartile range, 1.63–1.90 mm), and the smallest diameter was 1.15 mm. These characteristics are described in the Online Supplemental Data.

Endovascular Procedures

The total number of procedures was 66 (LVIS Jr, 22; Neuroform Atlas, 44). Twenty-three (34.8%) clopidogrel hyporesponders were administered cilostazol. Among the 7 cases in which 2 stents were deployed, Y-stent placement using identical stents was performed in 6 patients. These characteristics are described in Table 1.

Immediate Postprocedural, Radiologic, and Clinical Outcomes

Stent deployment was successful in 66 cases (100.0%). Immediately after the procedure, the aneurysm occlusion grade was RR I ($n = 38$, 57.6%), RR II ($n = 13$, 19.7%), and RR III ($n = 15$, 22.7%). The procedure-related complications occurred in 9 cases (13.6%) within the first 7 days of the procedure, including 7 (10.6%) thromboembolic and 2 (3.0%) hemorrhagic complications. Among 7 thromboembolic complications, 6 cases of in-stent thrombosis were identified during the procedure and completely controlled using intra-arterial and IV tirofiban infusion, and none were symptomatic. However, 1 patient with a distal anterior cerebral artery aneurysm experienced thrombus formation during the procedure, which could not be sufficiently controlled, resulting in an acute anterior cerebral artery territory infarction (mRS 4). Hemorrhagic complications were observed in 2 patients. One patient with an anterior communicating artery aneurysm was successfully treated without any procedural events, but subarachnoid hemorrhage was diagnosed 12 hours after the procedure. It is suspected that the aneurysm was ruptured during the cell-through procedure, but the contrast leakage was not noticed during the procedure. The patient was treated with external ventricular drainage and discharged with an mRS score of 4. Another patient experienced an intraprocedural rupture of a distal anterior cerebral artery aneurysm and was discharged with an mRS score of 5 (Table 2).

Table 2: Procedure-related complications and 90-day clinical outcomes

Clinical Outcomes	Values
Procedure-related complications (No.) (%)	10 (15.2)
Thromboembolism	8 (12.1) ^a
Hemorrhage	2 (3.0)
Unfavorable outcome (mRS ≥ 3) (No.) (%)	3 (4.5)
Procedure-related mortality (No.) (%)	0

^aIncluding 7 asymptomatic cases.**Table 3: Radiologic outcomes**

Aneurysm Occlusion Classification	Values
Immediate postprocedural (No.) (%)	
RR I	38 (57.6)
RR II	13 (19.7)
RR III	15 (22.7)
Follow-up occlusion (median, 12.1 mo) (No.) (%)	
RR I	51 (87.9)
RR II	4 (6.9)
RR III	3 (5.2)
Recurrence (No.) (%)	2 (3.4%) ^a
In-stent stenosis (No.) (%)	0 (0%)

^aNeither of these patients required retreatment.

Follow-up Radiologic and Clinical Outcomes

Follow-up images were available for 58 aneurysms (90.5%; DSA, 15; MRA, 43; median, 12.1 months). During the follow-up, RR I was achieved for 51 aneurysms (87.9%), RR II was achieved for 4 aneurysms (6.9%), and RR III was achieved for 3 aneurysms (5.2%). Recurrence was noted in 2 patients (3.4%), neither of whom required retreatment. No case of in-stent stenosis ($>50\%$) occurred among the 15 patients with DSA follow-up (median, 17.1 months) (Table 3). A delayed procedure-related complication occurred in 1 patient who experienced acute embolic infarction in the left frontal lobe 2 months after undergoing stent-assisted coiling of a left MCA bifurcation aneurysm, resulting in mild dysarthria (mRS 2). Overall, 3 patients had unfavorable outcomes 90 days postprocedure, resulting in 4.5% morbidity. There was no procedure-related mortality.

Risk Factors Associated with Procedure-Related Complications

Current smoking ($P = .042$) was statistically associated with procedure-related complications on univariate analysis (Online Supplemental Data). On multivariate analysis, current smoking ($OR = 7.1$; 95% CI, 1.35–37.50; $P = .021$) was the only statistically significant factor. The aneurysm characteristics, parent artery diameter, stent type, and complete aneurysm occlusion were not associated with an increased risk of procedure-related complications (Table 4).

DISCUSSION

In the current study of patients who underwent SAC using low-profile stents (LVIS Jr and Neuroform Atlas) for unruptured intracranial aneurysms arising from small vessels (≤ 2.0 mm), the immediate postprocedural occlusion grades were RR I ($n = 38$, 57.6%), RR II ($n = 13$, 19.7%), and RR III ($n = 15$, 22.7%) and

Table 4: Multivariate analysis of risk factors for procedure-related complications

Variables	Odds Ratio	95% Wald CI	P Value
Age	1.08	0.99–1.19	.086
Female sex	5.38	0.61–47.72	.131
Current smoking	7.10	1.35–37.50	.021 ^a
Diabetes mellitus	3.25	0.15–72.60	.457
Cardiovascular disease	2.24	0.15–33.63	.560
Parent artery diameter	18.40	0.126–2694.60	.252
RR I	2.30	0.23–22.94	.478

^aStatistically significant.

technical success was achieved in all 66 cases. Within 90 days, procedure-related complications occurred in 10 cases (15.2%) and unfavorable outcomes were noted in 3 patients (4.5%), without mortality. The aneurysm occlusion grade was RR I or II in 55 cases (94.8%) at the last follow-up (median, 12.1 months), with a 3.4% recurrence rate.

Stent-assisted coiling is widely accepted for the treatment of wide-neck, artery-incorporated, and fusiform intracranial aneurysms. However, stent placement in small vessels using earlier stents with higher profiles remains technically challenging because these stents should be delivered via a 0.021- or 0.027-inch microcatheter, which sometimes requires an exchange technique using a 300-cm exchangeable wire.¹⁵ On the other hand, the ability of the low-profile stents to be delivered via a 0.0165- or 0.017-inch microcatheter offers an advantage when treating aneurysms arising from narrow and tortuous vessels. In the previous study of Kühn et al,¹⁶ a 93.2% (41/44) technical success rate was reported in SAC using Neuroform (Stryker) or Enterprise (Codman & Shurtleff) stents in small vessels of ≤ 2 mm. Our current study showed a higher technical success rate of 100%. Furthermore, SAC using low-profile stents for aneurysms at complex and acute-angled vasculature has also been reported. In a study of anterior communicating artery aneurysms treated with the LVIS Jr, Santillan et al¹⁷ reported a 96.0% (24/25) technical success rate. Similarly, Samaniego et al¹⁸ attempted treating PICA aneurysms with the LVIS Jr and suggested its feasibility in their case series.

Although SAC using low-profile stents seems feasible even in small vessels, the risk of procedure-related complications remains a major concern regarding stent placement because deploying stents in a small, tortuous vessel may be complicated by poor wall apposition and increased metal coverage, all of which may lead to thromboembolism. Several studies have reported treatment outcomes of SAC using earlier versions (higher profile) of Neuroform or Enterprise stents in small vessels (Online Supplemental Data). Kühn et al¹⁶ reported their experience of SAC using Enterprise and Neuroform stents in parent arteries of ≤ 2.0 mm, with 13.6% thromboembolic and 2.3% hemorrhagic complications. Chung et al¹⁹ also investigated 31 cases of SAC using Enterprise stents in parent arteries of < 2.0 mm and found thromboembolic complications without hemorrhagic complications in 9.7% of the cases. Recently, for the evaluation of low-profile stents in small vessels, Wang et al²⁰ evaluated 22 aneurysms treated using the LVIS Jr and reported 4.5% hemorrhagic and no thromboembolic complications. Another study of LVIS Jr by Santillan et al²¹ also showed 11.4% thromboembolic complications and 2.8% hemorrhagic complications in their 35 case series. However, in these 2 studies, small parent arteries

were defined as vessels smaller than 2.5 mm.^{20,21} Furthermore, they included only a small number of cases (22 and 35, respectively).

To the best of our knowledge, our study is the first and largest study including 66 aneurysms treated by SAC using low-profile stents in small vessels of ≤ 2.0 mm and showing 12.1% thromboembolic and 3.0% hemorrhagic complications (morbidity, 4.5%; mortality, 0). These complication rates were comparable with those in previous studies of low-profile stents with a larger sample size.^{11,22–24} In a study of 80 cases of SAC using Leo Baby stents (Balt Extrusion), Aydin et al²² reported an overall complication rate of 8.8% and 3.8% morbidity without mortality. Similarly, Alghamdi et al¹¹ reported 10% thromboembolic and 2.5% hemorrhagic complications, resulting in 5% morbidity and 0% mortality in 43 SAC cases using the LVIS Jr. A recent multicenter study of Neuroform Atlas demonstrated a major stroke rate of 4.4%, with a 2.2% permanent morbidity rate and a 0.5% mortality rate.²³ In a systematic review, Park et al²⁴ reported a periprocedural complication rate of 12.4% and procedure-related morbidity between 0% and 5.5% with low-profile stents (LVIS Jr and Leo Baby). Currently, low-profile stents demonstrate procedure-related complication rates comparable with those of higher-profile stents.

Several studies have investigated the risk factors associated with procedure-related complications in SAC of intracranial aneurysms.^{25,26} Complications related to stent placement have been more thoroughly evaluated in the cardiology field, in which smoking is a strong risk factor for in-stent thrombosis after percutaneous coronary intervention,²⁷ because smokers tend to be at higher thrombogenic risk. In the present study, current smoking was an independent risk factor for procedure-related complications during and after SAC in small vessels (≤ 2.0 mm). This finding is contradictory to the concept of “smoker’s paradox.” Reed et al²⁸ demonstrated that smokers exhibit lower PRU than nonsmokers when treated with clopidogrel. In the present study, however, smokers showed higher PRU than nonsmokers, without statistical significance (233.6 versus 181.1, $P = .06$). Perhaps smoking does not universally reduce platelet reactivity due to the cytochrome P450 genotype-dependent effect of smoking on clopidogrel responsiveness.²⁹ Because most of the procedure-related complications were intraoperative thromboembolism, the mechanical stress exerted by the deployment of a stent on the endothelium, which was already affected by noxious stimuli such as smoking,³⁰ might contribute to immediate thrombus formation. Whether smaller vessels are more vulnerable to these risk factors remains to be elucidated.

Individual responses to clopidogrel are varied, and hyporesponse is commonly reported. Unfortunately, hyporesponse to clopidogrel increases the risk of thromboembolic events. In the present study, though statistically not significant, PRU mean value was higher in the procedure-related complication group (206.60 versus 184.24, $P = .337$). Recently, newer antiplatelet agents such as ticagrelor or prasugrel have been considered alternatives for clopidogrel hyporesponders to reduce the risk of periprocedural thromboembolic complications.^{31,32} However, in the present study, cilostazol was added to the clopidogrel hyporesponders on the basis of the initial platelet function test because ticagrelor and prasugrel were not approved by the Ministry of

Food and Drug Safety in Korea for use in neuroendovascular procedures. We did not repeat the platelet function test after administering cilostazol, so it is not clear whether the higher baseline PRU of the patients with procedure-related complications increased the risk of thromboembolic complications; however, analysis of the effects of conventional dual-antiplatelet agents plus cilostazol and the newer antiplatelet regimen would provide valuable knowledge for the management of clopidogrel hyporesponders.

In this study, all patients, identically, received 3000 IU of IV heparin initially and additional 1000 IU of IV heparin every hour during the procedure. Because the antithrombotic effect of heparin measured by activated clotting time varies among individuals, monitoring of the heparin response and patient-tailored dose selection would have lowered the thromboembolic complication rate.

Our study has several limitations. First, this was a retrospective study with a relatively small sample size of unruptured aneurysms collected from a single institution. Thus, selection bias cannot be avoided regarding the demographics and percentages observed. Furthermore, the risk-factor analysis is not supported by high statistical power due to the small sample size. Nevertheless, to the best of our knowledge, this study was performed with the largest sample gathered from a single center, and to reduce selection bias, we included 64 consecutive patients treated with low-profile stents for unruptured cerebral aneurysms arising from small vessels. Another limitation was the lack of long-term follow-up. Therefore, further studies are needed in larger populations treated with SAC using low-profile stents to assess long-term safety and durability.

CONCLUSIONS

This study demonstrates that off-label use of low-profile stents in the SAC of unruptured intracranial aneurysms arising from parent arteries of ≤ 2.0 mm is feasible and relatively safe, with a good aneurysm occlusion rate and an acceptable complication rate.

ACKNOWLEDGMENTS

We would like to thank the Biostatistics Collaboration Unit of Yonsei University College of Medicine for statistical consultation and Editage (www.editage.co.kr) for English language editing.

REFERENCES

- Wang AS, Campos JK, Colby GP, et al. Cerebral aneurysm treatment trends in National Inpatient Sample 2007–2016: endovascular therapies favored over surgery. *J Neurointerv Surg* 2020;12:957–63 [CrossRef Medline](#)
- Park KY, Kim BM, Kim DJ, et al. Y-configuration stenting for coiling of wide-neck bifurcation aneurysms using Low-profile Visualized Intraluminal Support Junior. *J Neurointerv Surg* 2019;11:400–04 [CrossRef Medline](#)
- Tähtinen OI, Vanninen RL, Manninen HI, et al. Wide-necked intracranial aneurysms: treatment with stent-assisted coil embolization during acute (<72 hours) subarachnoid hemorrhage—experience in 61 consecutive patients. *Radiology* 2009;253:199–208 [CrossRef Medline](#)
- Hong Y, Wang YJ, Deng Z, et al. Stent-assisted coiling versus coiling in treatment of intracranial aneurysm: a systematic review and meta-analysis. *PLoS One* 2014;9:e82311 [CrossRef Medline](#)
- Huang Q, Liu J, Zhao R, et al. The safety and efficacy of stenting in the treatment of complex posterior cerebral artery aneurysms: a seven-case report and literature review. *Clin Neuroradiol* 2013;23:175–87 [CrossRef Medline](#)
- Roh HG, Chun YI, Choi JW, et al. Retrograde stent placement for coil embolization of a wide-necked posterior inferior cerebellar artery aneurysm. *Korean J Radiol* 2012;13:510–14 [CrossRef Medline](#)
- Zhang J, Lv X, Jiang C, et al. Endovascular treatment of cerebral aneurysms with the use of stents in small cerebral vessels. *Neurol Res* 2010;32:119–22 [CrossRef Medline](#)
- Shankar JJS, Quateen A, Weill A, et al. Canadian Registry of LVIS Jr for Treatment of Intracranial Aneurysms (CaRLA). *J Neurointerv Surg* 2017;9:849–53 [CrossRef Medline](#)
- Grossberg JA, Hanel RA, Dabus G, et al. Treatment of wide-necked aneurysms with the low-profile visualized intraluminal support (LVIS Jr) device: a multicenter experience. *J Neurointerv Surg* 2017;9:1098–102 [CrossRef Medline](#)
- Burkhardt JK, Srinivasan V, Srivatsan A, et al. Multicenter postmarket analysis of the Neuroform Atlas stent for stent-assisted coil embolization of intracranial aneurysms. *AJNR Am J Neuroradiol* 2020;41:1037–42 [CrossRef Medline](#)
- Alghamdi F, Mine B, Morais R, et al. Stent-assisted coiling of intracranial aneurysms located on small vessels: midterm results with the LVIS Junior stent in 40 patients with 43 aneurysms. *Neuroradiology* 2016;58:665–71 [CrossRef Medline](#)
- ten Brinck MF, de Vries J, Bartels RHMA, et al. NeuroForm Atlas stent-assisted coiling: preliminary results. *Neurosurgery* 2019;84:179–89 [CrossRef Medline](#)
- Kim CH, Hwang G, Kwon OK, et al. P2Y12 reaction units threshold for implementing modified antiplatelet preparation in coil embolization of unruptured aneurysms: a prospective validation study. *Radiology* 2017;282:542–51 [CrossRef Medline](#)
- Roy D, Milot G, Raymond J. Endovascular treatment of unruptured aneurysms. *Stroke* 2001;32:1998–2004 [CrossRef Medline](#)
- Akpek S, Arat A, Morsi H, et al. Self-expandable stent-assisted coiling of wide-necked intracranial aneurysms: a single-center experience. *AJNR Am J Neuroradiol* 2005;26:1223–31 [Medline](#)
- Kühn AL, Hou SY, Puri AS, et al. Stent-assisted coil embolization of aneurysms with small parent vessels: safety and efficacy analysis. *J Neurointerv Surg* 2016;8:581–85 [CrossRef Medline](#)
- Santillan A, Schwarz J, Boddu S, et al. Stent-assisted coil embolization of anterior communicating artery aneurysms using the LVIS Jr stent. *Interv Neuroradiol* 2019;25:12–20 [CrossRef Medline](#)
- Samaniego EA, Abdo G, Hanel RA, et al. Endovascular treatment of PICA aneurysms with a low-profile visualized intraluminal support (LVIS Jr) device. *J Neurointerv Surg* 2016;8:1030–33 [CrossRef Medline](#)
- Chung J, Suh SH, Hong CK, et al. Preliminary experience with self-expanding closed-cell stent placement in small arteries less than 2 mm in diameter for the treatment of intracranial aneurysms. *J Neurosurg* 2015;122:1503–10 [CrossRef Medline](#)
- Wang CC, Li W, Feng ZZ, et al. Preliminary experience with stent-assisted coiling of aneurysms arising from small (<2.5 mm) cerebral vessels using the low-profile visualized intraluminal support device. *AJNR Am J Neuroradiol* 2017;38:1163–68 [CrossRef Medline](#)
- Santillan A, Boddu S, Schwarz J, et al. LVIS Jr. stent for treatment of intracranial aneurysms with parent vessel diameter of 2.5 mm or less. *Interv Neuroradiol* 2018;24:246–53 [CrossRef Medline](#)
- Aydin K, Arat A, Sencer S, et al. Stent-assisted coiling of wide-neck intracranial aneurysms using low-profile Leo Baby stents: initial and midterm results. *AJNR Am J Neuroradiol* 2015;36:1934–41 [CrossRef Medline](#)
- Zaidat OO, Hanel RA, Sauvageau EA, et al. Pivotal trial of the Neuroform Atlas stent for treatment of anterior circulation aneurysms: one-year outcomes. *Stroke* 2020;51:2087–94 [CrossRef](#)

24. Park SY, Oh JS, Oh HJ, et al. **Safety and efficacy of low-profile, self-expandable stents for treatment of intracranial aneurysms: initial and midterm results—a systematic review and meta-analysis.** *Interv Neurol* 2017;6:170–82 [CrossRef Medline](#)
25. Adeeb N, Griessenauer CJ, Moore JM, et al. **Ischemic stroke after treatment of intraprocedural thrombosis during stent-assisted coiling and flow diversion.** *Stroke* 2017;48:1098–100 [CrossRef Medline](#)
26. Zuo Q, Yang P, Lv N, et al. **Safety of coiling with stent placement for the treatment of ruptured wide-necked intracranial aneurysms: a contemporary cohort study in a high-volume center after improvement of skills and strategy.** *J Neurosurg* 2019;131:435–41 [CrossRef Medline](#)
27. Faxon DP, Fuster V, Libby P, et al. **Atherosclerotic vascular disease conference: writing group III: pathophysiology.** *Circulation* 2004;109:2617–25 [CrossRef Medline](#)
28. Reed GW, Cannon CP, Waalen J, et al. **Influence of smoking on the antiplatelet effect of clopidogrel differs according to clopidogrel dose: Insights from the GRAVITAS trial.** *Catheter Cardiovasc Interv* 2017;89:190–98 [CrossRef Medline](#)
29. Park KW, Park JJ, Jeon KH, et al. **Enhanced clopidogrel responsiveness in smokers: smokers' paradox is dependent on cytochrome P450 CYP1A2 status.** *Arterioscler Thromb Vasc Biol* 2011;31:665–71 [CrossRef Medline](#)
30. Michael PR. **Cigarette smoking, endothelial injury and cardiovascular disease.** *Int J Exp Pathol* 2000;81:219–30 [CrossRef Medline](#)
31. Cho WS, Lee J, Ha EJ, et al. **Low-dose prasugrel vs clopidogrel-based tailored premedication for endovascular treatment of cerebral aneurysms.** *Neurosurgery* 2019;85:E52–59 [CrossRef Medline](#)
32. Kim KS, Fraser JF, Grupke S, et al. **Management of antiplatelet therapy in patients undergoing neuroendovascular procedures.** *J Neurosurg* 2018;129:890–05 [CrossRef Medline](#)