



## Get Clarity On Generics

Cost-Effective CT & MRI Contrast Agents

 FRESENIUS  
KABI

[WATCH VIDEO](#)

# AJNR

## Diagnostic Value of "Mushroom" Morphology in Vertebral Chordoma

T.S. Ghosh, S. Tiwari, P.K. Garg, P.S. Khera and P. Elhence

*AJNR Am J Neuroradiol* 2021, 42 (3) E15-E16

doi: <https://doi.org/10.3174/ajnr.A6947>

<http://www.ajnr.org/content/42/3/E15>

This information is current as  
of August 12, 2025.

# Diagnostic Value of “Mushroom” Morphology in Vertebral Chordoma

We read with great interest the recently published article “Exophytic Lumbar Vertebral Body Mass in an Adult with Back Pain.” We thank John C. Benson et al<sup>1</sup> for their lucid description of imaging features of chordoma presenting as an exophytic lumbar vertebral mass. We recently encountered a similar case and would like to add few points related to this pathology.

Our patient, 68 years old male, presented with a history of low back pain for the previous 3 years. The initial spine MR imaging done 3 years earlier showed a small L4 lesion (Figure A, B) confined to the vertebral body itself without any extraosseous component. He was provisionally diagnosed with vertebral hemangioma and managed conservatively with intermittent analgesics. A recent aggravation of his low back pain and new-onset paresthesia of bilateral lower limbs made him seek medical attention at our institute, and he underwent repeat imaging.

The MR imaging (Figure C, D) revealed an exophytic L4 vertebral body lesion with an extraosseous soft tissue component remarkably similar to the mass described in the Benson et al<sup>1</sup> article. The appearance on the noncontrast imaging mimicked an aggressive hemangioma with expansile extraosseous soft tissue component and preserved vertically oriented bony trabeculae. However, the dynamic time-resolved imaging of contrast kinetics (TRICKS) MR image did not show any arterial phase early enhancement or any prominent artery supplying the lesion, which was against the diagnosis of vertebral hemangioma (Figure E, F). An imaging differential of chordoma was considered,<sup>2</sup> and it was decided to proceed with CT-guided Tru-Cut (Merit Medical) biopsy. On histopathology, the lesion was proved to be chordoma.

Regarding the imaging, we would like to add a couple of inputs that we have learned from this case to differentiate chordoma from other differential diagnoses.

First, the noncontrast CT and MR images in vertebral chordoma may be confused with aggressive vertebral hemangioma. A dynamic TRICKS MR image may prove helpful in differentiating this condition by showing lack of early arterial enhancement and lack of a prominent feeding vessel<sup>3</sup> (Figure E, F).

Second, as mentioned in the article, chordoma typically spares the adjoining intervertebral discs, but in our case, it showed few focal areas of involvement of adjoining IV discs (Figure C, D), suggestive of its locally aggressive nature.


Third, our case demonstrates the natural history of vertebral chordoma over a 3-year duration. It originated from the mid L4 vertebral body, had slow growth, and later progressed to a large vertebral mass with a dumbbell- or mushroom-shaped exophytic paravertebral extension.

Finally, a biopsy from a suspected vertebral chordoma is not encouraged because of the risk of recurrence along the biopsy tract. In our case, to prevent such an event, embolization of the biopsy tract with doxorubicin beads was done.

In conclusion, despite being an exceedingly rare entity, chordoma should be considered as a differential for exophytic vertebral body lesion with extraosseous soft tissue component along with other differential diagnoses as mentioned by Benson et al.<sup>1</sup>


## REFERENCES

1. Benson JC, Vizcaino MA, Kim DK, et al. **Exophytic lumbar vertebral body mass in an adult with back pain.** *AJNR Am J Neuroradiol* 2020;41:1786–90 [CrossRef Medline](#)
2. Smolders D, Wang X, Drevelengas A, et al. **Value of MRI in the diagnosis of non-clival, non-sacral chordoma.** *Skeletal Radiol* 2003; 32:343–50 [CrossRef Medline](#)
3. Hurley MC, Gross BA, Surdell D, et al. **Preoperative Onyx embolization of aggressive vertebral hemangiomas.** *AJNR Am J Neuroradiol* 2008;29:1095–97 [CrossRef Medline](#)

 T.S. Ghosh

 S. Tiwari

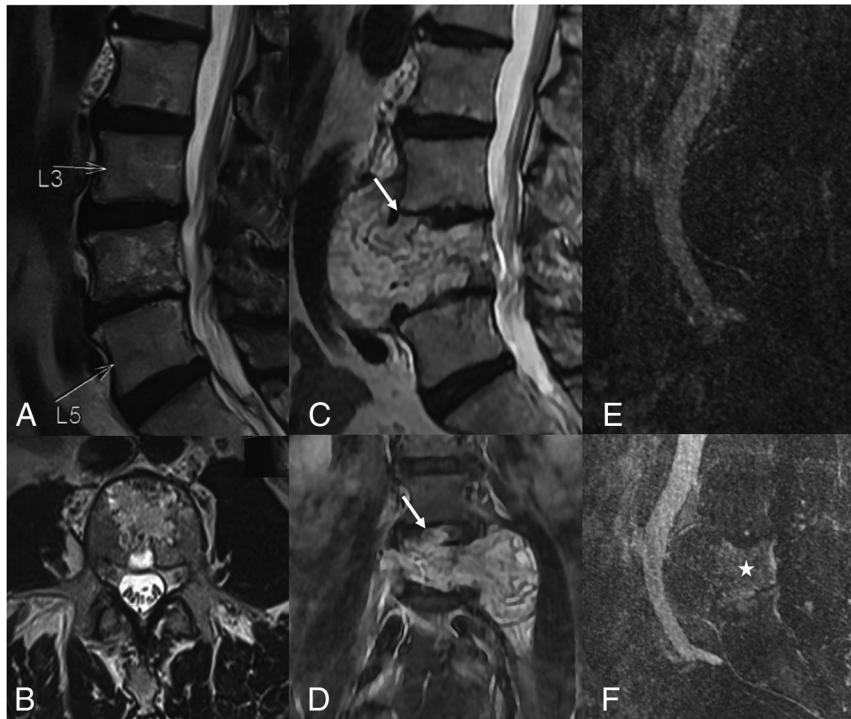 P.K. Garg

 P.S. Khara

Department of Diagnostic and Interventional Radiology  
All India Institute of Medical Sciences, Jodhpur  
Rajasthan, India

 P. Elhence

Department of Pathology  
All India Institute of Medical Sciences, Jodhpur  
Rajasthan, India



**FIGURE.** The T2 sagittal (A) and axial (B) MR images done in December 2017 show a nonexophytic and centrally located T2 hyperintense lesion, confined to the L4 vertebral body outline without any extraosseous soft tissue. Repeat T2 sagittal (C) and coronal (D) MR imaging in August 2020 shows increase in the size of mass. The mass is centered within the body of vertebra with an exophytic component extending to the left lateral aspect causing smooth displacement of the psoas major muscle. Note the focal areas of infiltration of adjoining intervertebral disc (*white arrows*) by the tumor. The sagittal dynamic TRICKS MR image arterial phase (E) shows no early enhancement or any dominant feeder to the mass. The venous phase of angiogram (F) shows mild diffuse tumoral enhancement of the lesion.