

Get Clarity On Generics

Cost-Effective CT & MRI Contrast Agents



FRESENIUS
KABI

WATCH VIDEO

AJNR

Perspectives

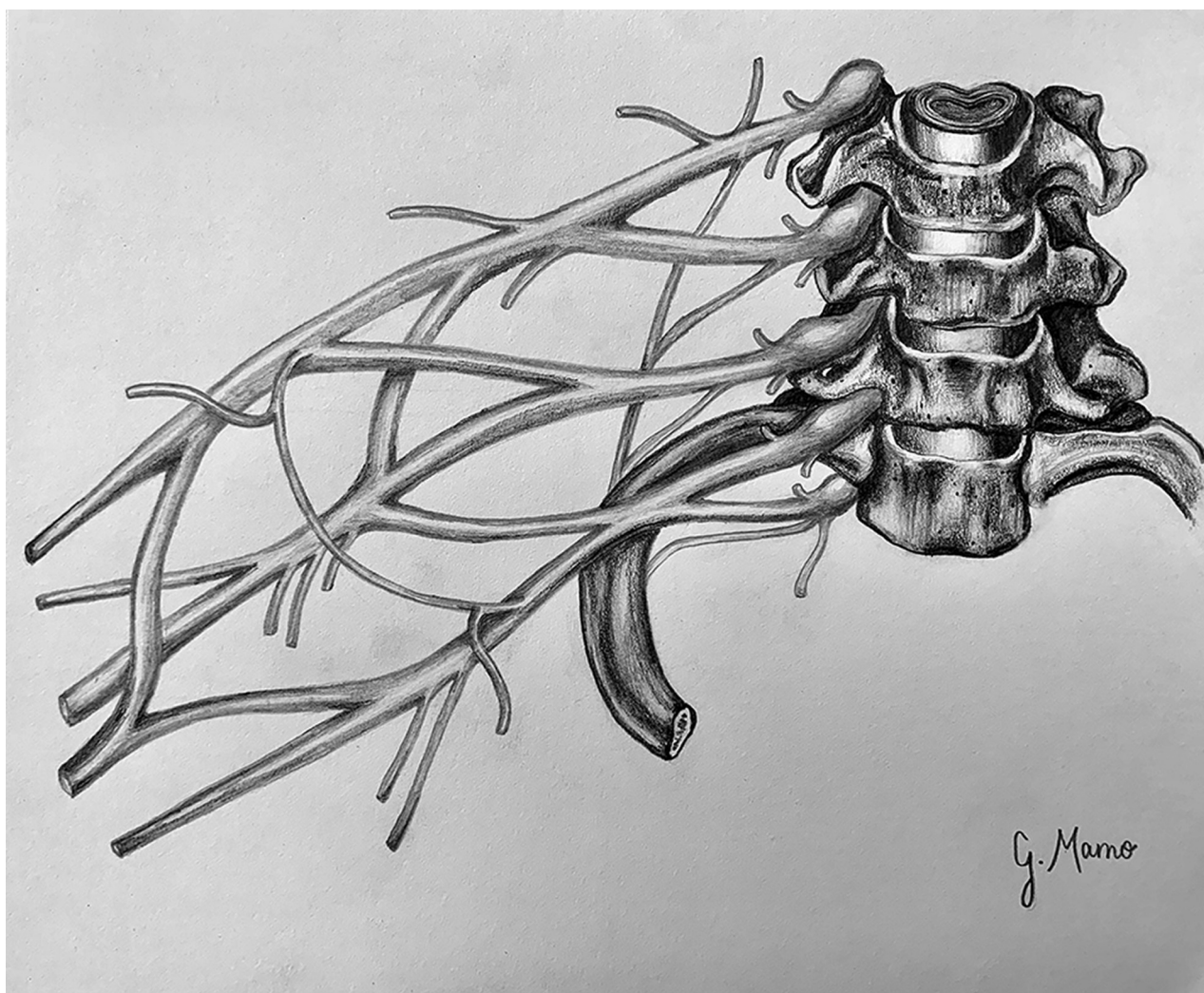
Gabriella Mamo

AJNR Am J Neuroradiol 2021, 42 (10) 1741

doi: <https://doi.org/10.3174/ajnr.P0115>

<http://www.ajnr.org/content/42/10/1741>

This information is current as
of August 11, 2025.



Title: Brachial Plexus. Whether it is the crucial attention in tasks or the everlasting need for a keen eye, radiology will continue to be a field that requires precision and a focus on fine detail. As a medical student also striving to embrace my artistic abilities, particularly in human anatomy, it is essential that I am detail-oriented with my work in order to illustrate the various organ systems as realistically as possible. I will always seek to bring life to 2-dimensional images on paper, much like radiologists must interpret 2-dimensional images on a screen, correlating them to real human life. This piece uses pencil on paper to depict the various nerves of the brachial plexus and vertebrae C5 to T1.

Gabriella Mamo, Philadelphia College of Osteopathic Medicine