



## Get Clarity On Generics

Cost-Effective CT & MRI Contrast Agents



FRESENIUS  
KABI

WATCH VIDEO

# AJNR

## Celebrating 35 Years of the AJNR: July 1984 edition

*AJNR Am J Neuroradiol* 2019, 40 (7) 1250

doi: <https://doi.org/10.3174/ajnr.P0082>

<http://www.ajnr.org/content/40/7/1250>

This information is current as  
of August 20, 2025.

## Celebrating 35 Years of the AJNR

July 1984 edition

Computed Tomography of  
Orbital Myositis

Steven C. Dresner<sup>1</sup>  
William E. Rothfus<sup>2</sup>  
Thomas L. Slamonvits<sup>1,3</sup>  
John S. Kennerdell<sup>1,3</sup>  
Hugh D. Curtin<sup>2</sup>

The computed tomographic (CT) scans of 11 consecutive patients with orbital myositis were reviewed to better characterize the CT appearance of this condition. The findings in this series differed from those of previous reports in several ways. Multiple muscle involvement predominated. Bilateral involvement was more frequent than previously reported. Enlargement of the tendon as well as the muscle was a frequent finding, but a normal tendinous insertion did not preclude the diagnosis of orbital myositis. Although the CT appearance of orbital myositis is often helpful, the findings are not pathognomonic; correlation with history, clinical findings, and therapeutic response must be considered in making the diagnosis.

Orbital myositis is a recognized subgroup of the nonspecific orbital inflammatory syndrome or orbital pseudotumor [1-3]. Early-generation computed tomography (CT) characterized orbital pseudotumor as a diffuse process; however, with improved resolution, specific target organs in the orbit have been identified [3]. For example, when the inflammatory process is localized to the lacrimal gland, sclera, nerve sheath, or extraocular muscle, a diagnosis of dacryoadenitis, periorbititis, perineuritis, or orbital myositis can be made.

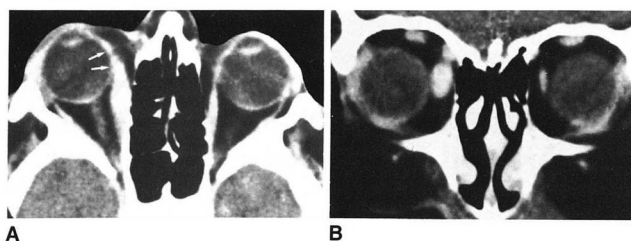
Previous reports characterized orbital myositis as a predominantly unilateral inflammatory process causing irregular enlargement of a single isolated extraocular muscle and its tendinous insertion [3]. It was suggested that this appearance on CT could serve to distinguish orbital myositis from dysthyroid orbitopathy and other orbital conditions causing enlarged extraocular muscles. The present study was undertaken to better characterize the CT appearance of orbital myositis with high-resolution axial and coronal scans.

## Materials and Methods

We reviewed the CT scans of 11 consecutive patients with a diagnosis of orbital myositis based on their history, clinical course, and response to steroids. Patients with diffuse orbital pseudotumor were excluded. Eight of the 11 studies were performed on a GE 8800 scanner. Three studies were performed on an AS & E 5050 scanner. All patients had axial and direct coronal scans with 5-mm sections. Contrast material was used in nine of the 11 studies. No patients had a history of thyroid dysfunction or signs or symptoms of dysthyroid orbitopathy. Laboratory evaluation (done in six patients) was negative for thyroid abnormalities.

## Results

Twenty-nine muscles in 11 patients were identified as enlarged on CT: the medial rectus muscle(s) in eight patients, the lateral rectus in five, the superior rectus/levator palpebrae superioris complex in four, and the inferior rectus and superior oblique in two each. Five of 11 cases had bilateral involvement. Of the six with unilateral involvement, five had a single isolated enlarged extraocular muscle or muscle complex.

Intravenous Contrast-Enhanced CT of the  
Postoperative Lumbar Spine:  
Improved Identification of Recurrent  
Disk Herniation, Scar, Arachnoiditis,  
and Diskitis

J. George Teplick<sup>1</sup>  
Marvin E. Haskin<sup>1</sup>

Unsuccessful relief of symptoms after back surgery is usually attributable to hypertrophic extralaminar scar or recurrent herniated disk. Their clinical and myelographic differentiation is difficult, yet important because reoperation is not always beneficial for scar removal. This article examines the usefulness of intravenous contrast-enhanced computed tomography for this problem. Forty-five postsurgical patients were studied; eight had subsequent surgery. In the four with hypertrophic scars, intravenous contrast enhancement of the scar allowed its recognition in each case; in the four with recurrent disk herniation, nonenhancement of the extruded disk allowed its recognition in three. In the other 37 patients who were not reoperated, 33 were believed to have scar on the basis of contrast enhancement. Continuous contrast infusion during scanning, absolute avoidance of patient movement, and careful consideration of other structures in the spinal canal are important in interpretation. The method seems promising for more accurate evaluation of failed back surgery, including the recognition of diskitis.

High-resolution computed tomography (CT) has proven to be the most accurate method for evaluating the causes of failure of relief or later recurrence of symptoms after back surgery [1-6]. Two of the most common causes are hypertrophic extralaminar scar and recurrent herniated disk [1, 2, 5, 7]. The distinction of one from the other is of considerable importance, since extralaminar scar removal often leads to further scar formation [1, 2, 6, 8], while removal of a recurrent herniated disk is generally beneficial. Until recently the distinction usually could not be made conclusively before reoperation, and too often the surgeon was disappointed in finding a scar and not a recurrent herniated disk.

Both recurrent herniated disk and symptomatic hypertrophic scar can produce similar low-back symptoms and radiculopathy. Gradually increasing symptoms beginning a year or more after diskectomy are considered more likely due to scar radiculopathy, while a more abrupt onset at any interval after surgery is more likely due to recurrent herniated disk [1, 2]. Myelography, unfortunately, cannot make a reliable distinction in most cases [3, 8-10], since both lesions can create a clear-cut myelographic defect at or near the interspace.

In most CT scans of the postoperative lumbar spine, fairly confident recognition of fibrosis (scar) is possible using recently published criteria [4-6]. However, when the postoperative lesion resembles a typical herniated disk on CT, it may still prove to be a hypertrophic scar mass (figs. 1 and 2). Sometimes repeat postoperative CT scans are helpful. If, over a period of months or years, there is a definite increase of extralaminar soft tissues, it is highly probable that a recurrent herniated disk has developed. The postoperative extralaminar tissue, which generally begins as a postoperative hematoma [2, 4-6], tends to diminish slightly as fibrosis develops and matures, but does not usually enlarge. Consequently, an enlarging extralaminar soft-tissue mass on follow-up CT will mean that a recurrent disk herniation has developed (fig. 3).

To make the distinction with greater certainty, some suggest a CT scan with

