



Get Clarity On Generics

Cost-Effective CT & MRI Contrast Agents



FRESENIUS
KABI

WATCH VIDEO

AJNR

CT of long-standing ankylosing spondylitis with cauda equina syndrome.

H Grosman, R Gray and E L St Louis

AJNR Am J Neuroradiol 1983, 4 (5) 1077-1080

<http://www.ajnr.org/content/4/5/1077>

This information is current as
of August 23, 2025.

CT of Long-Standing Ankylosing Spondylitis with Cauda Equina Syndrome

Harvey Grosman¹
Robin Gray
Eugene L. St. Louis

The authors present distinctive computed tomographic (CT) findings in two cases of long-standing ankylosing spondylitis accompanied by the cauda equina syndrome. Multiple, asymmetric erosions of the posterior elements of the lumbar spine on CT were correlated with thecal diverticula demonstrated by myelography. The pathogenesis of these erosions may be related to arachnoiditis in the early phase of the spondylitis.

The occurrence of the cauda equina syndrome in patients with ankylosing spondylitis was first reported by Bowie and Glasgow [1] in 1961. Until then, the known neurologic complications of ankylosing spondylitis included isolated nerve-root lesions, atlantoaxial subluxation with secondary spinal cord compression, and susceptibility to trauma of a rigid spine with injury to the cord. The first cases of cauda equina syndrome in the North American literature were reported in 1973 [2, 3]. In most of the cases reported, dramatic myelographic changes have been noted, namely, multiple thecal diverticula and/or dilated lumbar sacs. Kramer and Krouth [4] in 1961 were the first to describe a case with both characteristic myelographic and computed tomographic (CT) findings. Our two cases show similar CT changes, which in some cases may be so specific as to obviate myelography.

Case Reports

Case 1

A 57-year-old man had noted low back pain initially in 1936 at age 28. By 1946 the pain had subsided but his spine and hips had become immobile. In 1964 he experienced numbness and burning over the lateral and plantar aspects of the right foot, as well as sharp pains in the right buttock and thigh. Other symptoms included impotence, difficulty in micturition, and constipation. A suprapubic prostatectomy failed to relieve the patient's symptoms. Two years later he experienced difficulty in walking because of weakness of the dorsal and plantar flexors of the right ankle.

In 1967, diminution of touch, pain, and temperature sensation was noted in the S1-S5 distribution on the right side. Rectal sphincter tone was lax. Fasciculations were noted in both calves, and there was marked weakness of plantar flexion bilaterally. Ankle jerks were absent. A glucose tolerance test was normal. The cerebrospinal fluid (CSF) protein level was 41 mg/dl, without cells. Spine radiographs showed advanced spondylitic changes with obliteration of the sacroiliac joints and ankylosis of the hips. A myelogram showed a large lumbar sac with many diverticula in the L2-L5 region (figs. 1A and 1B). The nerve root sleeves appeared normal.

Since 1978 the patient has experienced an increasing burning sensation in both feet, recurrent bladder infections, and incontinence. A CT scan of the lumbar spine in 1979 demonstrated asymmetric bony erosions of the laminae and spinous processes at multiple levels and an enlarged spinal canal (figs. 1C and 1D).

Received September 8, 1982; accepted after revision March 21, 1983.

¹ All authors: Department of Radiology, Wellesley Hospital, 160 Wellesley St. East, Toronto, Ont. M4Y 1J3, Canada. Address reprint requests to H. Grosman.

AJNR 4:1077-1080, September/October 1983
0195-6108/83/0405-1077 \$00.00
© American Roentgen Ray Society

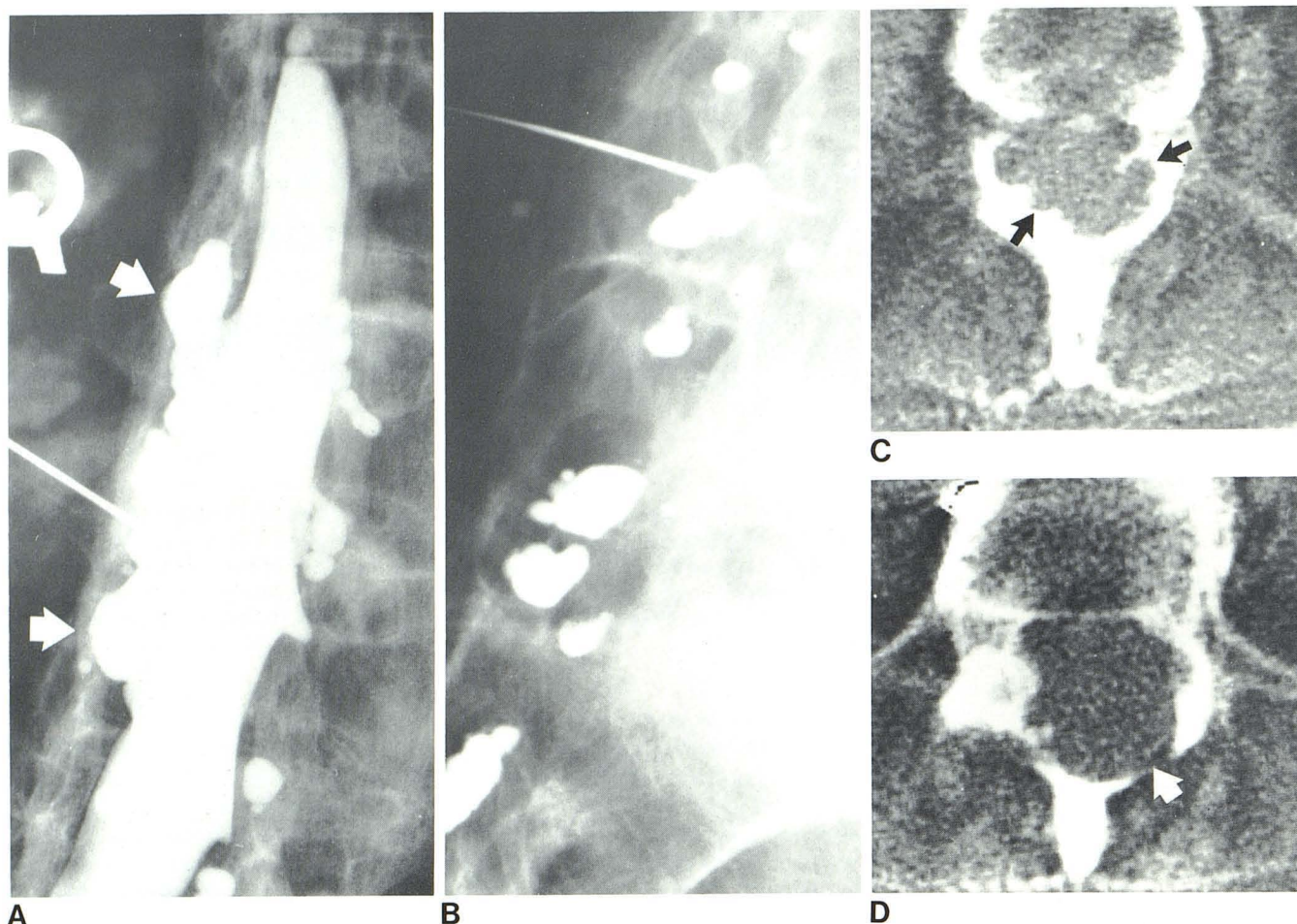


Fig. 1.—Case 1. **A**, Lumbar myelogram, oblique view. Multiple subarachnoid diverticula (arrows) communicate with thecal sac in L2–L5 region. **B**, Standing lateral view of lower lumbar spine. Residual contrast material in multiple, posteriorly situated diverticula. **C** and **D**, CT scans. Asymmetric erosions (arrows) of laminae and spinous processes of vertebrae at multiple levels correspond to diverticula seen on myelography.

Case 2

A 51-year-old man had had persistent cervical and lumbar back pain, progressive stiffening, and decreasing range of back movement since 1952 at age 23. In 1961 (at age 32) a diagnosis of ankylosing spondylitis was made. In 1972 the patient began to experience continuous and progressive paresthesia and coldness in the right leg. Examination in 1975 revealed decreased vibration and pinprick response below the right ankle, slightly decreased position sense in the toes, and unequal ankle jerks.

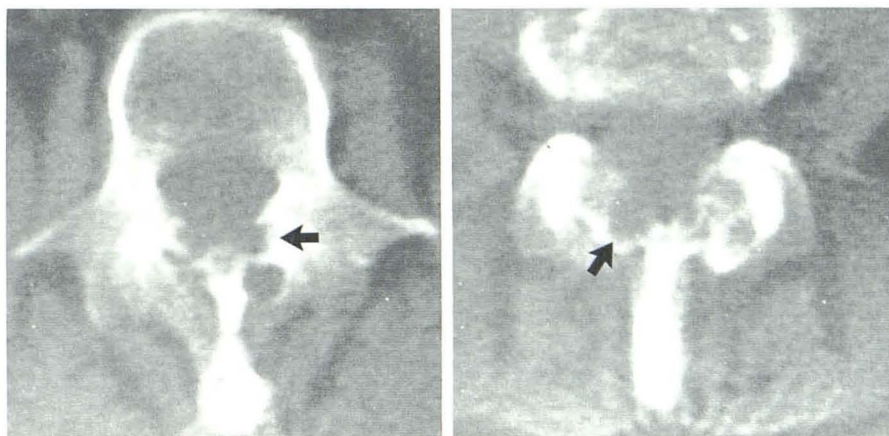
These symptoms gradually progressed; by 1979, the ankle reflexes were absent bilaterally, and there was decreased position sense in the right foot, diminished vibration sense below the knee, and no sensation in the toes. The patient reported persistent numbness of both feet with the right foot colder than the left. Sexual function was normal. Electromyographic studies revealed greatly reduced amplitude of the motor evoked potentials in the left peroneal nerve. Spine radiographs showed advanced spondylitic changes of the entire spine with obliteration of both sacroiliac joints. A CT scan of the lumbar spine demonstrated multiple, asymmetric, irregular erosions of the laminae throughout the lumbar region, more pronounced on the right than on the left (fig. 2).

Discussion

Only 28 cases of the cauda equina syndrome secondary to ankylosing spondylitis have been reported previously [1–11]. Inactivity and long duration of the primary spondylitis appear to be common features in this association. A review of reported cases shows that all the patients had had spondylitis for at least 8 years (and in most cases, much longer) before the onset of neurologic symptoms; this is also well documented in our two patients.

Another important and consistent feature of this disorder, which was emphasized by Russel et al. [2], is the occurrence of dorsally situated lumbar diverticula and/or enlarged thecal sacs. Of the 24 reported cases in which myelography was performed, 15 patients had multiple lumbar diverticula, two had enlarged thecal sacs only, and one had a thoracic diverticulum only. The remaining six patients, reported as normal, may have undergone myelography in the prone position only. The diverticula usually can be demonstrated only in the supine position and may be missed if only a

Fig. 2.—Case 2. Lumbar CT scans. Asymmetric erosions (arrows) of laminae at multiple levels of lumbar spine. Myelography was not performed in this patient.



standard prone myelogram is obtained. This may account for some of the earlier myelographic studies reported as normal.

The CT findings in our cases are striking: multiple, focal, asymmetrically located erosions, selectively involving the laminae and spinous processes of the lumbar spine. In 1968 Mathews [5], who performed the only necropsy on a patient with this disorder, described similar erosions affecting only the posterior elements of the lumbar spine. The pathologic changes seen in the lumbar spine on cross-sectional slices of postmortem specimens from this patient are almost identical to those seen on the CT scans in our patients.

The pathogenesis of this entity remains speculative. Ludwig et al. [12] and Boland et al. [13] have shown that many patients with rheumatoid spondylitis have elevated CSF protein concentrations. Elevated CSF protein levels have been reported also in three of four patients with ankylosing spondylitis and the cauda equina syndrome of less than 2 years' duration. Hauge [6] described a patient with a 1 year history of neurologic disease and elevated CSF protein levels who, at decompressive laminectomy, had extensive fibrous arachnoid reactions in the lumbar region. Mathews [5], in his autopsy report of a patient with a 10 year history of neurologic disease, found normal CSF protein levels, no arachnoiditis, and adhesion of arachnoid, dura, and periosteum to the bony erosions in the lumbar spine.

Mathews theorized that active arachnoiditis with elevated CSF protein levels is present initially but subsides over time to an inactive state. Subsequently, adhesions might form blind-ended arachnoid pouches that could expand through pulsatile force, respiratory pressures, or even gravity. The inflammatory process could impair the elasticity of the meninges and periosteum, and these structures might expand diffusely or focally, causing erosion of the adjacent laminae and spinous processes.

Focal erosions of the spinal canal can occur in many other disease entities, such as perineural cysts, congenital spinal intradural and extradural cysts, and tumors. However, the pathologic changes associated with these entities differ from those described in our patients, since they do not appear at multiple levels, are less asymmetric, and do not

selectively affect the posterior elements of the spine (as was noted in our two cases). Dural ectasia in neurofibromatosis and Marfan disease can occur at multiple levels but always involves the anterior elements of the spine. Most of the other conditions can be differentiated on clinical grounds.

Myelography in patients with rigid "bamboo" spine and calcified paravertebral ligaments can be technically very difficult. The presence or absence of these characteristic focal erosions of the posterior elements can be determined easily by CT. If CT scans are positive and if clinically appropriate, further investigation by myelography may be obviated. Moreover, unnecessary prosthetic or genitourinary surgery (as in our case 1) can be averted if this disorder is diagnosed by thorough screening.

We have performed myelography in two patients who presented with a cauda equina-like syndrome and long-standing ankylosing spondylitis. The CT scans in both cases were considered normal. The myelograms, however, revealed changes consistent with arachnoiditis involving the right S2 nerve root in one patient and the S1–S3 nerve roots bilaterally in the other patient. In patients with normal CT scans, myelography is still warranted.

No effective treatment has been found for this disorder. On the assumption that active arachnoiditis may contribute to the disease process, Russel et al. [2] administered long-term corticosteroids to one of their patients with no effect. Perhaps if steroid therapy were instituted during the earlier, active inflammatory stage of the disease, some ameliorative effect could be achieved. CSF protein levels in these patients could be monitored to determine whether they were in the active inflammatory phase.

In conclusion, we believe that the CT findings described in patients with long-standing ankylosing spondylitis who have developed symptoms consistent with the cauda equina syndrome should be considered characteristic for this entity, as typified by our two cases.

ACKNOWLEDGMENTS

We thank Hugh Smythe, Duncan Gordon, and Lynn Russel for clinical assistance and Roseanna Baldacchin for manuscript preparation.

REFERENCES

1. Bowie EA, Glasgow GL. Cauda equina lesions associated with ankylosing spondylitis. *Br Med J* **1961**;2:24-27
2. Russel ML, Gordan AG, Ogryzlo MA, McPhedran RS. The cauda equina syndrome of ankylosing spondylitis. *Ann Intern Med* **1973**;78:551-554
3. Gordon AL, Yudell A. Cauda equina lesion associated with rheumatoid spondylitis. *Ann Intern Med* **1973**;78:555-557
4. Kramer LD, Krouth GJ. Computerized tomography—an adjunct to early diagnosis in the cauda equina syndrome of ankylosing spondylitis. *Arch Neurol* **1978**;35:116-118
5. Mathews WB. The neurological complications of ankylosing spondylitis. *J Neurol Sci* **1968**;6:561-573
6. Hauge T. Chronic rheumatoid polyarthritis and spondylarthritis associated with neurological symptoms and signs occasionally simulating an intraspinal expansive process. *Acta Chir Scand* **1961**;120:395-401
7. Lee MLH, Waters DJ. Neurological complications of ankylosing spondylitis (letter). *Br Med J* **1962**;1:798
8. McGill IG. An unusual neurosurgical syndrome associated with ankylosing spondylitis. *Guy's Hosp Rep* **1966**;115:33-36
9. Rosenkranz W. Ankylosing spondylitis: cauda equina syndrome with multiple spinal arachnoid cysts. *J Neurosurg* **1971**;34:241-248
10. Hassan I. Cauda equina syndrome in ankylosing spondylosis: a report of six cases. *J Neurol Neurosurg Psychiatry* **1976**;39:1172-1178
11. Milde EJ, Aarli J, Larsen JL. Cauda equina lesions in ankylosing spondylitis. *Scand J Rheumatol* **1977**;6:118-122
12. Ludwig AD, Short CL, Bauer W. Rheumatoid arthritis as a cause of increased cerebro-spinal fluid protein. *N Engl J Med* **1932**;228:306-310
13. Boland EW, Headley WE, Hench DS. The CSF fluid in rheumatoid spondylitis. *Ann Rheum Dis* **1948**;7:195-199