



Get Clarity On Generics

Cost-Effective CT & MRI Contrast Agents



FRESENIUS
KABI

WATCH VIDEO

AJNR

Intracystic radiotherapy (90Y) of craniopharyngiomas: CT-guided stereotaxic implantation of indwelling drainage system.

W J Huk and J Mahlstedt

AJNR Am J Neuroradiol 1983, 4 (3) 803-806

<http://www.ajnr.org/content/4/3/803>

This information is current as
of August 8, 2025.

Intracystic Radiotherapy (^{90}Y) of Craniopharyngiomas: CT-Guided Stereotaxic Implantation of Indwelling Drainage System

W. J. Huk¹ and J. Mahlstedt²

An indwelling drainage system for percutaneous drainage and radiotherapy of cystic craniopharyngiomas is described. The catheter is implanted into the cyst stereotactically with a computed tomography-guided targeting device and connected to a Rickham reservoir. In addition to the repeated percutaneous evacuation of the cysts, this closed system enables intracavitary radiotherapy (yttrium-90) without the risk of leakage of the radioactive material into the cerebrospinal fluid spaces. The technique and relevant literature are discussed, and three typical cases are described.

Craniopharyngiomas constitute one of the most discouraging treatment groups of intracranial tumors for neurosurgeons and radiotherapists. Although usually noninvasive, they adhere to the surrounding vital structures, which makes complete removal impossible without serious damage to the brain [1–3].

For this reason several different kinds of surgical procedures have been described, depending on the location, extent, and structure of the tumor [4]. Leksell et al. [5] divided these tumors into three groups on the basis of their appearance: (1) predominantly cystic, with large solitary cysts (13/21 cases); cystic with appreciable solid parts (four/21 cases); predominantly solid, no cysts observed (four/21 cases).

Recently Cabezudo et al. [6] reviewed the literature and their own results with respect to the efficacy of the various kinds of therapeutic approaches including total or partial removal, radiotherapy, and drainage of the cysts.

Very often the clinical course and symptoms of craniopharyngiomas are determined by the formation of cysts and the reaccumulation of cystic fluid after evacuation of the tumor cyst. In these cases indwelling drainage systems for percutaneous evacuation of the cysts have been advocated [7]. We describe a modification of this technique and report three typical cases.

Technique

Implantation of the drainage system is obtained with a computed tomography (CT)-guided stereotaxic device, which was developed in cooperation with the Siemens Corp. and reported in 1980 [8]. The device allows intraoperative CT sight control of the path of the probe and the accurate localization of the catheter in the tumor cyst. Before operation bilateral angiography of the intracranial

vessels is performed to study the vascular anatomy and its relation to the cyst.

The cyst is punctured through a frontal burr hole and a silicone plastic tube is implanted in such a manner that all holes of the tip of the catheter are placed inside the cyst. Finally the catheter is connected to a subcutaneous Rickham reservoir.

If frequent reaccumulation of cystic fluid in the ensuing weeks or months requires repeated percutaneous evacuation of the cysts, intracystic radiotherapy is considered.

Volumetry of the cyst, which is necessary for the calculation of the proper ^{90}Y dosage, is obtained with a radionuclide dilution technique [9]. For this, ^{99}Tc is injected into the cyst and reaspirated for the measurement about 6 hr later to allow sufficient dilution even in poorly communicating, lobulated cysts. The amount of ^{90}Y is calculated to achieve a total radiation dosage to the cyst wall of about 20,000 rad (200 Gy), a dose which empirically has been found to be adequate [2, 10, 11].

Gamma camera scintigraphy and CT are performed after injection of contrast medium into the cyst to ensure that no leakage of the drainage system exists. Before the isotope is injected, part of the cystic fluid is evacuated to reduce pressure on the nervous structures adjacent to the cyst.

Representative Case Reports

Case 1

A 17-year-old girl was first admitted when a large cystic craniopharyngioma causing occlusive hydrocephalus was discovered. The hydrocephalus was drained by a Torkildsen drainage, and the cyst was punctured through a right frontal burr hole.

At age 23 years, the patient was readmitted with increasing fatigue, ptosis of the left eye, atrophy of both optic nerves, and right temporal as well as left nasal visual field defects. This time an indwelling catheter was implanted freehand into the large cyst and connected to a subcutaneous Rickham reservoir. Postoperatively the clinical symptoms and visual functions improved markedly.

Recurrent symptoms 1½ years later led to another admission for percutaneous evacuation of reaccumulated cystic fluid. Aspiration was repeated 9 months later (fig. 1A) and 2 months after that, when 25 ml of cystic fluid was aspirated. A short time later (fig. 1B), ^{90}Y -silicate was instilled after partial evacuation of the cyst, which again was followed by clinical and visual improvement.

¹Department of Neuroradiology, Neurochirurgische Klinik der Universität Erlangen-Nürnberg, Schwabachanlage 6, 852 Erlangen, West Germany. Address reprint requests to W. J. Huk.

²Institute of Nuclear Medicine, Universität Erlangen-Nürnberg, 852 Erlangen, West Germany.

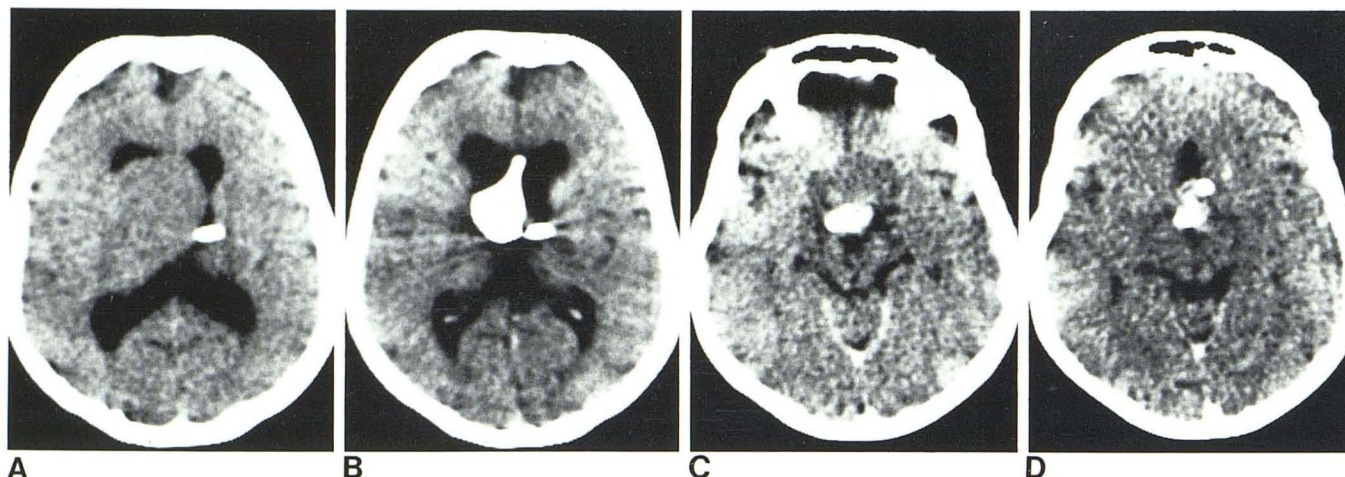


Fig. 1.—Case 1. A, Reaccumulated cyst with indwelling drainage system. B, 11 months later. Metrizamide cystogram before instillation of yttrium-90. C, 3 months later. Second cyst anterior to obliterated first cyst. D, Stereotactically implanted drainage system in frontal cyst after evacuation of cystic fluid.

After another 3 months, the patient was readmitted with progressive loss of vision in both eyes. CT revealed a seemingly refilled cyst. However, when no cystic fluid could be aspirated from the Rickham reservoir and injection of a small amount of metrizamide failed to stain the cyst, a second separate cyst had to be assumed between the horizontal sections of both anterior cerebral arteries (fig. 1C). Soon after, a second drainage system was implanted stereotactically (fig. 1D). As the wall separating the cyst from the ventricle was very thin, drainage of the cyst occurred not only to the Rickham reservoir but also to the ventricle through the holes of the catheter (then still a Holter-Hausner ventricular catheter). The patient was discharged after good clinical improvement. Control CT scans 2 months later showed no refilling of the cysts, and the patient was able to return to work.

Case 2

A 60-year-old man had a right parasellar cystic craniopharyngioma that had caused a left-sided hemiparesis, a third nerve palsy on the right, and visual field defects of both eyes. Because of severe cardiac insufficiency, operation was not indicated at that time.

When the patient was readmitted 4 years later (fig. 2A) with progressive symptoms, a freehand implantation of a Rickham drainage system into the large cyst of 50 ml was performed. Subsequently reaccumulation of cystic fluid required repeated evacuation of the cyst almost every month, and, after 11 months, ^{90}Y -silicate was injected into the approximately 20 ml cyst after partial evacuation.

However, refilling of the cyst occurred after 1 month, and a larger dose of ^{90}Y was instilled into a cyst of about 16 ml. During the next 4 months shrinkage of the cyst was observed on CT scans, and there was slight improvement of visual function. However, about 1 week after the second instillation of ^{90}Y a right oculomotor palsy developed, which has remained unchanged. This functional defect of the third cranial nerve can either be explained by pressure of the cyst, by traction of the shrinking cyst to the adherent nerve, or by radiation damage to the nerve due to its close relation to a thin wall of the cyst at its basal surface. A control CT scan 8 months after the palsy (fig. 2B) showed further shrinking of the cyst. No perifocal edema was seen.

Case 3

A 12-year-old boy was first admitted with clinical signs of endocrine dysfunction, headache for 1 year, and bilateral visual field defects. CT revealed a suprasellar, partly cystic craniopharyngioma. Craniotomy was performed and a subtotal resection of the tumor was achieved.

The patient was readmitted after 1 month with progressive loss of vision, headache, and fatigue. CT demonstrated a supra- and parasellar lobulated cystic lesion (fig. 3A). An indwelling Rickham drainage system was implanted stereotactically into the left parasellar cyst through a left frontal burr hole. When the intra- and suprasellar part of the tumor was punctured, no cystic fluid could be obtained. Postoperatively visual function improved for 3 months, when an incomplete hemianopsia returned that was more pronounced on the left side. ^{90}Y -silicate was injected into the cyst.

After 8 months the patient returned with progressive loss of vision due to a refilling of the left cyst and a second new cyst in the right parasellar region (fig. 3B). Also, white-matter edema was seen in the left frontal lobe. As both cysts could be evacuated through the catheter in the left cyst, indicating sufficient communication between the cysts, a second instillation of a beta-emitter was considered.

Discussion

Since recurrent symptoms in the chronic course of craniopharyngiomas are often due to the development of cysts, particularly in children [12], the drainage of these cysts has proved to be a successful palliative measure [1–4, 6, 7]. For this purpose indwelling reservoir systems, which connected the cavity of the cyst via a thin plastic catheter with a subcutaneously placed Ommaya or Rickham reservoir, were first described by Fox [7] and later Oh [4], Miles [3], and Gutin et al. [13]. These authors inserted the tube into the cyst during open surgery and brought it to the surface under the frontal lobe or by way of the sphenoid wing or through the sylvian fissure. However, in cases of primarily inoperable tumors or when cysts recur after subtotal or even total removal of the tumor, these cysts can be drained through a small burr hole by a stereotactically inserted tube, thus avoiding repeated craniotomy. With our CT-guided targeting device this is a relatively uncomplicated measure, which can also be performed as an emergency

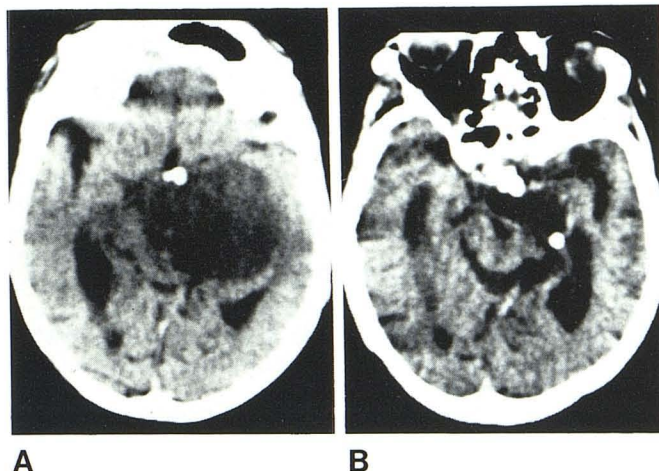


Fig. 2.—Case 2. A, Preoperative size of cystic craniopharyngioma. B, 8 months later. Cyst is markedly diminished.

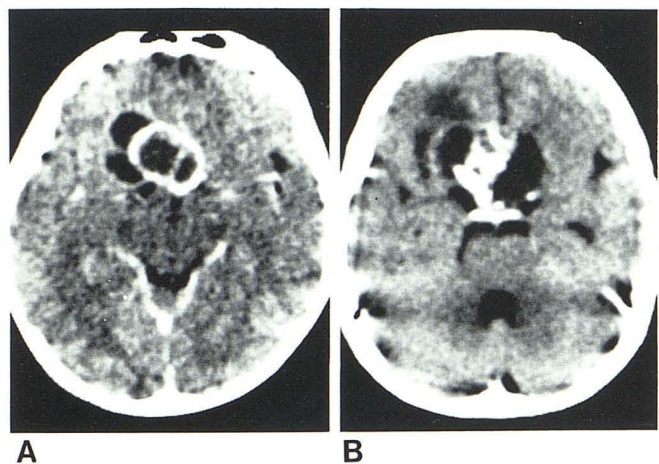


Fig. 3.—Case 3. A, Recurrence of cystic tumor about 1 year after craniotomy with subtotal removal. B, 11 months later. Reaccumulation of left parasellar cyst and formation of second cyst in right parasellar region.

procedure in cases of acute loss of vision. As yet, no occlusion of the shunt has been observed in our six cases of up to 4½ years' duration.

In addition to the repeated percutaneous aspiration of the cyst, the indwelling shunt device was used to instill various therapeutic solutions [4] and radioactive isotopes, such as ^{90}Y for intracystic radiotherapy. Leksell and Liden [10] introduced the stereotaxic puncture and evacuation of the cysts and the instillation of radioactive agents (^{32}P) in the early 1950s. In 1972 Backlund et al. [1] discussed the advantages of various intracystic isotopes and described their technique in the stereotaxic management of cystic craniopharyngiomas.

Among others [5, 14], these authors, and later Sturm et al. [15], injected the radioisotopes into the cyst without using a reservoir system. This technique bears the danger of leakage of the isotope through the puncture hole into the ventricles or the subarachnoid space, with possible loss of cranial nerve function (Mundinger F, personal communication). Backlund et al. [1] detected a small amount of radioactivity in the lumbar cerebrospinal fluid in five of 22 cases without mentioning unwanted side effects on the nervous system; in their opinion major leakage of radioactivity is unlikely.

This is supported by our observation in one case where, after the removal of the cystic contents including the previously injected ^{90}Y , 80% of the radioactivity was found to have remained in the cyst, probably attached to the walls of the cyst [1]. With our closed system, leakage not only seems very unlikely but can also be detected with great reliability before the instillation of the isotope.

Intracystic radiotherapy was indicated when the cystic fluid reaccumulated within a few weeks or months and when no leakage of the drainage system could be verified.

The operative risk of the stereotaxic procedure is similar to that of standard stereotaxic operations [1]. In 1972 Backlund et al. [1] described a subarachnoid hemorrhage in one of their 22 cases. Sturm et al. [15] mentioned a frontal intracerebral hematoma after puncture of the cyst in one of nine cases. In none of our six cases were complications related to the operation observed.

Unwanted side effects of the ^{90}Y radiation to the optic pathways occurred in about 4% of 90 cases in the series of Backlund (cited in [15]). Sturm et al. [15] described transient deterioration of visual acuity in one of 10 cases, which was believed to have been caused by radiation-induced edema or a minute displacement of the impaired optic nerve due to shrinkage of the cyst. The latter may also be the cause of the third nerve palsy in our case 2. If the cyst wall adjacent to important structures is very thin, radiation may have harmful effects outside the cyst, which also would help to explain the third nerve palsy already mentioned, as well as the white-matter edema in our case 3 [16].

Reaccumulation of cystic fluid is not excluded after radiotherapy with beta-emitters. Schaub et al. [16] reported recurrence of cysts in three of 10 cystic gliomas up to 4½ years after the first injection of ^{90}Y (or ^{186}Re) at a dose of about 20,000 rad (200 Gy). In these cases, as in our case 3, the indwelling catheter enables percutaneous evacuation of the cyst and the repetition of the intracystic radiotherapy, avoiding further operative procedures. One explanation for the reaccumulation of cystic fluid may be a too-low dosage due to inaccurate volumetry [2, 14, 17]. With the dilution method, however, volumetry can be difficult in small and lobulated cysts with poor communication among the various parts of the cyst. Dilution of the ^{99}Tc solution may be insufficient, leading to a false smaller volume of the cyst. To reduce this risk we now remove the ^{99}Tc specimen for volumetry no sooner than 6 hr after the injection, which is a modification of the method described by Georgi et al. [9] in 1980, who recommend a repeated reaspiration and reinjection before removing the ^{99}Tc specimen for volumetric calculations in the same session.

The stereotaxic implantation of indwelling drainage systems into inoperable or recurrent cystic craniopharyngiomas offers therapeutic results similar to craniotomy without the need for major surgery. The percutaneous approach to the cysts through the subcutaneous reservoir makes possible not only the immediate decompression of the optic pathways and other nervous structures but also facilitates intracavitary radiotherapy with colloidal ^{90}Y and other liquid agents for the obliteration of the cyst without the risk of leakage.

Although this method does not affect the growth of the solid parts of the tumor, the reduction or the removal of cysts helps alleviate the patients' symptoms for a longer period of their remaining life.

REFERENCES

1. Backlund EO, Johansson L, Sardy B. Studies on craniopharyngiomas. II. Treatment by stereotaxis and radiosurgery. *Acta Chir Scand* 1972;138:749-759
2. Backlund EO. Studies on craniopharyngiomas. Stereotaxic treatment with intracystic yttrium-90. *Acta Chir Scand* 1973;139:237-247
3. Miles J. Sump drainage: a palliative manoeuvre for the treat-

- ment of craniopharyngiomas. *J Neurol Neurosurg Psychiatry* **1977**;40:120-126
4. Oh SY, Rickhamklappen. Drainage bei rezidivierenden zystischen Kraniopharyngiomen. *Schweiz Arch Neurol Neurochir Psychiatr* **1973**;113:57-72
 5. Leksell L, Backlund EO, Johansson L. Treatment of craniopharyngiomas. *Acta Chir Scand* **1967**;133:345-350
 6. Cabezudo JM, Vaquero J, Areito E, Martinez R, Garcia de Sola R, Bravo G. Craniopharyngiomas: a critical approach to treatment. *J Neurosurg* **1981**;55:371-375
 7. Fox JL. Intermittent drainage of intracranial cysts via the subcutaneous Ommaya reservoir. *J Neurosurg* **1967**;27:272-273
 8. Huk W, Baer U. A new targeting device for stereotaxic procedures within the CT-scanner. *Neuroradiology* **1980**;19:13-17
 9. Georgi P, Strauss L, Sturm V, Ostertag H, Sinn H, Rommel T. Prä- und postoperative Volumenbestimmung bei Kraniopharyngiomzysten. *Nuklearmedizin* **1980**;19:187-190
 10. Leksell L, Liden K. A therapeutic trial with radioactive isotopes in cystic brain tumors. Radioisotope techniques, I. *Med Physiol Appl* **1952**;1-4
 11. Szikla G, Peragut JC. Irradiation interstitielle des gliomes. *Neurochirurgia* **1975**;21[Suppl 2]:187-228
 12. Villarejo FJ. Recurrence in craniopharyngiomas. *Neurochirurgia* **1982**;25:73-74
 13. Gutin PH, Klemme WM, Lagger RL, Mackay AR, Pitts LH, Hosobuchi Y. Management of the unresectable cystic craniopharyngiomas by aspiration through an Ommaya reservoir drainage system. *J Neurosurg* **1972**;52:36-40
 14. Bond WH, Richards D, Turner EA. Experiences with radioactive gold in the treatment of craniopharyngiomas. *J Neurol Neurosurg Psychiatry* **1965**;28:30-38
 15. Sturm V, Rommel T, Strauss L, et al. Preliminary results of intracavitary irradiation of cystic craniopharyngiomas by means of stereotactically applied yttrium-90. *Adv Neurosurg* **1981**;401-404
 16. Schaub C, Bluet-Pajot MT, Videau-Lornet C, Askienazy S, Szikla G. Endocavitary beta-irradiation of glioma cysts with colloidal 186-rhenium. In: Szikla G, ed. *Stereotactic cerebral irradiation*, INSERM symposium no. 12. Amsterdam: Elsevier/North Holland, **1979**:293-302
 17. Trippi AC, Garnier JT, Kassabian JT, Sheldon CH. A new approach to inoperable craniopharyngiomas. *Am J Surg* **1969**;118:307-310

Addendum

Since acceptance of this paper, the patient in case 2 has died of cardiac insufficiency. At autopsy, the cranial nerve III palsy was explained by tumor penetration. No radiation damage to the nerve was found.