



Get Clarity On Generics

Cost-Effective CT & MRI Contrast Agents

**FRESENIUS
KABI**

[WATCH VIDEO](#)

AJNR

Transluminal angioplasty of stenotic carotid arteries: case reports and protocol.

U Wiggli and O Gratzl

AJNR Am J Neuroradiol 1983, 4 (3) 793-795

<http://www.ajnr.org/content/4/3/793>

This information is current as
of August 9, 2025.

Transluminal Angioplasty of Stenotic Carotid Arteries: Case Reports and Protocol

U. Wiggli¹ and O. Gratzl²

Transluminal angioplasty of the carotid artery was successfully performed without complications in two patients, one with a stenotic internal carotid artery and one with a stenotic common carotid artery. Effectiveness of the procedure was proven by amelioration of common carotid flow. The authors outline factors to be considered in selecting patients for this procedure, including the particular cerebrovascular pathogenesis, type of stenotic lesion, clinical indications, and technique and materials used for dilatation.

Percutaneous transluminal angioplasty (PTA) or dilatation of neck vessels has been described in cases of surgically inaccessible or poorly accessible lesions such as vertebral artery stenosis [1], carotid artery fibromuscular dysplasia [2], and proximal stenosis of aortic arch vessels [3]. We present two cases of severe carotid artery stenosis treated successfully by PTA. We wish to draw attention to factors that must be considered in selecting patients who are likely to benefit from this procedure; on the basis of such a protocol, carotid angioplasty may become the method of choice in appropriate cases.

Technique

PTA was performed under local anesthesia. Diazepam (5–10 mg) was used for sedation; 1 mg Atropin was given intravenously to protect against reflex bradycardia during manipulation near the carotid sinus. During the procedure the patients were fully heparinized with 20,000 U; after the dilatation, heparin therapy was continued at a lower dose for 2 days and then replaced by oral anticoagulants. A 6 French Olbert balloon dilatation catheter (Surgimed; Oelstykke, Denmark) with a balloon length of 25 mm and balloon diameter (filled) of 5 mm was introduced by transfemoral route. After the balloon segment was placed within the stenosis, circulation ceased in the distal part of the artery. Dilatation was then immediately undertaken and continued until injection of contrast medium showed resumption of circulation in the distal artery (the catheter still remaining within the stenosis). Dilatation lasted 3 min in case 1, 2.5 min in case 2. Total occlusion time was 15–25 sec. In each case dilatation was undertaken three times, each time with increased pressure (2.5–3.8 atm, applied manually). The interval between successive dilatations was 20–30 sec.

Care must be exercised in inflating and deflating the balloon, since the type of catheter used creates not only radial but also tangential forces. The Olbert catheter is otherwise especially well suited to this procedure because the balloon segment is barely

larger than the rest of the catheter. Care must also be taken to achieve a completely symmetric expansion of the balloon. Any marginal indentation may indicate the presence of calcified (i.e., not compressible) material.

Case Reports

Case 1

A 55-year-old man had several transient ischemic attacks with disturbed vision in the left eye. He also complained of dizziness. Seven years previously, a successful endarterectomy had been performed for a right-sided carotid artery stenosis. Neurologic examination on admission was normal. Angiography showed severe stenosis of the left internal carotid artery (fig. 1A). There was concomitant left vertebral artery stenosis.

PTA was performed without complications; its success is documented in figure 1B and table 1. Clinical follow-up over 6 months showed no neurologic abnormalities.

Case 2

A 64-year-old man complained of blurred vision in his left eye. He had repeatedly experienced a slight right-sided hemiparesis and he also complained of dizziness. Diabetes and coronary heart disease (with two infarcts) had been present for at least 15 years. Neurologic examination on admission showed no abnormalities. Angiography detected a severe stenosis of the left common carotid artery (fig. 2A). The contralateral internal carotid artery showed a stenosis of 60%–70%. The right vertebral artery was occluded. PTA was performed without complications; its success is documented in figure 2B and table 1. The patient's clinical follow-up for 8 months showed no neurologic abnormalities.

Discussion

Transluminal angioplasty of stenotic carotid arteries may be an alternative procedure for endarterectomy, if certain factors are considered in selecting patients who are candidates for this procedure. On the basis of experience with angioplasty in peripheral, renal, and coronary artery disease, it is evident that the observed complications (permanent occlusion, intramural hematoma, intimal tearing, embolization of plaques) would have very serious consequences in cerebral arteries. For this reason, our protocol is very restrictive; future successes and further development of dilatation catheters may lead to an accordingly expanded protocol.

¹Department of Neuroradiology, Kantonsspital Basel, CH-4031 Basel, Switzerland. Address reprint requests to U. Wiggli.

²Department of Neurosurgery, Kantonsspital Basel, CH-4031 Basel, Switzerland.

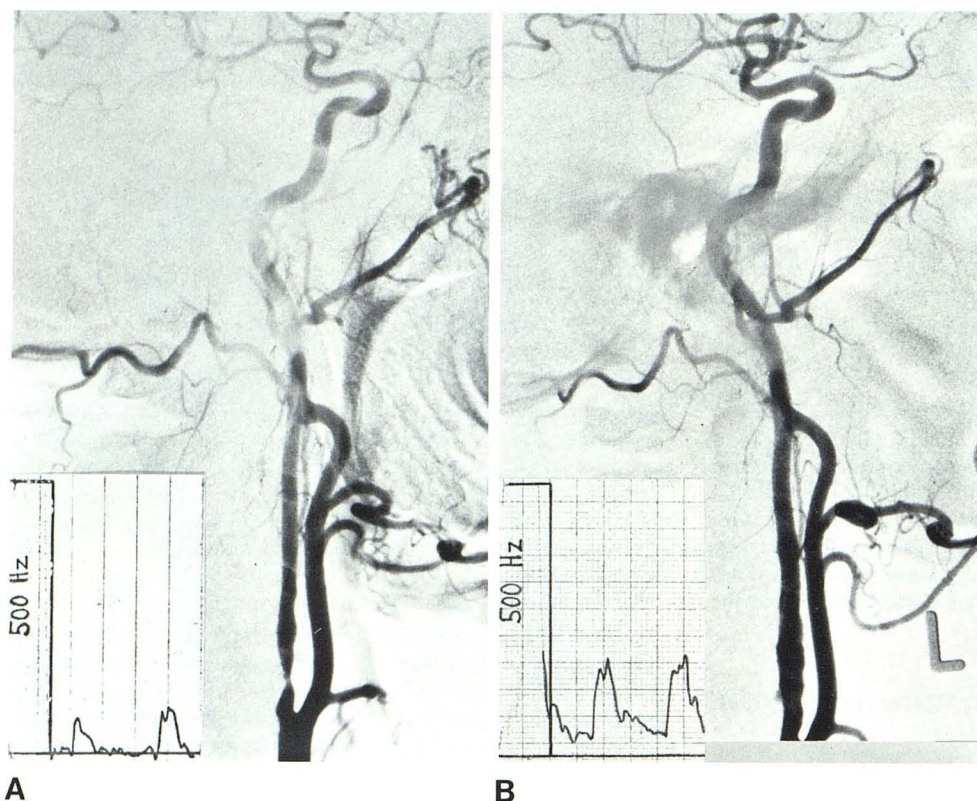


Fig. 1.—Case 1. A, Angiogram before PTA. Severe left-sided stenosis at origin of internal carotid artery. No filling of anterior cerebral artery, slight filling of ophthalmic artery. Very weak supratrochlear signal (*inset*). B, Angiogram 3 weeks after PTA. Internal carotid artery shows only slight irregularities at site of former stenosis. Very good filling of anterior cerebral and ophthalmic arteries. Improved supratrochlear signal (*inset*).

TABLE 1: Common Carotid Flow and Supratrochlear Signal in Two Patients before and after Transluminal Angioplasty

	Common Carotid Flow (ml/sec)		Supratrochlear Signal	
	R	L	R	L
Case 1:				
Before angioplasty	8.4	7.2	++	Ø
After angioplasty	9.9	10.0	++	++
Case 2:				
Before angioplasty	12.9	4.7
After angioplasty	6.4	6.5	+	+

Note.—The supratrochlear signal is an ultrasonographic recording of flow direction (anterograde → or retrograde ←) and flow intensity (+ / ++ / Ø) in the ophthalmic artery. R = right; L = left.

Pathogenesis Suitable for PTA

A meticulous angiographic analysis of pathogenesis and morphopathology of cerebrovascular disease is necessary in each case, including a thorough clinical evaluation and consideration of possible alternative therapeutic and operative procedures. The type of pathogenesis best suited to angioplasty is ocular, cerebral, or cerebellar ischemia due to hemodynamic effects. All extra- and intracranial vessels must be investigated, including existing and potential collateral pathways. The latter can be tested by temporary balloon occlusion.

Stenoses Suitable for PTA

The most suitable stenoses for angioplasty are well delineated, more or less concentric, and no longer than about 10 mm. The degree of stenosis should be hemodynamically significant. The pre- and poststenotic segments should be straight to allow easy manipulation with the catheter. Dilatation of irregular, atheromatous, and ulcerated lesions should probably not be attempted yet; it is questionable whether dilatation has any remodeling effect on plaques [4]. The stenosis should be free of gross intramural calcification; this can be visualized by computed tomography (CT) of the stenotic region (fig. 3). Calcified plaques probably contribute to intimal tearing, although the latter "complication" has been seen on angiograms obtained immediately after endarterectomy.

Clinical Indications for PTA

Suitable candidates for carotid angioplasty include patients with a history of transient ischemic attacks, reversible ischemic neurologic deficits, or mild strokes. However, since angioplasty is not a durable procedure [5], its use should be reserved for the following cases and situations; (1) patients in whom temporary carotid artery occlusion during endarterectomy would not be tolerated owing to lack of collateral vessels; (2) patients who present a high risk for endarterectomy under general anesthesia owing to cardiovascular disease; and (3) patients for whom a short-term effect might be judged sufficient (e.g., very old patients or those who require an emergency procedure pending a later bypass operation, especially in cases where several neck vessels are involved).

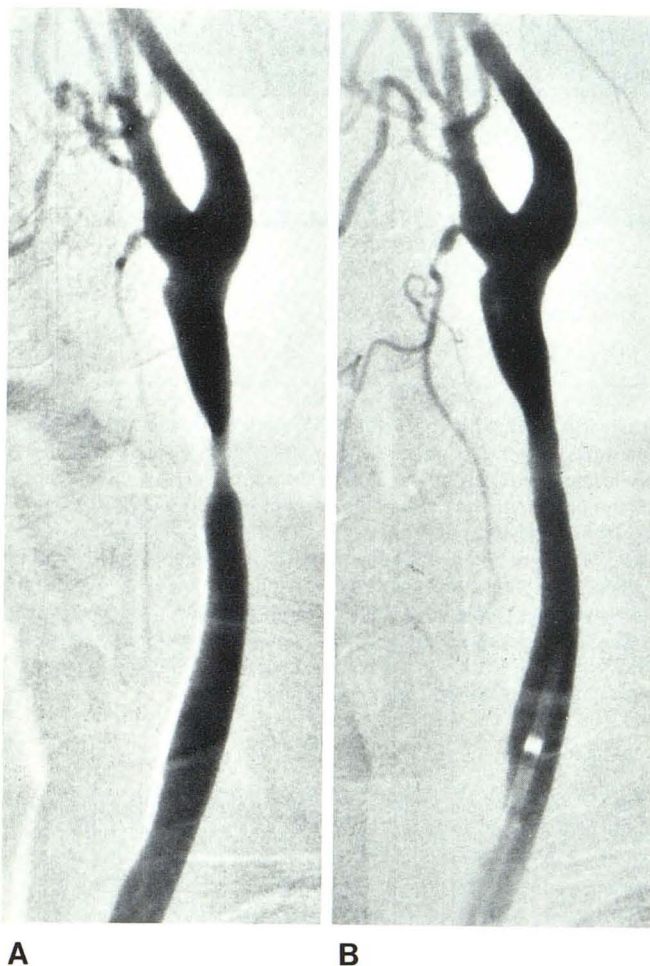
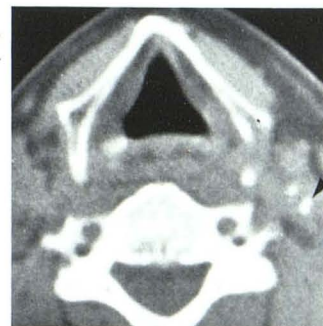

Fig. 2.—Case 2. **A**, Angiogram before PTA. Severe left-sided stenosis of common carotid artery. **B**, Appearance after PTA.

Conclusion

After consideration of the factors mentioned above, catheters and other equipment appropriate to the individual case must of

Fig. 3.—CT scan at level of angiographically located carotid artery stenosis. Localized calcification (arrow).



course be selected. The technical skill of the radiologist in manipulating introducers, wire-guides, and catheters is also of the utmost importance for a successful outcome.

Finally, follow-up evaluation is essential, both immediately after the procedure and at regular intervals over the ensuing 6 months. This evaluation should include clinical assessment and Doppler sonographic data (flow through both common carotid arteries, supratrochlear signal, site and character of carotid murmurs). Follow-up angiography should be performed about 6 weeks after angioplasty.

REFERENCES

1. Motarjeme A, Keifer JW, Zuska AJ. Percutaneous transluminal angioplasty of the vertebral arteries. *Radiology* **1981**; 139:715-717
2. Garrido E, Montoya J. Transluminal dilatation of internal carotid artery in fibromuscular dysplasia: a preliminary report. *Surg Neurol* **1981**;16:469-471
3. Castaneda WR, Formanek A, Lillehei RC, Tatavarthy M, Amplatz K. Nonsurgical treatment of Takayasu's disease. *Cardiovasc Intervent Radiol* **1981**;4:245-248
4. Laerum FL, Vlodaver Z, Castaneda WR, Edwards JE, Amplatz K. The mechanism of angioplasty. *ROFO* **1982**;136:573-576
5. Flanigan PD, Schuler JJ, Spigos DG, Lim LT. Anatomic and hemodynamic evaluation of percutaneous transluminal angioplasty. *Surg Gynecol Obstet* **1982**;154:181-185