



Get Clarity On Generics

Cost-Effective CT & MRI Contrast Agents

 FRESENIUS
KABI

[WATCH VIDEO](#)

AJNR

Combined use of stereotaxic CT and angiography for brain biopsies and stereotaxic irradiation.

H Gahbauer, V Sturm, W Schlegel, O Pastyr, H Scharfenberg, H J Zabel, G van Kaick, G Netzeband, K E Scheer and S Schabbert

AJNR Am J Neuroradiol 1983, 4 (3) 715-718

<http://www.ajnr.org/content/4/3/715>

This information is current as
of August 12, 2025.

Combined Use of Stereotaxic CT and Angiography for Brain Biopsies and Stereotaxic Irradiation

H. Gahbauer,¹ V. Sturm,² W. Schlegel,³ O. Pastyr,³ H. Scharfenberg,³ H. J. Zabel,³ G. van Kaick,³ G. Netzeband,² K. E. Scheer,³ and S. Schabbert²

A Riechert Munding stereotaxic device was modified to enable artifact-free computed tomographic (CT) scanning with the stereotaxic frame attached to the patient's head. A localization system was developed allowing determination of the XYZ coordinates of the target point directly from the CT cut. Angiography was performed intraoperatively with the stereotaxic frame attached. Coronal and sagittal CT reconstructions were enlarged to the radiographic magnification to allow direct comparison with angiography. CT offered optimum localization of the target, whereas angiography determined the safest approach. Computer programs were developed to enable three-dimensional radiotherapy planning. ¹²⁵I seeds were implanted for treatment of low-grade gliomas and solid craniopharyngiomas. Yttrium-90 was applied in cystic craniopharyngiomas. Intracavitary rhenium-186 application was abandoned because of frequent cyst recurrence and leakage from the cyst.

Angiography is of great value for stereotaxic procedures because the safest approach to a lesion can be determined when the vascular anatomy is known. However, it is not very precise in localizing midline tumors or avascular tumors. Computed tomography (CT), on the other hand, is very precise in localizing midline tumors or avascular processes, but it does not always demonstrate the vascular anatomy sufficiently. To overcome the limitations of CT and angiography a system was developed that integrates both methods, wherein the CT tumor outline is transferred onto conventional angiograms.

Methods

Localization System

For stereotaxic surgery a modified Riechert Munding frame is used [1]. Angiography and CT are both performed with the frame attached to the skull [2]. Carbon fiber attachments enable CT scanning close to the base ring without degrading the images by artifacts.

The X and Y coordinates are determined by the sagittal (0°–180°) and coronal (90°–270°) lines, which are marked by thin holes in the base ring. The central x-ray for the radiographs is centered on this point. The CT planes parallel the base ring. To mark the sagittal and coronal line on CT a Plexiglas plate is attached to the base ring at 0°, 90°, 180° and 270°.

The center of these rectangular plates marks the coronal and sagittal lines. The vertical distance from the base ring is measured with a triangle made of thin wires embedded in the Plexiglas plate. The tip of the triangle originates from the zero plane. The angles of the triangle are chosen so that the height of the triangle equals the base (fig. 1). By measuring the distance between the two wires the Z coordinate can be derived directly (fig. 2).

With these localizing systems, the X, Y, and Z coordinates of each point can be measured directly on each CT cut and transferred to the angiogram if the magnification factor is known. The angiogram is obtained in the operating room before stereotaxic surgery with a long focus-film distance to minimize geometric distortion. To ensure that the base ring does not move between the operating room and the CT unit, a mobile table was manufactured that fits on both the operating room table and CT scanner. Displacement of the base ring during transport is thus excluded.

As the X, Y, and Z coordinates are defined on each CT cut, coronal and sagittal reconstructions can be compared directly and superimposed on intraoperative angiograms when radiographic magnification is accounted for [3]. As table increments may vary slightly from a given value, usually 2 mm, a distortion of the sagittal or coronal reconstruction may result. The table increments are therefore measured electronically and only these values are used for computation.

The reconstructions in the axial, coronal, and sagittal planes are enlarged according to radiographic magnification with a CT-controlled ink-jet plotter. From these printouts the tumor outlines are transferred directly to the angiogram by superposition (fig. 3). The approach of the stereotaxic puncture is then chosen according to the orientation of cranial vessels. This is especially important in biopsy of midline tumors such as pinealomas or midbrain tumors to avoid injuries to adjacent great vessels and in suprasellar lesions to avoid injury to suprasellar arteries or the chiasm.

Interstitial Radioisotope Treatment

Precise target-point determination and positioning of radioactive seeds is a prerequisite for interstitial therapy and can be achieved easily by CT-guided stereotaxy. Using three-dimensional radiotherapy planning, the precise position of the implant is calculated. For this purpose, computer programs have been developed allowing precise assessment of the isodose curve of interest according to the position of the seed, number of seeds, and their activity. The

¹Department of Radiology, Surgical Center, University of Heidelberg, Heidelberg, W. Germany. Address reprint requests to H. Gahbauer, Röntgenabteilung, Zentrum für Chirurgie, Universität Heidelberg, Im Neuenheimer Feld 110, 6900 Heidelberg, W. Germany.

²Department of Neurosurgery Surgical Center, University of Heidelberg, Heidelberg, W. Germany.

³Department of Nuclear Medicine, German Cancer Research Center, Heidelberg, W. Germany.




Fig. 1.—A, Four localization Plexiglas plates (solid arrows) mounted on base ring (open arrows) of Riechert Mundinger stereotaxic device at 0°, 90°, 180°, and 270°. B, Close-up view of localization plate. A = zero point for vertical measurement. Line drawn through zero points will also mark coronal or sagittal line. B = CT plane parallel to base ring. C = localization wires embedded in Plexiglas plate and arranged in triangle. Tip of triangle originates from zero point. Angles of triangles are such that base of triangle equals its height.

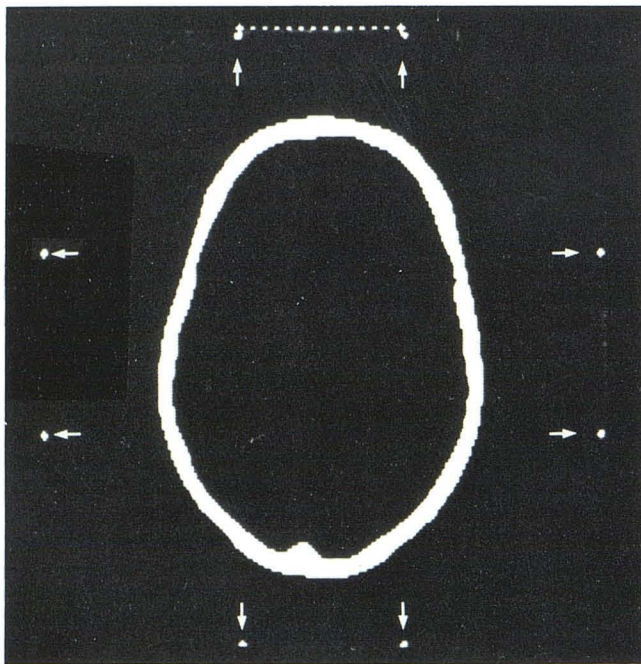


Fig. 2.—Determination of vertical coordinate: distance between localization wires (arrows) is measured on CT display at 0°, 90°, 180°, and 270°. Measured distance equals vertical coordinate (Z).

isodose curve can be displayed three-dimensionally. The computation also considers the form of the seed and the angle of introduction. This is necessary as the seed has an oblong shape [4-7]. ^{125}I is used as the radioisotope [8-10]. The accumulated dose aimed at the tumor margin is 100 Gy [11]. The interstitial implant allows a large dose to be delivered to the tumor [12], relatively sparing surrounding normal tissue, as shown by a steep decline of the isodose curves (fig. 4). Currently, the position of the seed is chosen by trial and error; however, a computer program is being developed that allows automatic calculation of the seed position from the tumor outline.

Intracavitary Treatment

For treatment of cystic craniopharyngiomas the Backlund technique [13-15] is used. Injecting yttrium-90 into the cyst will mainly affect and necrotize the cyst wall and because of its short-range β radiation spare surrounding structures (half layer 1.1 mm in soft tissue). A dose of 200 Gy is aimed at the inner surface of the cyst wall. Usually, the cyst volume does not change dramatically during radiation (half decay time 64 hr), however, it will progressively shrink over the ensuing few weeks and months. Occasionally, the cyst may disappear completely (fig. 5).

Volume determination is essential for intracavitary treatment. The volume is calculated by CT and radiodilution with $^{99\text{m}}\text{Tc}$ after puncture. By comparing CT and radiodilution volume, noncommunicating cysts, possible hyperdense cysts, and leakage can be assessed (fig. 6).

In order to detect possible leakage from the cyst a $^{99\text{m}}\text{Tc}$ scan is obtained intraoperatively before implantation of activity. Postoperative leakage can be checked by an yttrium-90 scan [16]. As an alternative radioisotope rhenium-186 was used in six cases. It has a lower β energy than yttrium-90 and a shorter range in soft tissue.

Results

In a series of 35 patients with predominantly cystic craniopharyngiomas encouraging results were achieved by yttrium-90 implantation. There was no operative mortality. Long-term results will be the subject of a separate report.

Rhenium-186 implantation into cystic craniopharyngiomas was performed in six patients. Its use, however, was abandoned because of frequent cyst recurrence secondary to its short-range radiation and a great tendency to leak from the cyst. The leakage of rhenium-186 may result from the transformation of the sulfur colloid into water-soluble compounds, which possibly leave the cyst more easily.

Only seven interstitial ^{125}I implantations have been performed so far. As the series is small no conclusion can be drawn. However, initial results are encouraging, as shown on the following patients.

An 8-year-old girl with grade I-II thalamic astrocytoma showed a significant reduction of tumor size 1 year after therapy and complete disappearance of sensorimotor hemiparesis (fig. 7).

An 11-year-old girl with grade III hypothalamic glioma showed

Fig. 3.—Comparison of reconstructed CT image with intraoperative stereotaxic angiogram. **A**, Computer printout (ink-jet plotter) of reconstructed coronal CT image in patient with cystic craniopharyngioma. Scale of representation corresponds to distortion of anteroposterior stereotaxic angiogram. Contour of skull (arrows) is calculated from coronal section through largest diameter of skull and drawn into coronal section through tumor to facilitate superposition with angiogram. **B**, Corresponding anteroposterior stereotaxic angiogram with elevation of A1 segment of anterior cerebral artery. Zero sagittal line is determined by hole (arrowhead) in base ring and corresponds to sagittal line in **A** (short arrow).

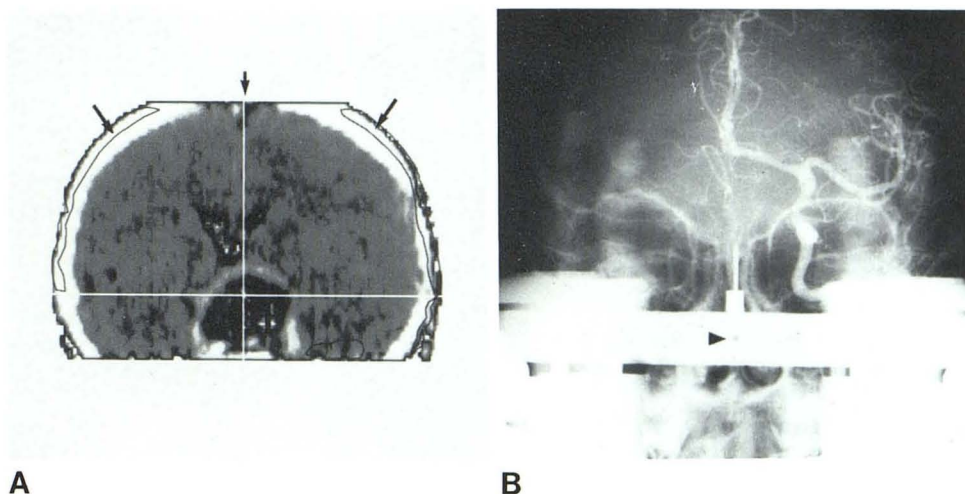


Fig. 4.—Three-dimensional radiotherapy planning in patient with thalamic grade III astrocytoma. Tumor is totally included in 10,000 rad (100 Gy) isodose curve (solid straight arrows). There is a steep dose decline as shown by 6,000 rad (60 Gy) (curved arrows) and 3,000 rad (30 Gy) (arrowheads) isodose curve. **A**, Horizontal CT image. Angle of entry of seed is simulated (open arrow). **B**, Sagittal reconstruction. Positions of three seeds (white squares).

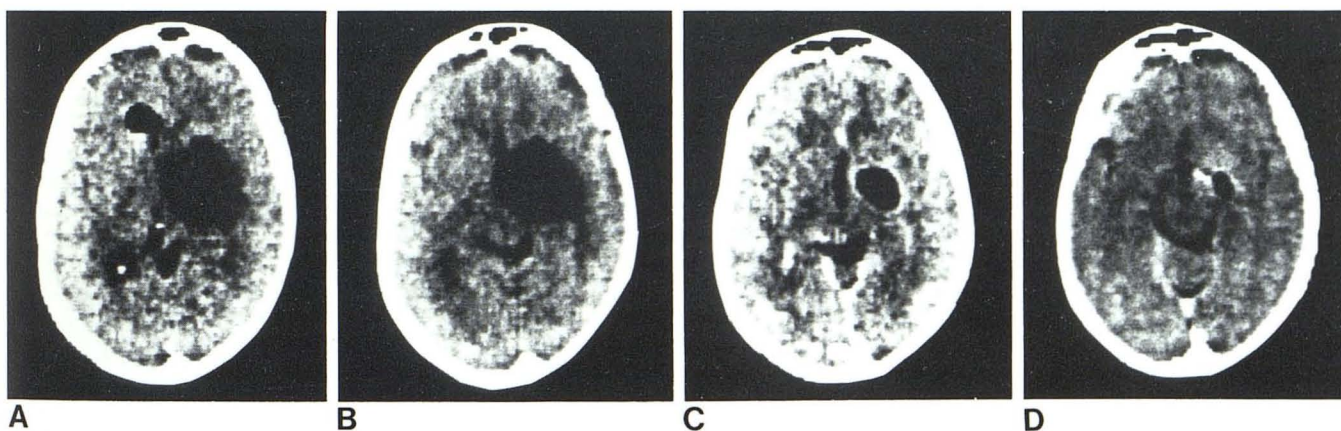
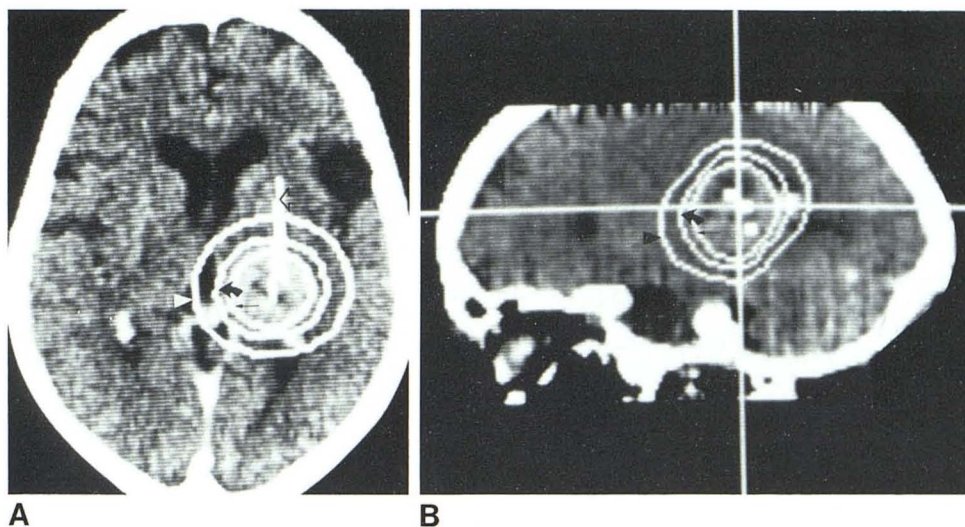


Fig. 5.—Cystic craniopharyngioma after intracavitary treatment with yttrium-90 shows slow progressive cyst shrinkage. Immediately (**A**), 3 weeks (**B**), 6 months (**C**), and 17 months (**D**) after treatment.

considerable shrinkage of tumor 6 months after therapy. The girl was blind preoperatively and regained enough vision to be discharged from a school for the blind.

Discussion

As the range of possible therapies widens and also the potential therapeutic risk, brain biopsies play an increasing role in the clinical

decision process. The system presented offers an easy way of CT-guided target-point determination to meet those demands without exceeding available computer software in current scanners. A simple modification of a conventional stereotaxic frame enables CT scanning without artifacts. CT-guided stereotaxy displaces ventricular filling in functional stereotaxy [17]. The availability of Amipaque CT possibly offers better localization of such structures as uncus

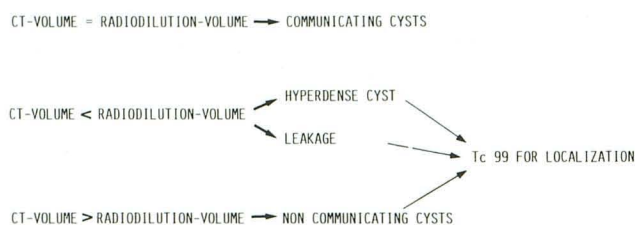


Fig. 6.—Cyst volume checks.

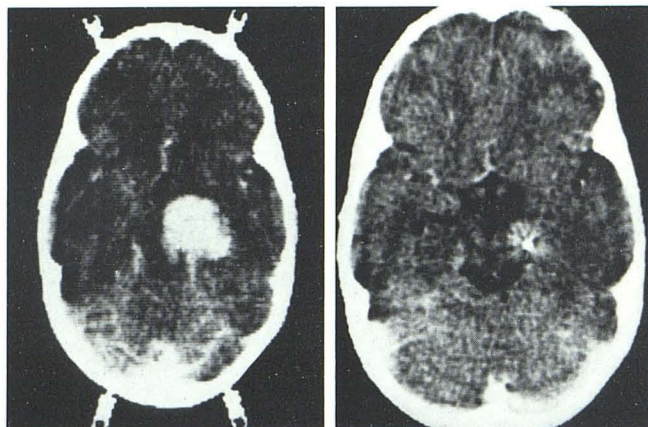


Fig. 7.—Hypothalamic astrocytoma (grade I–II) before (A) and 1 year after (B) treatment with ^{125}I .

and hippocampus than do conventional procedures.

By enlarging sagittal and coronal reconstructions to radiographic magnification, direct comparison of CT and angiography is possible. The addition of angiography to CT-guided stereotaxy enables a safe approach to lesions close to vascular structures, which would otherwise be hazardous to attack. Precise determination of tumor extension by CT, radiotherapy planning with three-dimensional reconstruction, and exact positioning of the seed are essential for successful interstitial therapy, increasing its efficacy and decreasing its risk. Clinical studies in larger series are still necessary to establish its exact role in brain tumor management.

REFERENCES

1. Traugott R. *Stereotactic brain operations*. Bern: Huber, 1980
2. Bergström M, Greitz T. Stereotaxic computed tomography.

AJR 1976;127:167–170

3. Schlegel W, Scharfenberg H, Sturm V, Penzholz H, Lorenz WJ. Direct visualization of intracranial tumours in stereotactic and angiographic films by computer calculation of longitudinal CT-sections: a new method for stereotactic localization of tumour outlines. *Acta Neurochir (Wien)* 1981;58:27–35
4. Hartmann G, Schlegel W, Scharfenberg H. The three-dimensional dose distribution of ^{125}I seeds in tissue. *Phys Med Biol* 1982;28 (in press)
5. Hilaris BS, Kim JH, Tokita N. Low energy radionuclides for permanent interstitial implantation. *AJR* 1976;126:171–178
6. Hilaris BS, Henschke U, Halt JG. Clinical experience with long half-life and low energy encapsulated radioactive sources in cancer radiation therapy. *Radiology* 1968;91:1163–1167
7. Kim JH, Hilaris BS. Iodine-125 source in interstitial tumour therapy—clinical and biological considerations. *AJR* 1975;123:163–169
8. Mundinger F. Rationale and methods of interstitial iridium-192 or iodine-125 protracted long term irradiation. In: Szikla G, ed. *Stereotactic cerebral irradiation*. Amsterdam: North Holland, 1979:101–115
9. Mundinger F, Busan B. Stereotactic interstitial iridium-192. Permanent implantation of pituitary adenomas. In: Szikla G, ed. *Stereotactic cerebral irradiation*. Amsterdam: North Holland, 1979:187–197
10. Pierquin B. The time factor in Curie therapy. In: Szikla G, ed. *Stereotactic cerebral irradiation*. Amsterdam: North Holland, 1979:175
11. Tokita N, Kim JH, Hilaris BS. Time-dose-volume considerations in iodine-125 interstitial brachytherapy. *Int J Radiat Oncol Biol Phys* 1980;12:1747–1749
12. Szikla G, Peragut JC. Irradiation interstitielle des gliomas. *Neurochirurgie* 1975;21[Suppl 2]:187–228
13. Backlund EO, Johansson L, Sarby B. Studies on craniopharyngiomas. II. Treatment by stereotaxis and radiosurgery. *Acta Chir Scand* 1972;133:749–759
14. Backlund EO. Studies on craniopharyngiomas. III. Stereotaxis treatment with intracystic yttrium-90. *Acta Clin Scand* 1973;139:237–247
15. Leksell L, Backlund EO, Johansson L. Treatment of craniopharyngiomas. *Acta Chir Scand* 1967;133:345–350
16. Schaub C, Bluet-Pajot MT, Videau-Lornet C, Askienazy S, Szikla G. Endocavitary beta irradiation of glioma cysts with colloidal rhenium-186. In: Szikla G, ed. *Stereotactic cerebral irradiation*. Amsterdam: North Holland, 1979:293–302
17. Birg W, Mundinger E. Direct target point determination for stereotactic brain operations from CT data and the calculation of setting parameters for polar-coordinate stereotactic devices. *Appl Neurophysiol* 1982;45:387–395