



Get Clarity On Generics

Cost-Effective CT & MRI Contrast Agents

 FRESENIUS
KABI

[WATCH VIDEO](#)

AJNR

Correlative anatomic and CT study of the lumbar lateral recess.

F Matozzi, J J Moreau, M Jiddane, M Beranger, T Ito, S Nazarian, J Gambarelli, P Michotey, C Raybaud and G Salamon

AJNR Am J Neuroradiol 1983, 4 (3) 650-652

<http://www.ajnr.org/content/4/3/650>

This information is current as
of August 12, 2025.

Correlative Anatomic and CT Study of the Lumbar Lateral Recess

F. Matozzi,¹ J. J. Moreau,¹ M. Jiddane,¹ M. Beranger,¹ T. Ito,¹ S. Nazarian,¹ J. Gambarelli,¹ P. Michotey,² C. Raybaud,² and G. Salamon²

The lumbosacral nerve roots and their relation to the lateral recess in the lumbar region were studied by computed tomography both in anatomic specimens from six cadavers and in vivo in 100 patients with or without disk herniation. The anatomic and tomodensitometric correlations are discussed. The normal morphology and contents of the lumbar spinal canal can be used as a guide to radiologic diagnostic exploration, which in turn can indicate the etiology and extent of lumbar sciatica and the course of treatment.

This is a study of the lumbosacral nerve roots and in particular their relation to the lumbar lateral recess. It is hoped that the study will contribute to a better understanding of radiologic exploration in cases of sciatica.

Materials and Methods

The anatomic material came from six cadavers. Frontal, sagittal, and axial slices of the lumbar spine were examined by computed tomography (CT). Other anatomic specimens were examined by contrast-enhanced CT. After CT scanning, each specimen was cut into 5 mm slices in the axial, frontal, or sagittal plane. All of the sections were imaged on metallographic film using a small focal spot tube.

The clinical study subjects were 100 patients with or without a disk herniation, each of whom was examined by axial CT (5-mm-thick slices) on a CE 10000 scanner.

Results

Anatomic Observations

The lateral recess or lateral wall of the vertebral canal is intersected with orifices, namely, the intervertebral foramina, at which level the nerve roots pass. The intervertebral foramina in the lumbar region are exteriorly oriented (fig. 1A) and situated behind the very large, oval-shaped vertebral bodies, forming a canal. The intervertebral foramina at the L5-S1 level are relatively narrow (fig. 1B). Each foramen is limited in front by the intervertebral disk's posterior face and by the outermost part of the upper vertebral body's posterior face; below, by the subjacent vertebral pedicle's superior border; above, by the notched inferior border of the upper vertebra; and behind, by the lower vertebra's superior articular process

anterior face (fig. 1B). The roots in this canal are directed downward and outward in the frontal plane (fig. 1A) and vertically in the sagittal plane (the recess has a keyhole form, wide at the top and narrow at the bottom) (fig. 1B). In the axial plane (fig. 2), the roots run in a transverse direction. In the lateral recess, the roots come into contact with the dura mater, which forms a lumbar sheath that is clearly visible on myelographic or on contrast-enhanced CT (fig. 2D). There are also important venous connections (anastomotic veins between the intra- and extraradicular plexus), arterial connections (radicular artery), and connections with the fat. The sinuvertebral nerve leading to the vertebral ligaments, the disk, and the

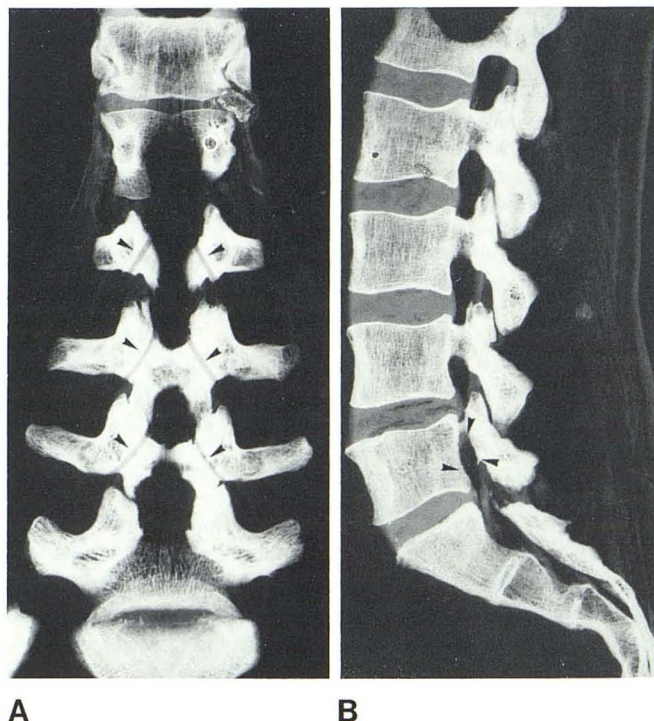


Fig. 1.—Anatomic specimens of lumbar spine. **A**, Frontal section through posterior part of lateral recess and emerging roots (arrowheads). **B**, Sagittal section through lateral recess. At the level of L5-S1, lateral recess is relatively narrow (arrowheads). At any level its shape resembles a keyhole.

¹ Laboratory of Anatomy, Centre Hospitalier Regional et Universitaire de la Timone, 13385 Marseille, France.

² Laboratory of Neuroradiology, INSERM U6, 300 Boulevard Sainte Marguerite, 13 Marseille, France. Address reprint requests to G. Salamon.

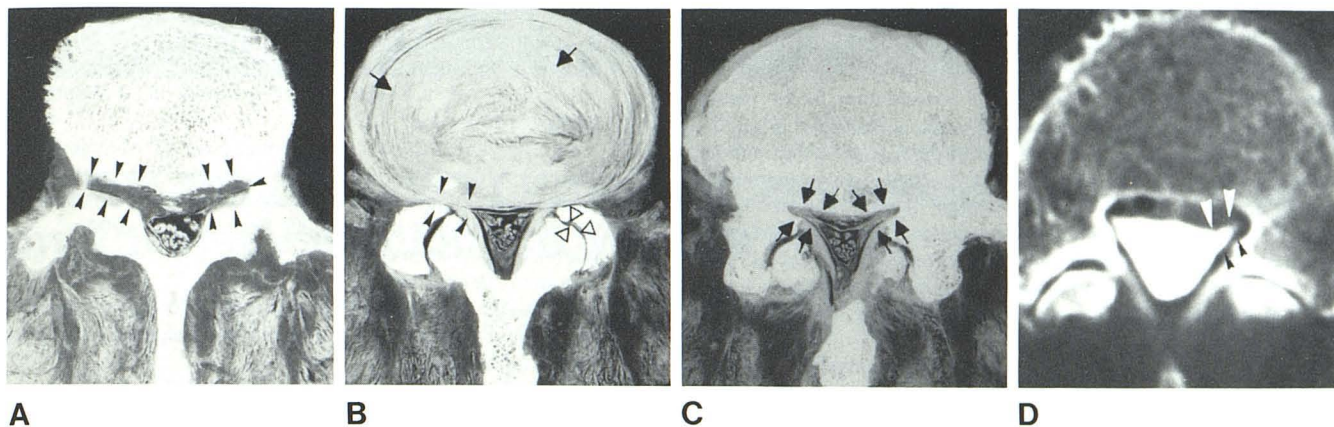


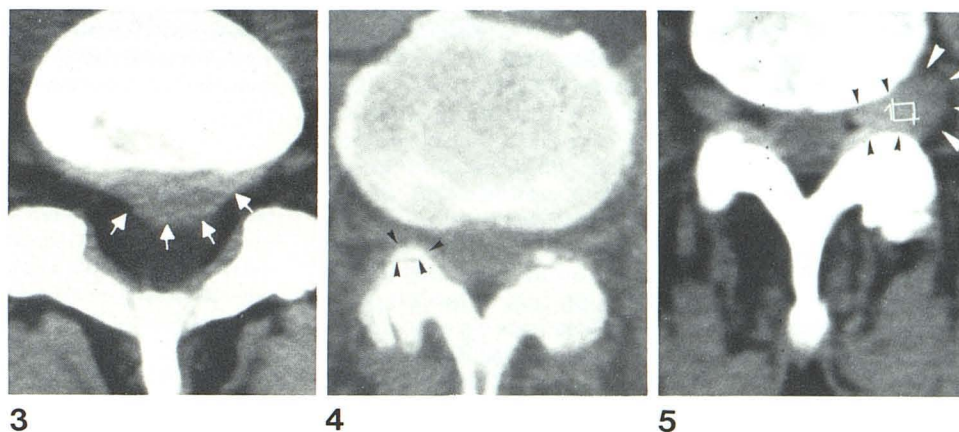
Fig. 2.—Anatomic specimens of L4–L5 space. Axial sections. **A**, Intersecting inferior part of L4. Superior aspect of lateral recess at L4–L5 level (arrowheads). **B**, At level of L4–L5 nucleus (arrows). Ligamentum flavum, facets (arrowheads), and posterior part of disk in close relation with corresponding emerging roots (open arrowheads). **C**, Intersecting superior part of

L5. Inferior aspect of lateral recess (arrows), which is narrower at this level. **D**, Contrast-enhanced CT. Section nearly identical to that of **C**. Subarachnoid space filled with contrast medium shows relation between dural sheath and lateral recess (arrowheads).

Fig. 3.—CT scan. Large disk herniation (arrows) on midline at L5–S1 level. The CT in this case favors complete enucleation of the disk.

Fig. 4.—CT scan. Arthrosis of facets (arrowheads) on right side causes narrowing of right lateral recess. This patient had sciatic pain, but the disk was normal.

Fig. 5.—CT scan. Neuroma (white arrowheads) at level of fourth nerve root on left side, surgically confirmed. Lateral recess (black arrowheads) appears filled by tumor but is not enlarged.



vertebral body is also found in the lateral recess, as are the lymph nodes. The nerve roots are related anteriorly to the intervertebral disk and the common posterior vertebral ligament and posteriorly to the posterior facet joint covered by the ligamentum flavum (fig. 2B). Individual variations in lumbar spinal articulation contribute to the difficulties inherent in CT exploration, in which the slices ideally should be parallel with the disks. Fusion anomalies or other osseous congenital anomalies may modify either the caliber of the canal or the relations between the vertebrae.

Radiologic Observations

The radiologic exploration of the lateral recess calls for at least three CT slices, the first one passing through the central part of the intervertebral disk and the others through the upper vertebra's inferior plateau and the lower vertebra's superior plate, respectively. Slices 5 mm thick are usually sufficient, but it must be realized that those passing through the vertebral body do not explore the lateral recess at all. Static interference may be encountered, especially at the L5–S1 level.

The CT examination usually provides images of the vertebral plate, the pedicle, and the facets (the osseous edges of the lateral recess). The ligamentum flavum overlapping the facet joints is almost always visualized, whereas the image of the common pos-

terior vertebral ligament is difficult to obtain. The emerging nerve root is most often visible at the lateral recess level on unenhanced CT. When radicular compression is present, the protruding disk is almost always visualized (fig. 3). The disk may protrude either medially or laterally. In some cases the disk is extruded and passes to the vertebral body's posterior face, where it is visualized on upper or lower slices. If disk compression is the major clinical problem, CT can show the width or calcifications of the ligamentum flavum, arthrosis of the facet joints (fig. 4), and of course the existence of any other osseous lesions (tumors, fractures, spondylolisthesis) (fig. 5). Narrowing of the spinal canal seen on CT is as significant as that of the lateral recess. Another important observation is the relative width of the dural sheath, which is more easily appreciated on myelography. It is possible that in certain very rare cases in which the dural sheath is very wide, the nerve root's very short free segment makes it extremely vulnerable.

Discussion

Many authors have reported on the tomodensitometric study of the lumbar spine, the spinal canal at the lumbar level, or diskal lesions. We shall consider only those studies that involved anatomic and radiologic correlations.

Most authors [1-7] agree that CT should be performed before any other exploratory examination in patients suffering from low back pain and sciatica. CT is noninvasive and usually can detect a disk herniation by such signs as the convex form of the disk's posterior part, the displacement or obliteration of anterior fat [3, 6-8], the stenosis canals, or the interfacet joint disease that affects the form and size of the lateral recess [1-7, 9]. The radiographic, myelographic, and phlebographic methods of exploration available to us did not permit differentiation between disk herniation and facet syndrome [1-3]. CT allows a different approach to the problem and aids in selecting or rejecting future explorations and surgical treatment. If the diagnosis is confirmed, therapeutic errors can be avoided [3, 10]. From an anatomic viewpoint, CT offers excellent visualization of the vertebral canal borders, the recesses, and the articulations [1-4]. We studied the morphology of the spinal canal, in particular; oval-shaped in L1, it becomes triangular in cross section at L5, where the recesses become deeper and narrower. This explains the frequency of sciatic disease at this level, especially since L5 and S1 are the largest roots [8, 10-12].

REFERENCES

1. Carrera GF. Lumbar facet joint injection in low back pain and sciatica. *Radiology* **1980**;137:661-664
2. Carrera GF, Haughton VM, Syvertsen A, Williams AL. Computed tomography of the lumbar facet joints. *Radiology* **1980**;134:145-148
3. Carrera GF, Williams AL, Haughton VM. Computed tomography in sciatica. *Radiology* **1980**;137:433-437
4. Jacobson RE, Gargano FP, Rosomoff HL. Transverse axial tomography of the spine—Parts I and II. *J Neurosurg* **1975**;42:406-419
5. Anand AK, Lee BCP. CT and metrizamide CT of lumbar disc disease. A comparison with myelography. Presented at the annual international conference on computed tomography of the Head and Spine, La Napoule, France, June **1982**
6. Warmick R, Williams PL, eds. *Gray's anatomy*. New York: Longman, **1973**:1471
7. Williams AL, Haughton VM, Syvertsen A. Computed tomography in the diagnosis of herniated nucleus pulposus. *Radiology* **1980**;135:95-99
8. Naidich TP, King DG, Moran CJ, Sagel SS. Computed tomography of the lumbar thecal sac. *J Comput Assist Tomogr* **1980**;4:37-41
9. Lazorthes G. *Le système nerveux périphérique*. Paris: Masson, **1971**:509
10. Hadley LA. *Anatomico-roentgenographic studies of the spine*. Springfield, IL: Thomas, **1976**:545
11. Kaiser M, Veiga-Pires JA, Dossetor RS. La valeur de la tomodensitométrie dans les affectations de la colonne vertébrale. *Ann Radiol* **1979**;22:1-6
12. Lee BCP, Kazam E, Newman AD. Computed tomography of the spine and spinal cord. *Radiology* **1978**;128:95-102.