



## Get Clarity On Generics

Cost-Effective CT & MRI Contrast Agents



FRESENIUS  
KABI

WATCH VIDEO

# AJNR

## High-resolution CT investigation of nonchromaffin paragangliomas of the temporal bone.

A Valavanis, O Schubiger and M Oguz

*AJNR Am J Neuroradiol* 1983, 4 (3) 516-519

<http://www.ajnr.org/content/4/3/516>

This information is current as of August 9, 2025.

# High-Resolution CT Investigation of Nonchromaffin Paragangliomas of the Temporal Bone

Anton Valavanis,<sup>1</sup> Othmar Schubiger,<sup>2</sup> and Mahmut Oguz<sup>1</sup>

**Twenty-six cases of surgically verified nonchromaffin paragangliomas (NCPs) of the temporal bone were investigated by contrast-enhanced, thin-section, multiplanar high-resolution computed tomography (CT). Based on the high-resolution CT findings the tumors were classified according to a recently introduced surgical classification of NCP into four main types (A, B, C<sub>1</sub>-C<sub>3</sub>, and D<sub>1</sub>-D<sub>3</sub>). With high-resolution CT tumors were correctly classified in all cases, as was shown with intraoperative correlation. On the basis of these findings, high-resolution CT should replace conventional tomography and should be regarded as complementary to selective angiography in the preoperative evaluation of NCP.**

Nonchromaffin paragangliomas (NCPs) (also called glomus tumors or chemodectomas) of the temporal bone are slow-growing, usually benign, locally invasive, and difficult-to-treat tumors that originate either from tympanic or jugular glomus bodies [1-3]. Selection of the surgical approach for NCPs depends on their size and extension [4, 5]. Fisch [6] classified NCPs into four main types, according to their location, size, extension, and degree of involvement of surgically important intratemporal structures. In his consecutive series of 72 surgically treated NCPs this classification proved highly useful, since it guided the selection of the appropriate surgical approach, enabled radical tumor removal, and contributed to a significant reduction of operative morbidity.

## *Classification of NCP of the Temporal Bone [6]*

*Type A* tumors are localized in the tympanic cavity and are removed by conventional tympanoplastic techniques.

*Type B* tumors are localized in the tympanomastoid area and are removed by conventional tympanoplastic techniques.

*Type C* tumors involve the jugular foramen and bulb and show variable degrees of extension into the infralabyrinthine compartment of the temporal bone. Type C tumors are radically removed by the infratemporal fossa approach. Depending on the degree of involvement of the carotid canal, type C tumors are further classified into three subtypes, C<sub>1</sub>-C<sub>3</sub>. For each subtype a specifically modified infratemporal fossa approach is used for radical tumor removal.

*Type D* tumors extend into the intracranial space. Depending on the size of the intracranial part, type D tumors are further classified into three subtypes, D<sub>1</sub>-D<sub>3</sub>. Type D<sub>1</sub> tumors (smaller than 2 cm) are radically removed by the infratemporal fossa approach; type D<sub>2</sub> tumors (greater than 2 cm) are removed by a combined, two-stage

otologic and neurosurgical approach; and type D<sub>3</sub> tumors are regarded as inoperable.

Conventional polytomography for evaluation of intratemporal bone changes and selective angiography for assessment of tumor vascularity and size are complementary methods for the preoperative evaluation of NCP [7-10]. High-resolution computed tomography (CT) of the temporal bone performed with the expanded-number range-target reconstruction technique [11] has proved highly accurate in imaging anatomic detail [12, 13] and in detecting various intratemporal lesions [14, 15]. These facts prompted us to apply high-resolution CT in the preoperative investigation and classification of NCP. In this report the high-resolution CT findings for each type of NCP we observed are presented and discussed.

## Materials and Methods

Between January 1980 and July 1982 we examined 26 surgically verified cases of NCP by high-resolution CT. Thin, overlapping section, contrast-enhanced multiplanar high-resolution CT was performed. All tumors underwent selective angiography, which confirmed in each case the presence of NCP. With the exception of two tumors of type D<sub>3</sub> all other tumors were surgically verified. The extension of each tumor as assessed at operation was correlated with the extension of each tumor as observed on high-resolution CT.

## Results

Based on high-resolution CT findings the 26 tumors were classified according to the system presented above. Correlation with the intraoperative findings in 24 tumors proved the CT classification to be correct in all operated cases.

Two tumors were classified as type A. In both cases a small soft-tissue, intensely enhancing mass was seen in the middle ear cavity, with the medial border of the mass broadly attached to the promontorium of the cochlea. In one case the medial inferior tumor border was also attached to the intact lateral wall of the vertical segment of the carotid canal (fig. 1). There was no destruction of bone evident on high-resolution CT.

Two tumors were classified as type B. In both cases coronal sections showed a mottled-appearing infiltration of the bone plate, which separates the jugular bulb from the hypotympanon. The cortical outline of the jugular bulb was intact. A soft-tissue enhancing mass was evident in the hypotympanon (fig. 2).

Eleven tumors were classified as type C. Among these, two were

<sup>1</sup> Department of Diagnostic Radiology, University Hospital of Zurich, 8091 Zurich, Switzerland. Address reprint requests to A. Valavanis.

<sup>2</sup> Department of Diagnostic Radiology, Kantonsspital Aarau, Switzerland.



classified as type C<sub>1</sub>, five as type C<sub>2</sub>, and four as type C<sub>3</sub>. In both type C<sub>1</sub> tumors coronal sections showed erosion of the cortical outline of the jugular bulb and an enhancing tumor mass in both the hypotympanon and the jugular fossa (fig. 3). In both type C<sub>1</sub> tumors axial sections showed enlargement of the jugular foramen and erosion of its cortical outline (fig. 4). In one case axial sections showed an intact vertical segment of the carotid canal. In the other case there was erosion of the posterior cortical outline of the vertical segment of the carotid canal (fig. 5). Sagittal reconstructions proved equally as useful as axial sections in the evaluation of the vertical segment of the carotid canal and of the jugular spur (fig. 4).

In all type C<sub>2</sub> tumors extensive erosion of the vertical segment of the carotid canal was evident on axial sections (fig. 6). In addition, type C<sub>2</sub> tumors showed variable degrees of extension into the infralabyrinthine compartment of the temporal bone. This was evident on both axial and coronal sections.

The four type C<sub>3</sub> tumors exhibited all the criteria of type C<sub>2</sub> tumors, but showed in addition erosion of the horizontal segment of the carotid canal. This was evident on both axial (fig. 7) and coronal sections. In all type C<sub>3</sub> tumors and in two type C<sub>2</sub> tumors axial sections showed medial extension of the tumor from the jugular foramen into the hypoglossal canal. In these cases coronal sections showed enlargement of the hypoglossal canal and erosion of its cortical outline. In five of these cases sections through the tongue demonstrated ipsilateral hypodensity of the lingual muscles.

Eleven tumors were classified as type D. Five of these tumors were classified as type D<sub>1</sub>, four as type D<sub>2</sub>, and two as type D<sub>3</sub>. The five type D<sub>1</sub> and two of the type D<sub>2</sub> tumors extended from the jugular foramen in a medial and superior direction to occupy the lateral cerebellopeduncular cistern (fig. 8). Of these, three type D<sub>1</sub> tumors and the two type D<sub>2</sub> tumors further extended into the cerebellopontine angle. One type D<sub>2</sub> and a type D<sub>3</sub> tumor first involved the internal auditory canal and then extended directly into the cerebellopontine angle. Another type D<sub>2</sub> tumor and a type D<sub>3</sub> tumor eroded the posterior surface of the petrous bone and extended from there into the posterior fossa.

## Discussion

Exact preoperative classification of NCP into one of the types presented above proved to be the essential prerequisite for selecting and planning the surgical approach [6]. This classification requires detailed evaluation of temporal bone involvement and accurate estimation of tumor size. Although conventional polytomography usually delineates the extent of bony destruction in the temporal bone [7, 8] and selective angiography provides a good estimation of tumor size [9], neither method is sufficient for a detailed evaluation of involvement of important intratemporal structures, such as the carotid canal, the facial nerve canal, and the infralabyrinthine compartment of the temporal bone. Furthermore, with conventional polytomography, because of its limited density resolution, accurate identification of the true extent and the limits of the intratemporal soft-tissue tumor mass is usually not possible. On the other hand, selective angiography was shown to overestimate the actual size of the tumor in certain cases [10].

Because of its improved density and spatial resolution, high-resolution CT visualizes simultaneously both soft tissue and bone structures in the temporal bone with a high degree of accuracy [11, 12]. In all of our cases high-resolution CT demonstrated both the exact size and location of the soft-tissue tumor mass and the type and degree of bone destruction. According to these parameters the tumor was correctly classified in all cases, as was shown by intraoperative correlation.

According to their sites of origin, NCPs of the temporal bone are

generally classified into two main groups, tympanic and jugular [1-3]. While tympanic-type NCPs are confined to the middle ear cavity, jugular-type NCPs may show variable degrees of intratemporal and even intracranial extension. In the surgical classification presented above, type A tumors represent tympanic NCP, while type B, C, and D tumors represent jugular NCP, with variable degrees of intratemporal (types B and C<sub>1</sub>-C<sub>3</sub>) and intracranial (types D<sub>1</sub>-D<sub>3</sub>) extension.

On high-resolution CT, type A NCPs appear as homogenous, intensely enhancing soft-tissue masses in the tympanic cavity, and are usually broadly attached to the promontorium of the cochlea (fig. 1). They do not cause bone erosion, but may be attached to the lateral surface of the vertical segment of the carotid canal.

Type B tumors infiltrate the hypotympanic bone plate and extend into the hypotympanon. For a tumor to be classified as type B, the cortical outline of the jugular bulb must be intact. Evidence of erosion of the cortical outline of the jugular bulb indicates tumor extension into the jugular bulb. In order for the removal to be radical in these cases the infratemporal fossa approach is necessary. Therefore NCPs exhibiting type B criteria but in addition showing erosion of the cortical outline of the jugular bulb must be classified as type C<sub>1</sub> tumors [6]. The cortical outline of the jugular bulb is best evaluated on coronal sections performed at the level of the pars vasculosa of the jugular foramen (figs. 2 and 3).

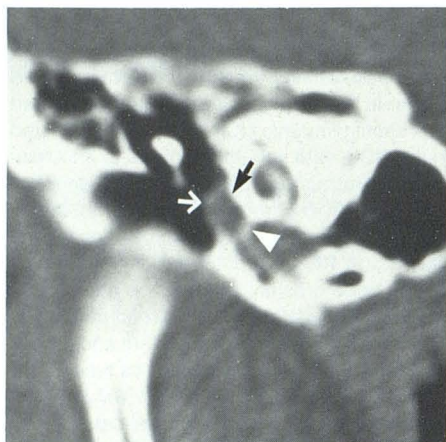Type C tumors are characterized by enlargement and erosion of the jugular foramen, variable degrees of involvement of the carotid canal, and variable degrees of extension into the infralabyrinthine and apical compartments of the temporal bone [6]. Since the shape of the jugular foramina of both sides is frequently asymmetric, and their sizes frequently differ, evidence of erosion of their cortical outline is a more sensitive factor than enlargement in evaluating NCPs. In all type C and type D tumors (22 cases) in our series erosion of the cortical outline of the jugular foramen was found in 15 cases (68%). Axial sections proved superior to coronal for evaluation of the jugular foramen.

Because of the central role of the carotid artery in surgery of NCP, type C tumors were further classified into three types, according to the degree of involvement of the carotid canal. In type C<sub>1</sub> tumors the carotid canal may be intact (fig. 4), or there may be minimal erosion of the posterior aspect of the cortical outline of the vertical segment of the carotid canal (fig. 5). The cortical outline of both the vertical and horizontal segments of the carotid canal is best evaluated on axial sections (figs. 5 and 6). In addition, sagittal reconstructions proved equally useful for evaluation of the posterior wall of the vertical segment of the carotid canal (fig. 4). In type C<sub>2</sub> tumors the vertical segment of the carotid canal is usually circumferentially eroded (fig. 5). Type C<sub>3</sub> tumors are characterized by additional erosion of the horizontal segment of the carotid canal (fig. 6). Erosion of the horizontal segment first occurs at the proximal part of the horizontal segment and usually involves the lateral wall (fig. 6).

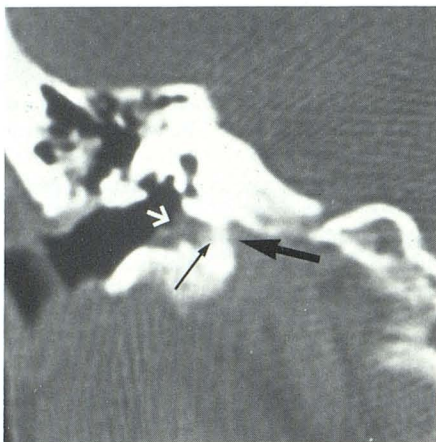
Invasion into the infralabyrinthine compartment, which occurs with type C tumors, is seen on high-resolution CT as an area of mottled appearance of the involved bone. While axial sections show the true extent of invasion of the infralabyrinthine compartment, coronal sections are useful in demonstrating even minimal erosion of bone. Type C<sub>1</sub> tumors show only minimal involvement of the infralabyrinthine compartment, limited to destruction of the jugular spur. Type C<sub>2</sub> tumors usually involve completely the infralabyrinthine compartment around the vertical segment of the carotid canal and frequently extend also medially in order to involve the inframeatal compartment (i.e., the bone plate below the floor of the internal auditory canal).

Type C<sub>3</sub> tumors also invade the apical compartment (the bone space ventral to the infralabyrinthine compartment and around the horizontal segment of the carotid canal). Type C<sub>2</sub> and C<sub>3</sub> tumors





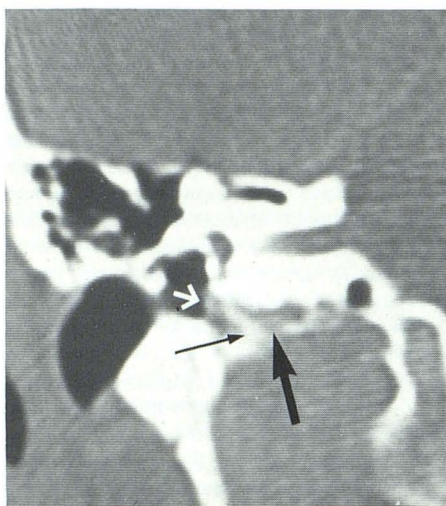
1



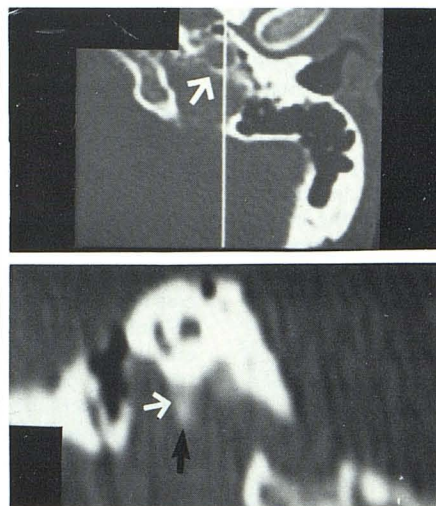
2

Fig. 1.—Type A NCP, right side. Coronal section. Small, enhancing, soft-tissue tumor mass (white arrow) broadly attached to promontory (black arrow) and lateral wall of carotid canal (arrowhead). No bone erosion.

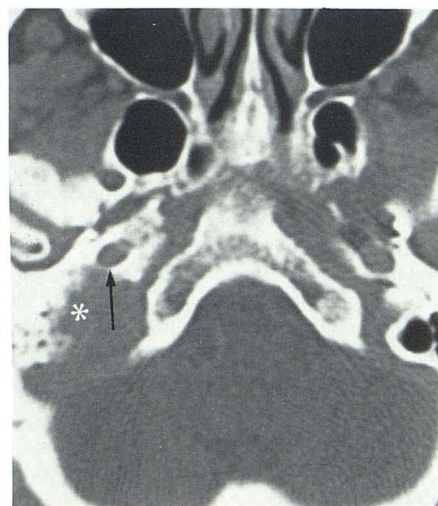
Fig. 2.—Type B NCP, right side. Coronal section. Erosion of hypotympanic bone plate (thin black arrow). Soft-tissue tumor mass in hypotympanon (white arrow). Notice intact cortical outline of jugular bulb (thick black arrow).



3



4



5

Fig. 3.—Type C<sub>1</sub> NCP, right side. Coronal section. Erosion of hypotympanic bone plate (thin black arrow). Soft-tissue tumor mass in hypotympanon (white arrow). Erosion of cortical outline of jugular bulb (thick black arrow).

Fig. 4.—Type C<sub>2</sub> NCP, right side. Sagittal reconstruction. Cortical outline of posterior carotid canal wall is intact (white arrow), as is jugular spur (black

arrow).

Fig. 5.—Type C<sub>1</sub> NCP, left side. Axial section. Significant enlargement and erosion of left jugular foramen (asterisk). Minimal erosion of cortical outline of posterior wall of vertical segment of carotid canal (arrow).

frequently extend medially and erode the hypoglossal canal. This was the case in six of the nine C<sub>2</sub> and C<sub>3</sub> tumors of this series. Axial sections demonstrate better than coronal sections tumor extension into the hypoglossal canal. Coronal sections show in these cases enlargement and erosion of the cortical outline of the hypoglossal canal more accurately than axial sections. In cases with involvement of the hypoglossal canal, coronal or axial sections through the tongue frequently (in five of six cases in this series) show ipsilateral hypodensity. This finding was previously described and attributed to denervation hemiatrophy of the tongue [16].

Type D tumors are characterized by intracranial extension into the posterior fossa. The size of the intracranial component in type D<sub>1</sub> tumors is less than 2 cm, and more than 2 cm in type D<sub>2</sub> tumors. Type D<sub>3</sub> tumors are considered inoperable because of their large extension. The tumor first extends into the extradural compartment of the posterior fossa. Since the medial border of the intracranial

component of the tumor is covered by dura it is typically convex shaped, smoothly contoured, and sharply demarcated (fig. 8). Usually type D<sub>1</sub> tumors are completely extradural. Type D<sub>2</sub> and D<sub>3</sub> tumors may however invade the dura and come in close contact or even adhere to the cerebellum. In three cases of this series parts of the intracranial component of the tumor were found at surgery to be located intradurally. In each of these cases CT demonstrated that one or more nodules overlaid the medial border of the tumor. We therefore suggest that a nodular appearance of the medial border of the intracranial portion of a NCP may indicate intradural extension.

Three patterns of intracranial extension were found in this series. Most commonly the tumor extends superomedially from the jugular foramen and occupies the lateral cerebellomedullary cistern. With further cranial-directed growth the tumor may occupy the cerebellopontine angle. More rarely, the tumor first involves the infralaby-



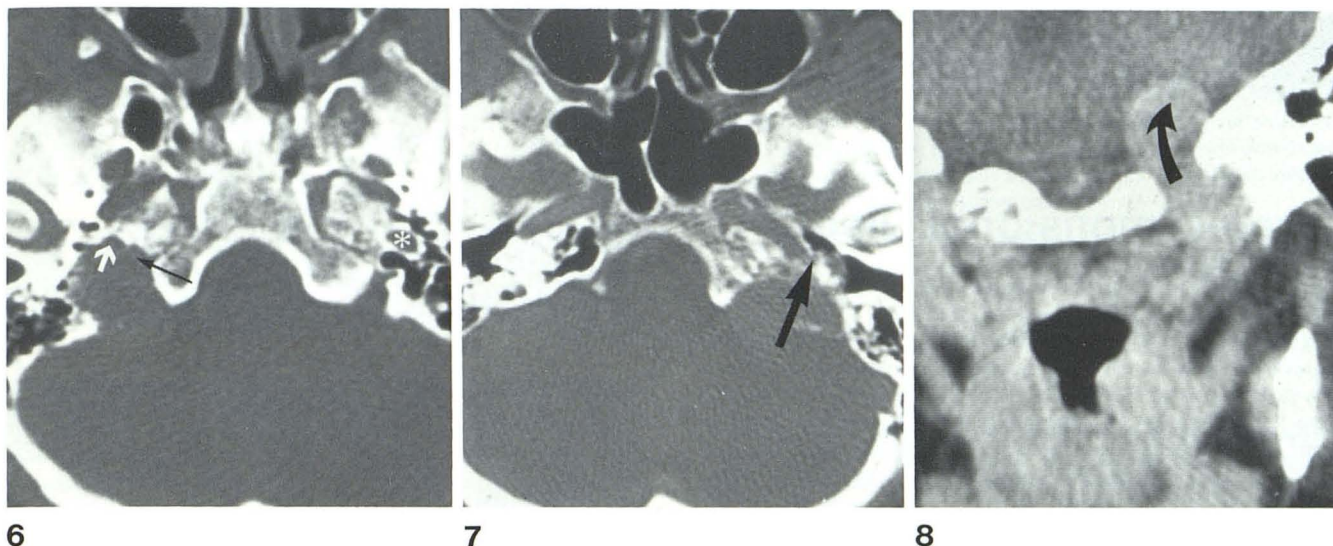


Fig. 6.—Type C<sub>2</sub> NCP, left side. Axial section. Vertical segment of carotid canal is completely destroyed (white arrow). Compare with normal carotid canal of right side (asterisk). There is in addition involvement of infralabyrinthine compartment around vertical segment of carotid canal (black arrow).

Fig. 7.—Type C<sub>3</sub> NCP, right side. Axial section. Erosion of lateral wall of

horizontal segment of carotid canal (arrow). Notice also extensive involvement of infralabyrinthine and apical compartments.

Fig. 8.—Type D<sub>2</sub> NCP, left side. Coronal section. Tumor extends from jugular foramen in medial and superior direction intracranially (arrow).

rinthine, then the inframeatal compartment, grows through the floor of the internal auditory canal intrameatally, and extends from there extrameatally to occupy the cerebellopontine angle. Also rarely, the tumor first involves the infralabyrinthine and inframeatal compartments and causes erosion of the posterior surface of the petrous bone. From here it extends broadly into the posterior fossa.

In conclusion, it is evident that high-resolution CT is the radiologic method of choice in providing the operative classification of NCP. This assertion is based primarily on the ability of high-resolution CT to accurately visualize the surgically important structures of the temporal bone (i.e., the middle ear cavity, the hypotympanic bone plate, the cortical outline of the jugular bulb, the jugular foramen, the carotid canal, the infralabyrinthine compartment, and the hypoglossal canal). Also important is its sensitivity in detecting even minimal erosion or involvement of these structures.

Selective angiography is complementary to high-resolution CT in the preoperative evaluation of NCP. Identification of the feeding arteries and correct localization of the tumor blush in the middle ear cavity and/or jugular fossa with the help of the recently introduced transcanalicular view allow correct estimation of size and extension of NCP in most cases [9]. Selective angiography is superior to high-resolution CT in detecting involvement of the wall of the carotid artery and tumor extension into the internal jugular vein [10].

## REFERENCES

1. Guild SR. Glomus jugulare in man. *Ann Otol Rhinol Laryngol* 1953;62:1045-1071
2. Alford BR, Guilford FR. Comprehensive study of tumors of the glomus jugulare. *Laryngoscope* 1962;72:765-787
3. Glasscock ME, Harris PF, Newsome G. Glomus tumors: diagnosis and treatment. *Laryngoscope* 1974;84:2006-2032
4. Oldring D, Fisch U. Glomus tumors of the temporal region: surgical therapy. *Am J Otol* 1979;1:7-18
5. Jenkins HA, Fisch U. Glomus tumors of the temporal region. *Arch Otolaryngol* 1981;107:209-213
6. Fisch U. Infratemporal fossa approach for glomus tumors of the temporal bone. *Ann Otol Rhinol Laryngol* 1982;91:474-479
7. Spector GJ, Sobol S, Thwaley SE, Maisel RH, Ogura JH. Glomus jugulare tumors of the temporal bone. Patterns of invasion in the temporal bone. *Laryngoscope* 1979;89:1628-1639
8. Valvassori GE, Buckingham RA. Radiography. In: Valvassori GE, Potter GD, Hanafee WN, Carter BL, Buckingham RA, eds. *Radiology of the ear, nose and throat*. Stuttgart: Thieme, 1982:85-89
9. Hesselink JR, Davis KR, Taveras JM. Selective arteriography of glomus tympanicum and jugulare tumors: techniques, normal and pathological arterial anatomy. *AJNR* 1981;2:289-297
10. Lasjaunias P, Menu Y, Bonuel D, Doyon D. Nonchromaffin paragangliomas of the head and neck. Diagnostic and therapeutic angiography in 19 cases explored from 1977 to 1980. *J Neuroradiol* 1981;8:281-299
11. Schaffer KA, Volz DJ, Haughton VM. Manipulation of CT data for temporal-bone imaging. *Radiology* 1980;137:825-829
12. Littleton JT, Schaffer KA, Callahan WP, Duricz ML. Temporal bone: comparison of pluridirectional tomography and high resolution computed tomography. *AJR* 1981;137:835-845
13. Russel EJ, Koslow M, Lasjaunias P, Bergeron RT, Chase N. Transverse axial plane anatomy of the temporal bone employing high spatial resolution computed tomography. *Neuroradiology* 1982;22:185-192
14. Lloyd GAS, Phelps PD, Du Boulay GH. High-resolution computerized tomography of the petrous bone. *Br J Radiol* 1980;53:631-641
15. Hanafee WN, Mancuso A, Winter J, Jenkins H, Bergstrom L. Edge enhancement computed tomography scanning in inflammatory lesions of the middle ear. *Radiology* 1980;136:771-775
16. Naidich TP, Pudlowski RM, Leeds NE, Deck MDF. Hypoglossal palsy: computed tomography demonstration of denervation hemiatrophy of the tongue associated with glomus jugulare tumor. *J Comput Assist Tomogr* 1978;2:630-632