



## Get Clarity On Generics

Cost-Effective CT & MRI Contrast Agents



FRESENIUS  
KABI

WATCH VIDEO

# AJNR

## Computed tomography of the anteverted internal auditory canal.

A J Silver, A F Jahn, P Sane, M E Mawad, S R Ganti and S K Hilal

*AJNR Am J Neuroradiol* 1983, 4 (3) 513-515

<http://www.ajnr.org/content/4/3/513>

This information is current as  
of August 18, 2025.

# Computed Tomography of the Anteverted Internal Auditory Canal

A. John Silver,<sup>1</sup> Anthony F. Jahn,<sup>2</sup> Paul Sane,<sup>1</sup> Michel E. Mawad,<sup>1</sup> S. Ramaiah Ganti,<sup>1</sup> and Sadek K. Hilal<sup>1</sup>

A symmetric variation in the course of the internal auditory canals, visualized best on axial computed tomographic views with thin sections, was observed in three of 75 patients examined mainly for hearing, vestibular, and facial nerve dysfunction. The incidence may be lower in an unselected population. In coronal section, with either pluridirectional or computed tomography, an anteverted internal auditory canal may mimic the normal configuration of "medial narrowing" because of the effect of partial sectioning of an angled cylinder with a thin beam. The pathologic significance of this finding is uncertain. In the three cases reported, it was associated with adult-onset uni- or bilateral hearing loss. Vestibular function may be compromised but may not be symptomatic. Facial nerve function was not impaired.

A large number of variations and anomalies in the anatomy of the internal auditory canal have been described in the plain film and pluridirectional tomographic literature [1-3], but very few have been added with computed tomography (CT) [4]. We have observed an anatomic feature not previously reported, to our knowledge, which is unlikely to have been detected prior to the use of CT. Because of the possibility of confusing it with a common, normal configuration on coronal views, with either pluridirectional tomography or CT, and also because of the coincident occurrence in each case of eighth nerve dysfunction, we are reporting three cases of anteverted internal auditory canals.

## Materials and Methods

CT scans obtained during a 1½ year period from the Neurological Institute with high-resolution, thinly sectioned (4 mm or less) views of the internal auditory canals were reviewed. The patients carried a variety of brainstem-related diagnoses; an undetermined number had hearing loss. In 75 consecutive cases, the internal auditory canals were measured on axial CT for the angular deviation of their long axes from a transverse line drawn between the orifices of the canals.

## Results

Three of 75 cases with axial CT views of the length of the internal auditory canals showed significant canal anteversion of 30° or more. In each case, the finding was symmetric with a slight, ante-

riorly convex curve to the canals. One case was associated with significant pneumatization of the petrous apices and narrowing of the internal auditory canals. The others were neither unusually pneumatized nor narrow. Coronal views were obtained in two cases and showed apparent "medial narrowing" [1], which was an artifact due to partial sectioning of the internal auditory canal at different levels with a narrow beam. There was no significant abnormality of head shape, although each patient was minimally brachycephalic. No other cranial abnormality was noted on CT, and no other cranial or systemic abnormality was found on clinical examination of these three patients.

Functionally, one patient had significant chronic, bilateral, central hearing loss (fig. 1) with nonlocalizing vestibular dysfunction, while a second had sudden, unilateral hearing loss of uncertain localization, with bilaterally diminished vestibular function. Both of these patients were in their 50s. A third patient, aged 32, had marked unilateral, high-frequency, central hearing loss with normal vestibular function in association with extensive petrous pneumatization and narrow internal auditory canals (fig. 2). Facial nerve function was normal in all three patients.

## Discussion

### Anatomy

The internal auditory canals project directly laterally, perpendicular to the midsagittal plane, in most patients [1]. Mild and asymmetric anteversion (10° or less) can be seen in a few cases (fig. 3), but our three cases showed marked (30°) and symmetric anteversion, with a definite, anteriorly convex curve.

The incidence of 4% in our series of patients (with various central and peripheral brainstem, hearing, vestibular, and facial disorders) suggests that canal anteversion is not a rare variant, but it may be less common in an unselected population. The absence of previous descriptions is attributable to the infrequency of obtaining thinly sectioned axial views by pluridirectional tomography, which are now obtained routinely with high-resolution CT scanners.

Thinly sectioned coronal CT views of anteverted canals may show only a part of each canal on any single view. For example, a view that shows the entire diameter of the lateral part of the canal may show only a partial diameter of the medial part. This appearance, of apparent relative narrowing of the medial aspect of the canals, mimics the common normal pattern of "medial narrowing." While the latter configuration usually reflects a true narrowing of the medial aspect (porus) of the internal auditory canal (fig. 4), a few such cases could actually represent anteverted canals.

<sup>1</sup> Department of Radiology, Neurological Institute, Columbia-Presbyterian Medical Center, 710 W. 168th St., New York, NY 10032.

<sup>2</sup> Department of Otorhinolaryngology, Presbyterian Hospital, Columbia-Presbyterian Medical Center, New York, NY 10032.



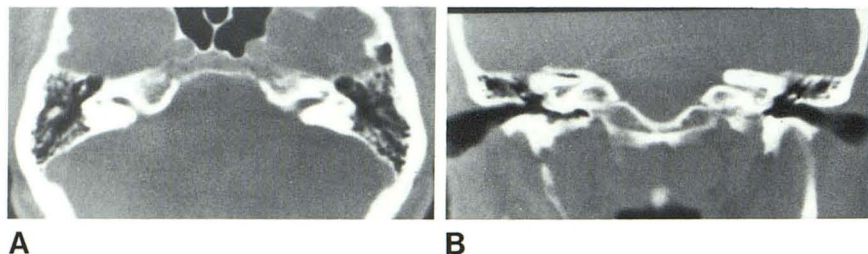


Fig. 1.—Anteverted internal auditory canals. **A**, Axial CT shows symmetrically anteverted canals with slight, anteriorly convex curve. Mild brachycephaly. **B**, Coronal CT shows effect of thin sectioning on angled cylinder. Canals show apparent medial narrowing, which is artifactual.

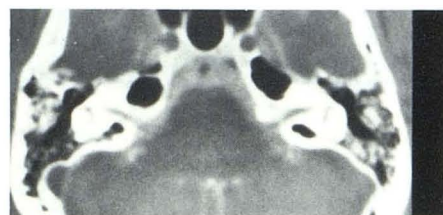

Fig. 2.—Anteverted internal auditory canals in association with pneumatization of petrous bone. Coronal CT, also with metrizamide, as well as pluridirectional tomography, demonstrated marked narrowing of both canals.

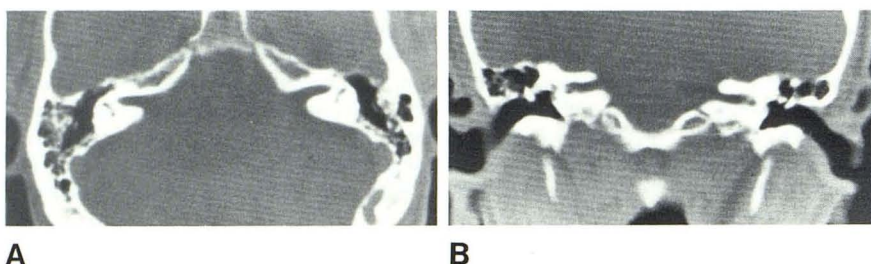


Fig. 3.—Normal internal auditory canals in patient with left-sided tinnitus but no hearing loss. **A**, Axial CT shows mildly patulous canals and slight asymmetric anteversion on left. **B**, Coronal CT shows no significant medial narrowing because canals are relatively straight.

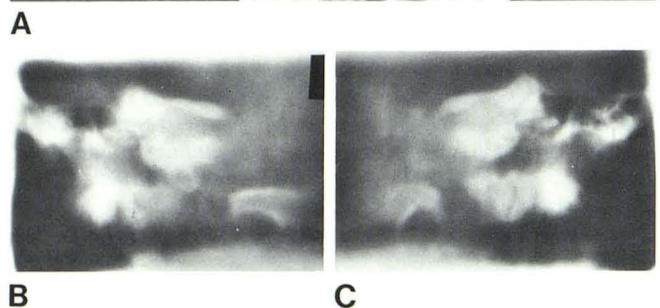
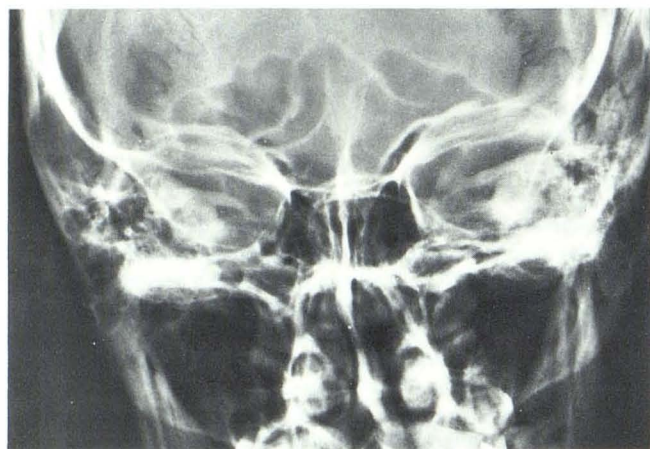


Fig. 4.—Medial narrowing, normal configuration, in patient with normal hearing. **A**, Posteroanterior view suggests true medial narrowing or "barreling." **B** and **C**, Right and left coronal pluridirectional tomograms confirm this extreme example of common configuration.

#### Embryology

The pathogenesis of this condition is likely to be developmental because the internal auditory canals are unlikely to change course markedly and symmetrically in adult life.

The otocyst and statoacoustic ganglion arise at 3–5 weeks gestation [5], while the axons from the ganglion join the brainstem around week 12 [6]. Ossification of the internal auditory canal begins in the fifth month and is complete by the sixth [7]. An anteverted course of the internal auditory canals could, therefore, result from an anomaly of induction between the statoacoustic ganglion and the brainstem.

#### Function

Correlation of this symmetric variation of structure of the internal auditory canals with clinically observable, functional deficit is incomplete. Of our three patients, only one had significant bilateral hearing loss. The other two had asymmetric or unilateral hearing loss. A different pair had a retrocochlear localization of hearing loss. Still a different pair had significant loss of vestibular function on electronystagmographic testing.

These observations do not strongly support a congenital origin for the functional deficits because of their asymmetry and their onset in adult life. Occasionally, however, a congenital or developmental structural defect may not become functionally manifest until adulthood.

The absence of facial nerve dysfunction supports a hypothesis involving an abnormality in the development of the statoacoustic ganglion, or its interaction with the brainstem, because the motor division of the facial nerve is derived from the facial nucleus, in the

brainstem, rather than the otocyst or its derived eighth nerve ganglion, both of which are peripheral. The absence of a severe (e.g., Mondini) inner ear anomaly, however, militates against a primary defect in the development of the otocyst.

Audiologic testing showed a retrocochlear defect in two cases, and uncertain localization in the third. This supports a hypothesis involving dysfunction of axons, rather than of acoustic ganglion cell bodies or their dendritic receptors.

The observed eighth nerve dysfunction may be coincidental, but it could be axonally mediated. As such, it could be related to a developmental variation in the induction of axonal connections of the eighth nerve ganglion with the brainstem. This anomaly, possibly in combination with a chronic mechanical effect on the axons along an unusual course of the internal auditory canals, could produce the observed, late eighth nerve dysfunction. The absence of seventh nerve involvement is difficult to explain but is not unlike the situation with an "acoustic neuroma" in which, despite significant mass effect on the facial nerve, dysfunction of the latter is rare or absent.

#### REFERENCES

1. Valvassori GE, Pierce RH. The normal internal auditory canal. *AJR* **1964**;92:1232-1241
2. Valvassori GE, Naunton RF, Lindsay JR. Inner ear anomalies. *Ann Otol Rhinol Laryngol* **1969**;78:929-938
3. Jensen J. Congenital anomalies of the inner ear. *Radiol Clin North Am* **1974**;12:473-482
4. Lloyd GAS, du Boulay GH, Phelps PD, Pullicino P. The demonstration of the auditory ossicles by high resolution CT. *Neuroradiology* **1979**;18:243-248
5. Pearson AA, Jacobson AD. The internal ear. In: *The development of the ear*. Rochester, MN: Amer. Acad. Ophthalmol. Otolaryngol., **1967**: 1-50
6. Ormerod FC. The pathology of congenital deafness. *J Laryngol Otol* **1960**;74:919-950
7. Anson BJ, Donaldson JA. *Surgical anatomy of the temporal bone*. Philadelphia: Saunders, **1981**: 83