



Get Clarity On Generics

Cost-Effective CT & MRI Contrast Agents



WATCH VIDEO

AJNR

Importance of auditory brainstem responses in the CT diagnosis of traumatic brainstem lesions.

M Zuccarello, D L Fiore, K Pardatscher, A Martini, A Paolin, G Trincia and G C Andrioli

AJNR Am J Neuroradiol 1983, 4 (3) 481-483

<http://www.ajnr.org/content/4/3/481>

This information is current as of August 17, 2025.

Importance of Auditory Brainstem Responses in the CT Diagnosis of Traumatic Brainstem Lesions

M. Zuccarello,¹ D. L. Fiore,² K. Pardatscher,² A. Martini,³ A. Paolin,⁴ G. Trincia,¹ and G. C. Andrioli¹

Changes in brainstem auditory-evoked potential response were serially investigated in 20 head-injury patients with neurologic and computed tomographic signs of brainstem lesion. The reliability of computed tomography in the evaluation of indirect signs of brainstem lesion from the image was investigated with elaboration of the brainstem auditory-evoked potential response. The measurement of auditory brainstem response is thought to be useful in detecting the severity and predicting possible recovery in posttraumatic brainstem injury. Brainstem deformity on computed tomography was a bad prognostic sign, indicating irreversible structural change.

Clinical features that reflect the severity of brain dysfunction are extremely important in monitoring the progress of head-injury patients, but a more detailed assessment of anatomic and functional disorders in the brain may be provided by a variety of investigative techniques. Computed tomography (CT) is a rapid, noninvasive method; however, it does not reflect the functional condition of the central nervous system, and some anatomic regions (e.g., the posterior cranial fossa) present difficulty in choosing the appropriate investigation, particularly with head-injury patients. The direct CT demonstration of posttraumatic brainstem lesions is considered reliable by many authors [1, 2], but the indirect evidence is quite uncertain. We tried to verify the reliability of CT in the evaluation of indirect signs of brainstem lesions with the aid of brainstem auditory-evoked potential responses (BAERs) [3–5].

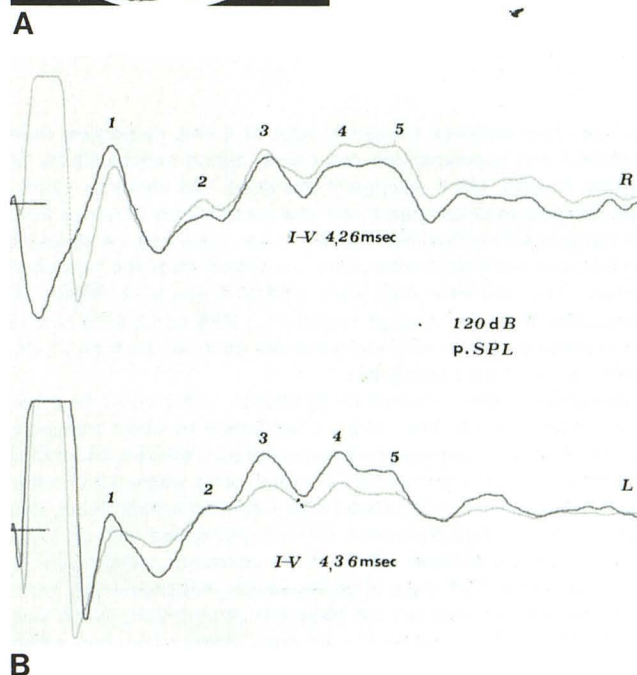
Materials and Methods

BAERs were recorded in 20 severely injured comatose patients admitted to neurosurgery at University Hospital, Padova, over a 10 month period. The criteria for including patients in the series included: aged 15–55 years; absence of temporal bone fracture on skull films; absence of anamnestic otologic pathology; normal canal by otomicroscopy; and presence of a posttraumatic lesion on CT scan. All BAERs were recorded and analyzed at least once, and some many times, according to the clinical course from time of head injury to final outcome.

Click signals (0.1 msec impulses of alternating polarity) were presented monaurally through electromagnetically shielded earphones at an intensity of 110 dB peak-equivalent sound pressure level (which corresponds to 80 dB hearing level) and at a rate of 21/sec. BAERs were recorded from conventional electroencephalographic (EEG) electrodes (vertex–ear lobe), amplified $\times 10^5$ at a

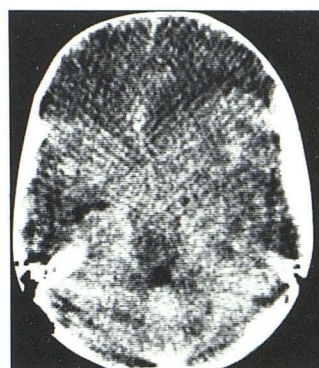

Fig. 1.—CT (A) and BAERs (B). Left extradural hematoma, obliteration of basal cisterns, and contralateral temporal horn dilatation. Interpeak latency of wave I–V is not more than 4.48 msec (grade 2).



band pass of 200–2,000 Hz, and averaged over a 10 msec time base. An artifact rejection device stopped triggering the averager sweeps when the EEG exceeded a preset value.

A total of 2,048 clicks was presented for each averaged re-

¹Department of Neurosurgery, University Hospital, Via Giustiniani 5, 35100 Padova, Italy. Address reprint requests to M. Zuccarello.

²Department of Neuroradiology, University Hospital, 35100 Padova, Italy.

³Department of Otolaryngology, University Hospital, 35100 Padova, Italy.

⁴Department of Anesthesiology, University Hospital, 35100 Padova, Italy.

TABLE 1: Clinical and Laboratory Findings in Traumatic Brainstem Lesions

Grade: Case No.	GCS	Brainstem Reflexes								CT Scan	Outcome
		Pupillary		Corneal		Oculocephalic		Decerebration			
		L	R	L	R	L	R	L	R		
Grade 1 (BAER I-V latency 4.07 ± 0.19 msec):											
1	6	+	+	+	+	+	+	+	—	+	Recovery
2	8	+	+	+	+	+	+	—	—	Normal	Recovery
3	7	+	+	+	+	+	+	—	—		+
4	7	+	+	+	+	+	+	—	—	Normal	Recovery
5	4	+	+	+	+	+	+	+	+		+
6	8	+	+	+	+	+	+	—	—	+	Recovery
Grade 2 (BAER I-V latency < 4.48 msec):											
7	8	+	+	+	+	+	+	—	—	+	Recovery
8	6	+	—	+	+	+	—	—	—	++	Recovery
9	5	—	—	+	+	—	—	+	+	++	PVS
10	7	+	+	+	+	+	+	—	—	++	Recovery
11	6	+	+	+	+	+	+	—	—	++	Recovery
Grade 3 (BAER I-V latency > 4.48 msec):											
12	5	+	+	+	+	+	+	—	+	++++	Death
13	5	+	—	+	—	+	—	+	—	++++	Death
14	5	+	—	+	+	+	—	+	—	++++	Death
15	4	—	+	+	+	—	+	+	+	++++	Death
16	4	—	—	+	+	—	—	+	+	++++	Death
17	5	—	+	+	+	—	+	+	+	++++	Death
Grade 4 (only wave I present):											
18	6	—	+	+	+	—	+	—	—	++++	Death
19	8	+	+	+	+	+	+	—	—	++++	Death
20	5	+	—	+	+	+	—	—	+	++++	Death

Note.—GCS = Glasgow coma score; PVS = persistent vegetative state; L = left, R = right; + = present, - = absent; CT scan: + = cistern compression; ++ = cistern compression and contralateral temporal horn dilatation; +++ = cistern compression, contralateral temporal horn dilatation, and brainstem deformation.

sponse. Two separate trials/averages of 2,048 responses were recorded and superimposed per ear to define reproducibility of results. Amplaid MK 6 equipment was used. The data from comatose patients were compared with the mean values obtained from 10 subjects with normal hearing. The mean value and the standard deviation of each parameter were calculated from the reference sample. The reference data were plotted in terms of ellipses of probability, the axes of which represent a 99% confidence limit in the reference sample. Other parameters such as intervals P_1 - P_5 and P_3 - P_5 were also calculated.

All patients were comatose on admission, with a Glasgow coma score of less than 8. The clinical examination included brainstem reflexes (pupillary, corneal, and oculocephalic reflexes) and motor responses. All patients had a CT examination within 12 hr after injury, entered into a clinical head-injury management protocol, and were given standard treatment. CT was performed with an Ohio Nuclear Delta 25 scanner with an 8 mm collimator, using a 256×256 matrix. Direct CT signs of posttraumatic brainstem injury were never present. In all cases the diagnosis of brainstem lesion was made only on the basis of one or more indirect findings, which included obliteration of pontine, cerebellopontine, or perimesencephalic cisterns; obliteration of the suprasellar cistern with widening of the ipsilateral cerebellopontine angle cistern; contralateral temporal horn dilatation; and brainstem deformation and foreshortening.

Results

The overall analysis of BAERs enabled us to define four grades of trauma injury: *grade 1*: BAERs are indistinguishable from those seen in normal subjects with regard to morphology and latencies of waves I-V (4.07 ± 0.19 msec; III-V = 1.79 ± 0.17 msec); *grade 2*: waves I-V are clearly discernible, but there is a delay in the

interpeak latency of waves I-V not greater than 4.48 msec; *grade 3*: waves I-V are clearly discernible, but the delay in the interpeak latency of waves I-V is greater than 4.48 msec. This seems to be incompatible with a functional brainstem recovery; and *grade 4*: only wave I is clearly present. Once these grades were determined the early CT scan of each patient was studied and the indirect signs of probable brainstem lesion noted. The patients were then classified on the basis of their BAER grades.

We found that all patients assigned to grades 1 and 2 presented only cistern obliteration with or without the contralateral temporal horn dilatation as indirect signs of brainstem injury (fig. 1). All those patients with grades 3 and 4 had brainstem deformation beyond the above-mentioned signs (fig. 2). All the grades 1 and 2 patients had a good recovery, while all those of grades 3 and 4 died (table 1).

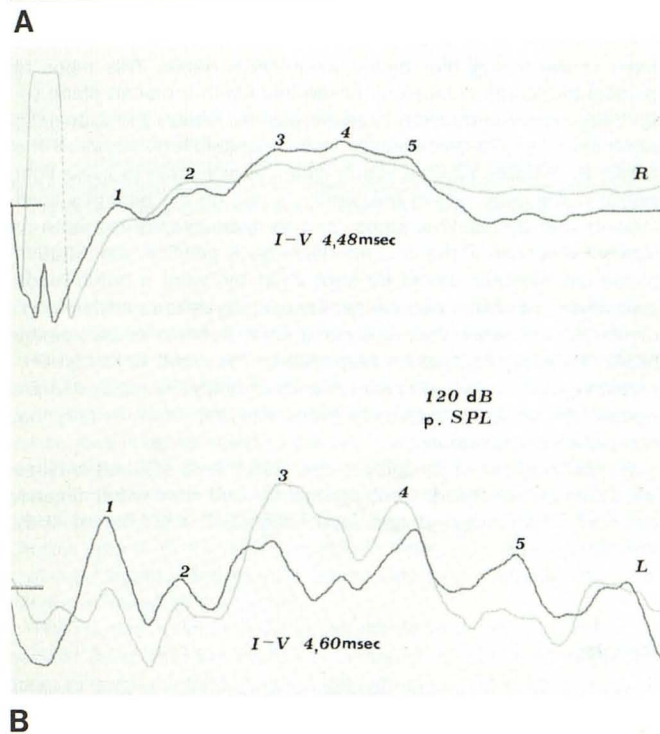
Discussion

It is well known how prognostically important the correct diagnosis of posttraumatic brainstem injury is. CT is capable of providing either direct or indirect demonstrations; but while the former are based on direct evidence of lesion (such as hemorrhage or edema), the latter are based on indirect signs that are equivocal per se and influenced by the particularly bad clinical and technical conditions that are typical of head-injury patients.

We must stress that in our series BAERs were never affected by nonneurologic factors (e.g., otologic ones). Our results point out clearly that only the presence of brainstem rotation or foreshortening is a sure sign of functional and structural brainstem alteration. In contrast, the presence of cistern compression only and its disappearance with or without contralateral temporal horn dilatation is, in our experience, indicative of functional and reversible brainstem involvement. In fact, in such cases the initial BAERs were

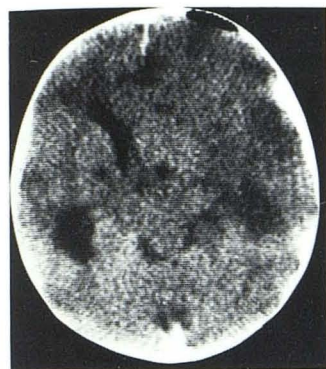

Fig. 2.—CT (A) and BAERs (B). Left cerebral contusion, brainstem rotation, and contralateral temporal horn dilatation. Interpeak latency of wave I-V is more than 4.48 msec (grade 3).



sometimes abnormal, but subsequently improved concomitant with the gradual improvement of the clinical status of the patients.

According to Greenberg et al. [3], BAERs can identify dysfunctional quiescent neurons capable of recovery and can discriminate these from neurons that are dead or incapable of normal function. It seems reasonable to assume that the BAERs give us an objective parameter with which to assess the severity of brainstem injury, thus allowing us to avoid equivocal diagnosis based on indirect CT signs.

REFERENCES

1. Tsai FY, Teal JS, Quinn MF, et al. CT of brainstem injury. *AJNR* 1980;1:23-29, *AJR* 1980;134:717-723
2. Zuccarello M, Fiore DL, Trincia G, De Caro R, Pardatscher K, Andrioli GC. Traumatic primary brainstem haemorrhage. Clinical and experimental study. *Acta Neurochir* 1983;67:103-113
3. Greenberg RP, Newlon PG, Hyatt MS, Narayan RK, Becker D. Prognostic implications of early multimodality evoked potentials in severely head-injured patients. *J Neurosurg* 1981;55:227-236
4. Lindsay KW, Carlin J, Kennedy I, Fry J, McInnes A, Teasdale GM. Evoked potentials in severe head injury analysis and relation to outcome. *J Neurol Neurosurg Psychiatry* 1981;44:796-802
5. Seales DM, Rossiter VS, Weinstein ME. Brainstem auditory evoked responses in patients comatose as a result of blunt head trauma. *J Trauma* 1979;19:347-353