



Get Clarity On Generics

Cost-Effective CT & MRI Contrast Agents

 FRESENIUS
KABI

WATCH VIDEO

AJNR

Treatment of cerebral arteriovenous malformations: combined neurosurgical and neuroradiologic approach.

L D Cromwell and A B Harris

AJNR Am J Neuroradiol 1983, 4 (3) 366-368

<http://www.ajnr.org/content/4/3/366>

This information is current as of August 21, 2025.

Treatment of Cerebral Arteriovenous Malformations: Combined Neurosurgical and Neuroradiologic Approach

Laurence D. Cromwell¹ and A. Basil Harris²

Experience with 31 intraoperative embolizations performed on 23 patients is reported. The procedure involves the direct injection of embolic material into the main arterial feeders during craniotomy. The combined effort involves the exposure of the lesion at craniotomy, standard arteriotomy, and fluoroscopically monitored intravascular infusion of contrast material followed by the injection of bucrylate (IBCA, Ethicon, Somerville, NJ) mixed with tantalum or Pantopaque into the feeding vessels and into the interstices of the malformation. It was concluded that the procedure significantly diminishes operating time and blood loss for the lesions that were subsequently resected. Fluoroscopy coupled with high-quality stop-frame videotape recording allows a detailed study of the flow characteristics of the malformation so that polymerization time can be regulated appropriately. Follow-up varied from 3 months to 4½ years. There were two deaths related to the procedure and one additional complication of cortical blindness that partially resolved. None of the survivors rebled. Most of the survivors improved.

The deliberate embolic occlusion of arterial feeders into arteriovenous malformations (AVMs) is receiving wide acceptance. The introduction of polymers by a catheter is used either alone or as an adjunct to surgery in an attempt to reduce the size and vascularity of the lesions. In order for this procedure to be helpful, normal brain must be preserved. The angiographer must position the catheter very selectively in order to maintain control over deposition of the occluding agent. However, this may not always be technically possible as the malformation may either be peripheral or the feeding vessels may be tortuous. In addition it is not always possible to embolize the entirety of the malformation.

Because of technical problems that are sometimes encountered in getting the catheter to the malformation from the percutaneous approach and because of less than complete obliteration of the malformation, we attempted to treat some patients by direct injection of the embolic material into the arterial feeder during craniotomy. Previously we reported our success in developing a mixture of Pantopaque and bucrylate, which gives a reproducible and predictable change in polymerization time and which forms a stable and miscible solution [1].

Subjects and Methods

Our treatment procedure involves injecting on one extreme a 50% mixture of Pantopaque and bucrylate, which polymerizes in

about 3 sec, or, on the other extreme, a mixture of tantalum and bucrylate, which polymerizes in less than 1 sec [1].

Our technique [2] involves a craniotomy in the operating room, during which time the appropriate available cortical vessels are isolated and in turn catheterized using standard arteriotomy techniques. We then obtain an intraoperative angiogram using a C-arm fluoroscope and a high-quality Siemens tape recorder and attempt to estimate the rapidity with which the malformation fills and empties (fig. 1A). The tape recorder obtains 60 frames/sec; the playback stop-frame quality is superb and is almost as good as the real-time image itself. By counting the number of frames and appropriately adjusting our injection volume of contrast material we can estimate both the necessary volume of bucrylate to be injected as well as the rapidity with which it should polymerize. Assuming that the catheter is properly located we then inject the appropriate mixture of bucrylate and Pantopaque or tantalum. We again monitor the deposition of the occluding agent with the C-arm fluoroscope and the high-quality Siemens Siricord tape recorder (fig. 1B). Additional feeders can then be angiographed and embolized in turn.

The subgroup of patients discussed in this communication deals exclusively with those who were treated with the combined neurosurgical and neuroradiological approach. This combined approach represents a subgroup of our experience. We wish to emphasize that this particular procedure is not a cure-all. However, we believe that there is a certain subset of patients who are best served by a combined neurosurgical and neuroradiological approach, and it is to this subset of patients that we direct our attention in this communication.

Patient Series Summary

Our series comprised 13 males and 10 females 14–68 years old. Nine patients had parietal lesions (four on the left). Seven patients had cranial AVMs outside the brain substance. One patient had a cerebellar lesion. The other patients had temporal, frontal, and occipital lesions. The most common presenting symptoms included headaches (seven patients), a history of subarachnoid hemorrhage (12 patients), and seizures (six patients).

The 23 patients had 31 operations. Twenty-two patients were embolized intraoperatively. The twenty-third patient with a left parietal AVM was operated on under a local anesthesia so that corticography could be performed. We were unable to either surgically remove or to embolize the malformation without causing a profound aphasia. Sixteen of our 23 patients were operated on once, five were operated on twice, and one had four operations.

L. D. Cromwell and A. B. Harris are affiliates of the Child Development and Mental Retardation Center.

¹ Department of Radiology, University of Washington School of Medicine, Seattle, WA 98195. Address reprint requests to L. D. Cromwell.

² Department of Neurological Surgery, University of Washington School of Medicine, Seattle, WA 98195.

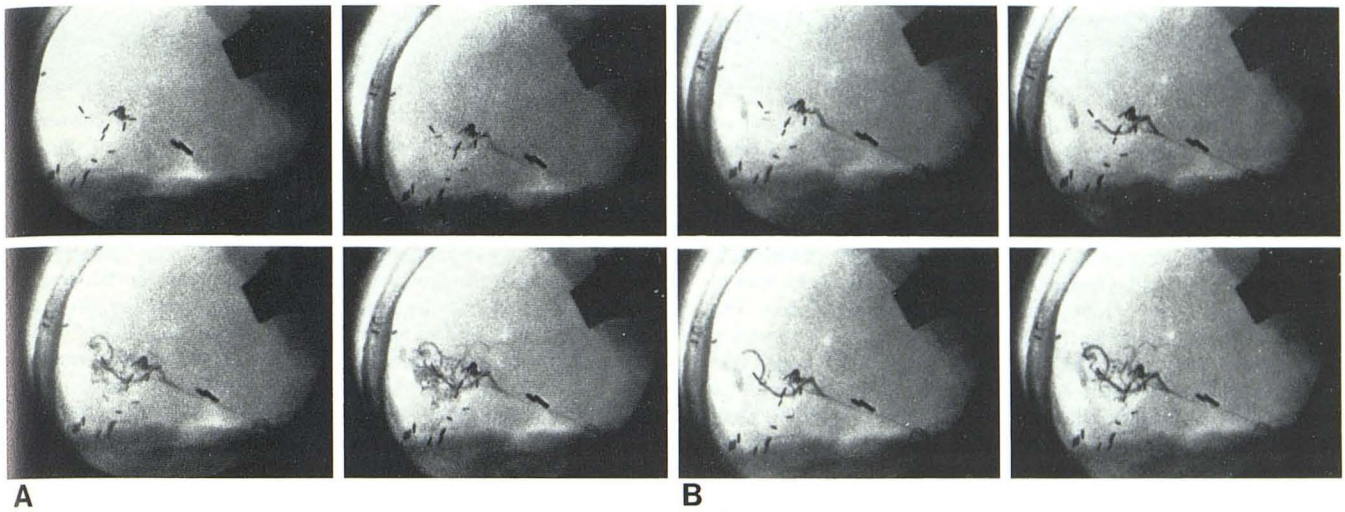


Fig. 1.—A, Several stop-frames selected from intraoperative angiogram illustrate dynamics of flow in typical AVM. B, Stop-frames from actual intraoperative embolization demonstrate intraarterial deposition of bucrylate mixed with tantalum.

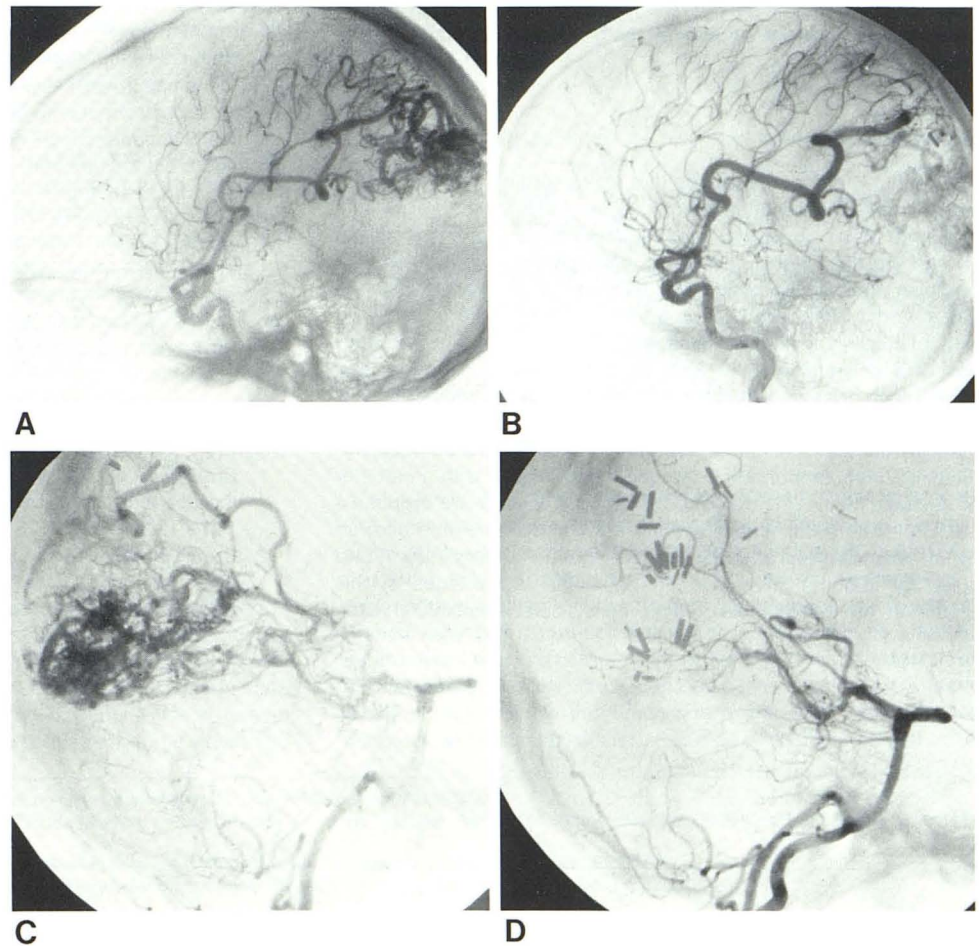


Fig. 2.—A, Preembolization angiogram shows peripheral AVM in parietal occipital region. Large cortical feeder supplies superior part of AVM. B, Postintraoperative embolization angiogram demonstrates obliteration of superior part of malformation previously supplied by one large cortical feeder. C, Inferior and residual part of malformation fed by posterior circulation. D, Final postsurgical angiogram demonstrates no residual AVM.

Eleven patients underwent intraoperative embolization without surgical removal of the AVM. Another 11 patients had both intraoperative embolization and surgical removal. Four of these patients were embolized and had their AVM removed at the same sitting. Another four were embolized intraoperatively two or more times before surgical removal. The other three patients had embolization and then surgical removal of their malformation at a subsequent sitting.

A typical intraoperative embolization and subsequent surgical procedure are illustrated in figure 2. The patient was a 25-year-old man with severe headaches and a recent subarachnoid hemorrhage. He had a right homonymous inferior quadrantanopsia. The preoperative angiogram (fig. 2A) illustrates the superior portion of the parietal occipital malformation. The large cortical feeder was embolized intraoperatively and the patient was returned on another day to the angiographic suite for follow-up angiography (fig. 2B). Figure 2C demonstrates the inferior portion supplied by the posterior circulation. It was not technically feasible to embolize this malformation at surgery so standard surgical procedures were performed to remove the inferior portion of the malformation. Figure 2D illustrates the final angiographic appearance after embolization of the superior portion and subsequent surgical removal of the portion fed by the posterior circulation.

Two deaths occurred. One patient died of pulmonary complications and a second patient bled immediately after the embolization procedure. There was one other complication, that of cortical blindness, which has only partially resolved. None of the survivors has rebled. Seventeen of our patients had postembolization follow-up angiograms, and in all patients the malformation was either almost completely obliterated angiographically or only a small residual remained.

Discussion

AVMs are formidable lesions that make surgical removal sometimes impossible and often difficult. Some AVMs are not resectable and in the past therapy has been directed toward partial occlusion by clipping the feeding vessels or intravascular embolization with particles and Silastic beads. We believe that surgical excision is still the best treatment when it is technically possible to carry out without causing significant damage to adjacent brain. The introduction of a polymer into the AVM by percutaneous catheter used either alone or as an adjunct to surgery has helped another subset of patients. However, in our experience it is seldom possible to embolize an entire malformation percutaneously. Because the radiologist often cannot reach the peripheral lesions with a catheter or because he may be deterred by tortuous vessels, we propose a combined effort with exposure of the lesion and craniotomy followed by intravascular deposition of the glue into the feeding vessels and hopefully into the interstices of the AVMs. Advantages of this procedure are that multiple cortical vessels can be embolized at the

same sitting. In addition this technique facilitates the introduction of the polymer into the nidus of the AVM itself, which can obliterate the shunt.

Originally our goal was to use intraoperative embolization as an adjunct to and as a means of facilitating surgical removal. However, after several years experience we point out that 11 of our 23 patients were only embolized. Only four patients were embolized and had surgical removal of their AVM at the same sitting.

Another advantage of intraoperative embolization is when the AVM is in the dominant hemisphere near the speech centers. It is necessary to perform provocative speech testing and corticography in the awake patient before the malformation is removed. We have performed this operative technique on two patients, one of whom we were able to embolize and surgically remove the malformation without any subsequent neurologic deterioration. In a second patient it was not possible to perform either embolization or surgery without producing a profound aphasia, thus the malformation was undisturbed.

Disadvantages of intraoperative embolization include all the risks of a major operation. One of our patients died not so much as a result of the embolization and intracranial surgery but rather from pulmonary empyema and subsequent sepsis, a direct result of an operation. Infarction and edema can be a problem after intraoperative embolization. In addition, if the embolic material passes through the malformation and blocks a major draining vein, the collateral veins may not be able to withstand the arterialized pressure. We believe this is the cause of death in the second of our two patients.

Finally we must point out that the use of IBCA in these procedures is experimental; an investigational device exemption from the Food and Drug Administration is required.

In conclusion, we believe that this is a useful procedure for a certain subset of patients but is not a panacea. That we have had few complications reflects not the basic simplicity and safety of the procedure but the fact that we have selected our patients with great care and have attempted intraoperative embolization and surgery on only a few of them. We are still unsure as to exactly which patient will benefit from just embolization or just surgery or a combination of various types of embolization followed by surgery. The treatment of cerebral AVMs is still under development. That there is no simple cure can be attested to by the fact that there is a plethora of therapeutic possibilities.

REFERENCES

1. Cromwell LD, Kerber CW. Modification of cyanoacrylate for therapeutic embolization: preliminary experience. *AJR* 1979;132:799-801
2. Cromwell LD, Harris AB. Treatment of cerebral arteriovenous malformations: a combined neurosurgical and neuroradiological approach. *J Neurosurg* 1980;52:705-708