

**Get Clarity On Generics**

Cost-Effective CT & MRI Contrast Agents

 FRESENIUS  
KABI

WATCH VIDEO

**AJNR**

**Intravenous digital subtraction angiography with  
iohexol.**

E D Cacayorin, A D Bernstein, C T Fruehan, S H Lee and S A  
Kieffer

*AJNR Am J Neuroradiol* 1983, 4 (3) 329-332  
<http://www.ajnr.org/content/4/3/329>

This information is current as  
of August 10, 2025.

# Intravenous Digital Subtraction Angiography with Iohexol

Edwin D. Cacayorin,<sup>1</sup> Allan D. Bernstein,<sup>1</sup> C. Thomas Fruehan,<sup>2</sup> Seungho H. Lee,<sup>1</sup> and Stephen A. Kieffer<sup>1</sup>

**Iohexol is a nonionic water-soluble iodinated contrast medium with chemical and physical properties similar to those of metrizamide. A randomized double-blind study was performed in 40 patients undergoing intravenous digital subtraction angiography for suspected carotid and vertebral disease to compare the radiographic imaging quality and side effects of iohexol with those of Renografin-76 (diatrizoate meglumine and diatrizoate sodium). The use of iohexol yielded a higher percentage of "excellent" images with a lesser incidence of image degradation due to swallowing and motion. Iohexol was also associated with milder and less frequent patient discomfort. No clinically significant changes in laboratory data parameters were observed with either contrast medium.**

Iohexol\* (Sterling-Winthrop Research Institute, Rensselaer, NY) is a new nonionic water-soluble iodinated contrast medium intended for intravascular and myelographic use [1-3]. The physical and chemical characteristics of iohexol are similar to those of metrizamide, but iohexol has the advantage of being available in solution stable to autoclaving.

In intravenous digital subtraction angiography (DSA), movement and swallowing are frequently associated with injection of currently available ionic contrast media and constitute a major cause of image quality degradation, particularly in the study of the cervical vessels [4, 5]. Experimental and clinical observations indicate that contrast materials with low osmolality in aqueous solution cause less patient discomfort than hyperosmotic media [6]. Early clinical experience has shown that iohexol, a contrast agent with low osmolality, is safe and well tolerated when injected intravenously or intraarterially [7, 8].

We report the results of a randomized double-blind study designed to compare the safety, tolerance, and imaging effectiveness of iohexol with Renografin-76 (diatrizoate meglumine and diatrizoate sodium) when these contrast media are used for DSA. The physical and chemical characteristics of the two contrast media are given in table 1.

## Subjects and Methods

Forty patients (35 outpatients, five inpatients) undergoing DSA as part of a clinical workup for suspected cerebrovascular disease were subjects of a randomized double-blind study designed to compare the contrast media iohexol (350 mg I/ml) and Renografin-76 (370 mg I/ml). Of the 20 patients studied with iohexol, 19 had

a history of transient ischemic attacks (TIA) localized to the carotid circulation, whereas one patient was clinically considered to have pseudotumor cerebri but underwent DSA to exclude possible cerebrovascular disease. Of the 20 patients studied with Renografin-76, 14 presented with a history of TIA, four with symptoms or signs of vertebrobasilar insufficiency, one with severe headaches, and one with a suspected intracranial aneurysm. Twenty-one women (11 with iohexol, 10 with Renografin-76) and 19 men (nine with iohexol, 10 with Renografin-76) were included in the study (age range, 29-85 years; mean ages, 65 years for Renografin-76 patients, 58 years for iohexol patients). Criteria for exclusion were pregnancy and known allergy to iodinated contrast material.

In all patients, the Seldinger technique was used for percutaneous placement of a 6 French polyethylene multi-side-hole, single-end-hole catheter into the superior vena cava (38 patients) or inferior vena cava (two patients). No premedication was given. Forty-five ml of contrast material per injection was administered at a rate of 15 ml/sec. Routine bilateral oblique projections for visualization of both carotid bifurcations were obtained for TIA patients. Anteroposterior and/or lateral intracranial views and an aortic arch projection were also obtained when the oblique views demonstrated moderate to severe atherosclerotic disease of the cervical arteries. Oblique carotid bifurcation projections and a single lateral posterior fossa or anteroposterior Towne projection were obtained in patients with clinically suspected vertebrobasilar insufficiency.

Angiography was performed on a Technicare DR 960 digital subtraction unit using a 512 × 512 matrix with a 9 inch (22.9 cm) mode for the aortic arch projections and a 5 inch (12.7 cm) mode for the cervical and intracranial views. Using 75 kVp and 12 mAs per frame as exposure factors for the cervical views, the estimated skin entrance exposure is 70 mR ( $0.18 \times 10^{-4}$  C/kg) per frame. Each sequence usually consists of 15 exposures at 1.25 frames/sec. The digital imaging system has a spatial resolution of about 1.8 line pairs/mm for the 512 × 512 matrix with a 5 inch (12.7 cm) mode and one line pair/mm with a 9 inch (22.9 cm) mode. A constant focal spot of 1.2 mm was used.

Pre- and postprocedural vital signs, electrocardiograms (ECGs), and blood profiles (hematocrit, hemoglobin, red blood cell count, white blood cell count, differential, platelet count, sedimentation rate, prothrombin time, and serum creatinine) were obtained in all patients. ECG readings were recorded to evaluate changes in the S-T segment, Q-T interval, and T-wave amplitude before and 1 and 2 min after each injection; these were analyzed by a cardiologist.

Discomfort during injection was subjectively assessed by both the patient and the physician performing the procedure. After each injection, the patient was questioned as to the type (heat, pain,

\* Chemical formula: N, N' - bis (2, 3-dihydroxypropyl)-5-[N-(2, 3-dihydroxypropyl) acetamido]-2, 4, 6-triiodoisophthalamide.

<sup>1</sup> Department of Radiology, SUNY Upstate Medical Center, 750 E. Adams St., Syracuse, NY 13210. Address reprint requests to E. D. Cacayorin.

<sup>2</sup> Department of Medicine, SUNY Upstate Medical Center, Syracuse, NY 13210.



cramp, other) and intensity of discomfort experienced (graded as "mild" for slight discomfort, "moderate" for definite but tolerable discomfort, and "severe" for excruciating discomfort). The physician performing the procedure, unaware of which contrast medium had been injected, also graded the patient's discomfort and in addition noted the presence of motion, swallowing, or coughing during or after each injection. The patient's account of the intensity of discomfort was given precedence when this differed from the physician's evaluation.

The quality of radiographic visualization was evaluated by an independent radiologist who was also unaware of which contrast

medium had been used. Images were rated "poor" when radiographic delineation of opacified arteries was insufficient for diagnosis, "good" when there was adequate diagnostic information despite image degradation due to swallowing or motion, and "excellent" when images were free of motion artifacts and demonstrated sharp delineation of the opacified arteries. Images with arterial segments partly obscured because of swallowing or motion, in which the vessels of primary interest were not significantly affected, were rated "good."

The outpatients were contacted by telephone and questioned about any adverse reactions within 48 hr after the study. Inpatients were similarly evaluated at 24 hr postexamination, at which time blood profiles were also obtained.

TABLE 1: Comparison of Iohexol and Renografin-76 for Intravenous Digital Subtraction Angiography

Criteria for Comparison	Iohexol	Renografin-76
No. of patients	20	20
No. of injections	65	72
Physical and chemical characteristics:		
Molecular weight	821	614
% iodine	46.4	62
Concentration (mg I/ml)	350	370
Osmolality (mol/kg H <sub>2</sub> O)	0.88	2.07
Viscosity (centipoise*):		
At 20°C	23.3	15.5
At 37°C	10.6	8.4
Radiographic imaging quality:		
Poor	0	0
Good	10 (15.4)	27 (37.5)
Excellent	55 (84.6)	45 (62.5)
Degree of patient discomfort:		
Mild	43 (66)	35 (49)
Moderate	22 (34)	32 (44)
Severe	0	5 (7)
Signs of patient discomfort:		
Motion	0	6 (8.3)
Swallowing	11 (17)	25 (35)
Coughing	0	4 (5.5)

Note.—Values in parentheses are percentages.  
\* 1 poise = 10<sup>-1</sup> Pa.s (SI unit).

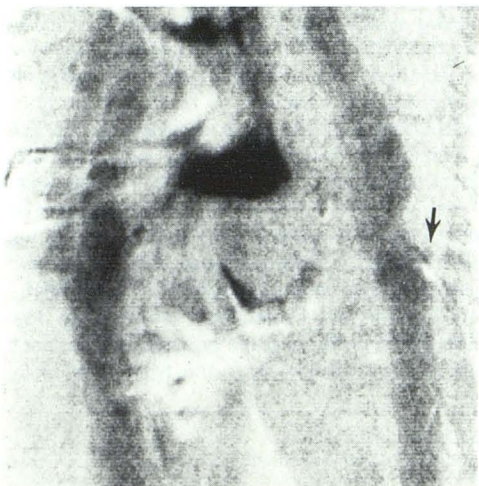
## Results

### Radiographic Imaging Quality

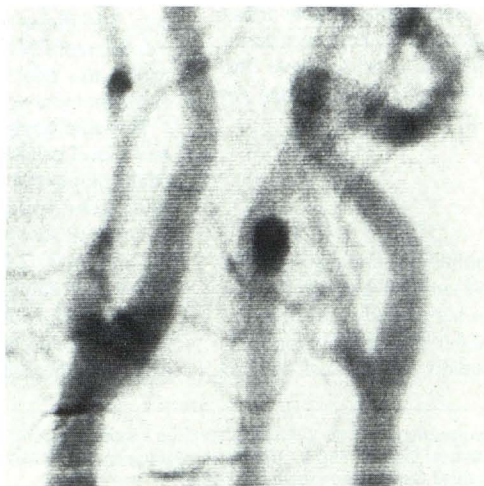
The study data comprised 65 DSA sequences in 20 patients for iohexol and 72 DSA sequences in 20 patients for Renografin-76. Data are summarized in table 1. The use of iohexol yielded 55 (84.6%) excellent and 10 (15.4%) good radiographic images. The images obtained with Renografin-76 were graded as excellent in 45 sequences (62.5%) and good in 27 (37.5%). The images rated good were attended by motion or swallowing but provided sufficient diagnostic information about arterial patency and contour (fig. 1). The images judged excellent were free of misregistration artifacts from motion or swallowing (figs. 2, 3A, and 4A).

### Discomfort

In 43 (66%) injections of iohexol, the patient experienced mild discomfort (a mild sensation of heat), while in 22 (34%) moderate discomfort was perceived. Discomfort with Renografin-76 was regarded as mild in 35 injections (49%), moderate in 32 (44%), and severe in five (7%). Swallowing was observed in 11 sequences (17%) with iohexol and in 25 sequences (35%) with Renografin-76. Motion was noted in six sequences and coughing episodes occurred in four sequences with Renografin-76. No apparent movement or coughing was observed with the iohexol injections.



1



2

Fig. 1.—DSA with Renografin-76 in 70-year-old woman presenting with transient ischemic attacks (TIA) in left hemisphere. Right posterior oblique projection. Moderate narrowing of left common carotid artery bifurcation and origin of left internal carotid artery due to atherosclerotic plaque formation posterolaterally. Probable ulceration of left common carotid bifurcation (arrow). Artifacts from swallowing partly obscure right common and right cervical internal carotid arteries, but left common carotid and left internal carotid arteries are not significantly affected. Image quality rated good.

Fig. 2.—DSA with iohexol in 64-year-old woman evaluated for TIA. Right posterior oblique projection. Study interpreted as normal. Image quality rated excellent.



Fig. 3.—DSA with iohexol in 54-year-old woman presenting with TIA. **A**, Right posterior oblique projection. Right internal carotid artery completely occluded in proximal segment (*large arrow*). Severe narrowing of right common carotid bifurcation, left common carotid artery, and origins of left internal and external carotid arteries. Multiple irregularities, probably representing areas of ulceration, along anterolateral aspect of distal left common carotid artery and proximal left internal carotid artery (*small arrows*). Image quality rated excellent. **B**, Towne projection. Predominating posterior fossa circulation with bilaterally enlarged vertebral arteries. Internal carotid circulations only faintly opacified, while cervical and petrous segments of right internal carotid artery are not visible. Faint opacification of upper cervical and petrous portions of left internal carotid artery (*arrow*). Image quality rated good.

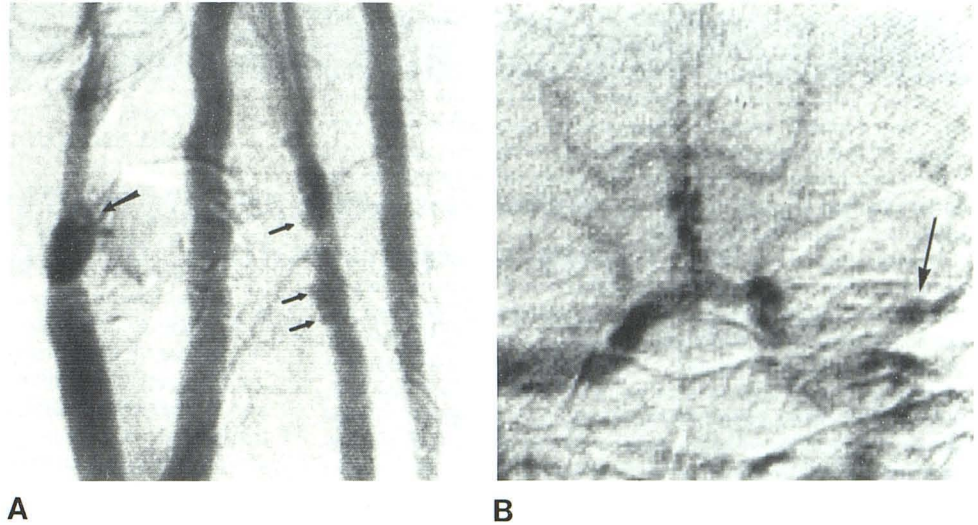
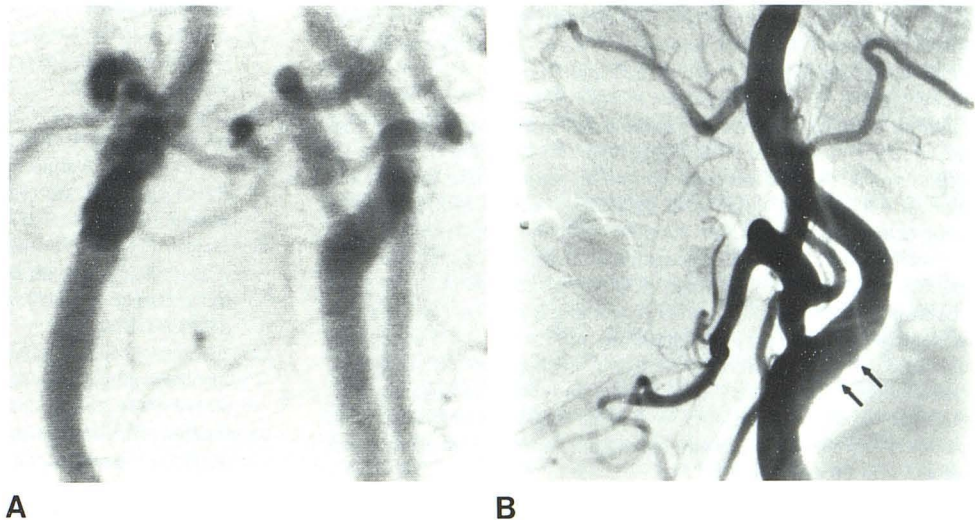


Fig. 4.—65-year-old woman evaluated for left hemispheric TIA. **A**, Cervical DSA with iohexol (right posterior oblique projection) shows no significant stenosis or irregularity of common or internal carotid arteries bilaterally. Image quality rated excellent. **B**, Conventional angiography (selective left common carotid arteriogram, lateral projection) demonstrates marginal irregularities along posterior aspect of distal left common carotid artery and proximal left internal carotid artery (*arrows*). These findings were not evident in **A** because less spatial resolution is attainable with intravenous DSA than with direct arteriography.



#### ECG, Blood Profiles, and Vital Signs

There were no clinically significant changes in postexamination ECGs, blood profiles, or vital signs as compared with baseline measurements.

#### Complications

Three complications were encountered, all in patients who had received iohexol for DSA. A 79-year-old man had an episode of angina pectoris which was promptly relieved by sublingual nitroglycerin. No significant ECG changes were noted in this patient. A 63-year-old man sustained moderate contrast extravasation around the superior vena cava, detected on fluoroscopy after two injections. He had complained of moderate chest heaviness during the second injection. This patient was observed for 3 hr, by which time he was asymptomatic, and experienced no further difficulty. A minimal amount of extravascular contrast material persisted in a chest radiograph obtained about 1 hr after the procedure. The third

patient developed pain in the right arm associated with cervical adenopathy 4 days after the examination. She was diagnosed as having phlebitis and treated conservatively. The clinical manifestations resolved within 2 weeks.

#### Discussion

The results of this study demonstrate that the nonionic water-soluble contrast medium iohexol is both safe and well tolerated for intravenous injection. The radiopacity of iohexol at 350 mg I/ml concentration is equal to that of Renografin-76 at 370 mg I/ml concentration. Our study suggests that the radiographic quality of DSA images with iohexol is slightly superior to that of similar images obtained with Renografin-76. We believe the difference is explained by the significantly lesser frequency of image degradation secondary to swallowing, motion, and coughing during and after injection with iohexol as compared with Renografin-76 (table 1).



Lasser and Lang [9] and Lieberman and Siegle [10] hypothesized that intolerance to and increasing toxicity of a contrast medium parallels a rise in its protein-binding capacity. Cogen et al. [11] observed increased histamine release after intravenous injection of iodinated contrast material, which may be associated with side effects. The attributes of low osmolality, low histamine release, and low plasma protein-binding capacity appear to be related to the better tolerance and lower toxicity reported for iohexol as compared with ionic contrast agents [1, 2].

Ingstrup and Hauge [8], in a randomized double-blind study comparing iohexol and Conray on injection into the common carotid and internal carotid arteries, reported no differences between the two contrast media in radiographic imaging quality, blood pressure, heart rate, or ECG parameters. They observed that sensations of warmth and pain were less pronounced with iohexol than with Conray in common carotid and internal carotid arteriography. These authors also compared iohexol with metrizamide on injection into the vertebral arteries; less warmth and pain or discomfort were noted with metrizamide as compared with iohexol in the vertebral artery injections.

Despite the advantages of economy and its relatively risk-free and less invasive nature, DSA has limitations when compared with conventional arteriography. Even when iohexol is used as the contrast medium, the quality of DSA images remains inferior to those obtained with direct arteriography because less spatial resolution is attainable with intravenous injection (fig. 4). The nonselective nature of intravenous DSA requires the use of more contrast material and therefore limits the number of projections obtainable per study, a factor that is particularly important in the detection of eccentrically situated vascular abnormalities including ulcerations. Inadvertent venous reflux and calcifications can reduce arterial opacification in subtracted images. Vascular superposition and occurrence of motion during contrast medium administration are the two major causes of image quality degradation in DSA. Stereoscopy and use of U-arm units [12] can aid in vascular isolation, and image reprocessing with alternate subtraction masks [12] and use of a head immobilizer [13] would minimize motion artifacts. Nevertheless, the availability of a safe and well tolerated contrast medium for DSA associated with less motion, swallowing, and patient discomfort constitutes a significant improvement in the quest for superior images.

## REFERENCES

1. Haavaldsen J. Iohexol. Introduction. *Acta Radiol [Suppl]* (Stockh) **1980**;362:9-11
2. Lindgren E. Iohexol. A non-ionic contrast medium: pharmacology and toxicology. *Acta Radiol [Suppl]* (Stockh) **1980**;362:131-134
3. Mutzel W, Seifert HM, Speck U. Biochemical-pharmacologic properties of iohexol. *Acta Radiol [Suppl]* (Stockh) **1980**;362:111-115
4. Chilcote WA, Modic MT, Pavlicek WA, et al. Digital subtraction of the carotid arteries: a comparative study in 100 patients. *Radiology* **1981**;139:287-295
5. Seeger JF, Weinstein PR, Carmody RF, Ovitt TW, Fisher HD III, Capp MP. Digital video subtraction angiography of the cervical and cerebral vasculature. *J Neurosurg* **1982**;56:173-179
6. Almen T. Angiography with metrizamide. Animal experiments and preliminary clinical experiences. *Acta Radiol [Suppl]* (Stockh) **1977**;355:419-430
7. Aakhus T, Sommerflet SC, Stormorken H, Dahlstrom K. Tolerance and excretion of iohexol after intravenous injection in healthy volunteers: preliminary report. *Acta Radiol [Suppl]* (Stockh) **1980**;362:131-134
8. Ingstrup HM, Hauge P. Clinical testing of iohexol, Conray meglumine and Amipaque in cerebral angiography. *Neuroradiology* **1982**;23:75-79
9. Lasser EC, Lang JW. Contrast-protein interactions. *Invest Radiol* **1970**;5:446-451
10. Lieberman P, Siegle RL. Complement activation following intravenous contrast material administration. *J Allergy Clin Immunol* **1979**;64:13-17
11. Cogen FC, Norman ME, Dunsky E, Hirshfeld J, Zweiman B. Histamine release and complement changes following injection of contrast media in humans. *J Allergy Clin Immunol* **1979**;64:299-302
12. Strother CM, Sackett JF, Crummy AB, et al. Intravenous video arteriography of the intracranial vasculature: early experience. *AJNR* **1981**;2:215-218
13. Seeger JF, Smith JRL, Carmody RF. A head immobilizer for digital video subtraction angiography. *AJNR* **1982**;3:352-353