



Get Clarity On Generics

Cost-Effective CT & MRI Contrast Agents



FRESENIUS
KABI

WATCH VIDEO

AJNR

Clinical comparison of metrizamide and iopamidol for myelography.

P A Turski, J F Sackett, L R Gentry, C M Strother and F Matozzi

AJNR Am J Neuroradiol 1983, 4 (3) 309-311

<http://www.ajnr.org/content/4/3/309>

This information is current as
of August 8, 2025.

Clinical Comparison of Metrizamide and Iopamidol for Myelography

Patrick A. Turski,¹ Joseph F. Sackett, Lindell R. Gentry, Charles M. Strother, and Francesco Matozzi

A double-blind parallel comparison of iopamidol and metrizamide for myelography was performed in 36 patients. Sixteen adverse reactions were noted in 10 patients who received metrizamide. Six adverse reactions were reported in five patients who received iopamidol. There was no appreciable difference in the radiographic opacification.

The development of nonionic water-soluble contrast media for myelography has resulted in improved anatomic delineation and better patient tolerance [1, 2]. Metrizamide was the first myelographic contrast medium that fulfilled the need for a contrast material of low neurotoxicity and sufficient radiopacity while being miscible with cerebrospinal fluid (CSF). Nevertheless, adverse reactions related to the toxicity of the contrast material occur after metrizamide myelography [2-6]. Consequently, a new contrast medium, iopamidol (Bracco, Milan, Italy; and Squibb, Princeton, NJ), has been developed in the hope of finding an even less toxic material. In this investigation iopamidol was compared with metrizamide to assess relative toxicity and radiographic opacification following intrathecal injection.

Materials and Methods

The study was performed as a double-blind parallel comparison in which each patient was randomly assigned either iopamidol or metrizamide. The contrast material was dispensed by a member of the neuroradiology service outside the myelographic room. The following conditions excluded patients from the study: under 18 years of age; women of childbearing potential not using an effective contraceptive; pregnancy; surgery required within 24 hr of the radiologic examination; hypersensitivity to any form of contrast agent; spinal puncture within the last month; frankly bloody CSF obtained after lumbar puncture; increased intracranial pressure or suspicion of intracranial tumor, abscess, or hematoma; treatment with phenothiazine derivatives, butyrophenones, tricyclic antidepressants, monoamine oxidase inhibitors, or analeptics within 1 week of the study; history of convulsive disorder or multiple sclerosis; history of psychosis; history of alcoholism or drug abuse. Thirty-six patients were studied, 18 with iopamidol and 18 with metrizamide. Eight cervical, six thoracic, 20 lumbar, and two complete myelograms were obtained, equally divided between iopamidol and metrizamide.

Clinical Observations

The patients were evaluated before myelography with history, physical examination, and neurologic examination by a member of the neurology department. Vital signs (pulse, respiratory rate, temperature, and supine blood pressure) were recorded before and at 15 min, 30 min, 1 hr, 4 hr, and 24 hr after the injection of the contrast material.

Laboratory Profiles

Hematologic survey, chemistry survey, and urinalysis were performed before myelography and at 24 and 72 hr after the procedure. CSF obtained during the myelogram was sent for cell count, total protein, glucose, and chloride.

The patients received a clear liquid breakfast before myelography and were not premedicated. Fluids were encouraged after myelography to insure adequate hydration.

The contrast material was administered through a 22 gauge needle, which was placed at the L2-L3 interspace for the lumbar and thoracic examinations. After lumbar puncture 3-5 ml of CSF was removed and 10-15 ml of 200 mg I/ml contrast material was introduced (metrizamide reconstituted with 13.2 ml of diluent). Cervical examinations were performed via a lateral C1-C2 puncture and 8-15 ml of contrast material (300 mg I/ml) was injected, depending on the volume of the cervical canal.

Following the procedure patients remained passive in bed with heads elevated 30° for 8 hr. Following this, the patients were allowed to have bathroom privileges and lie in the horizontal position.

Anteroposterior and oblique films were obtained with both horizontal and vertical beam techniques. The films were evaluated for technical quality and radiographic opacification by a neuroradiologist (J. F. S.), who did not know which contrast material had been administered. Films that were technically adequate were graded as: 0, no visualization or opacification; 1, poor visualization or faint opacification, inadequate for diagnosis; 2, adequate for visualization or sufficient opacification for diagnosis; or 3, superior visualization or opacification permitting diagnosis easily.

The patients underwent repeat neurologic examination and laboratory studies 24 hr after myelography. Adverse reactions were recorded including the time of onset, duration, and severity. Reactions were considered mild when they disappeared spontaneously without treatment. Moderate reactions were defined as those ne-

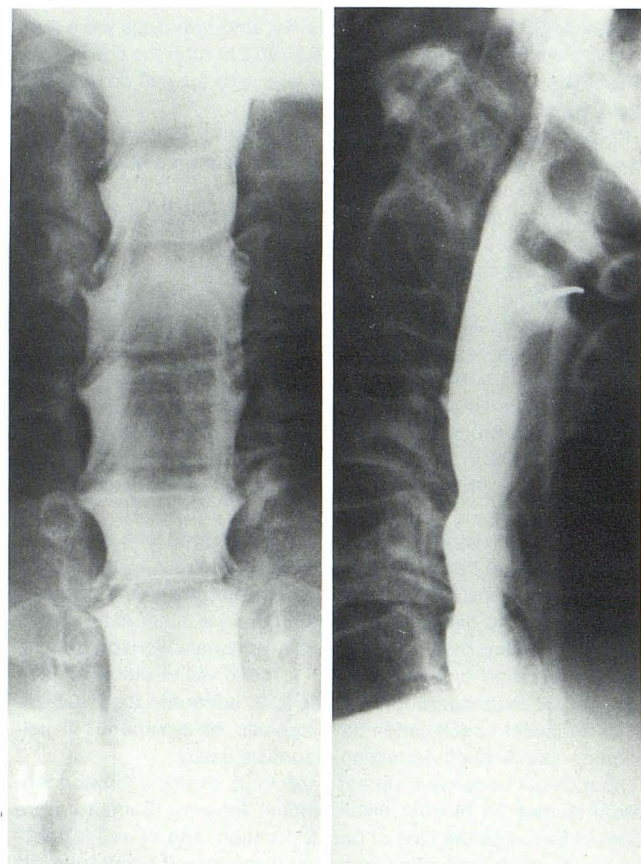
¹ All authors: Department of Radiology, University of Wisconsin, Clinical Science Center, 600 Highland Avenue, Madison, WI 53792. Address reprint requests to P. A. Turski.

cessitating treatment but responding immediately to such treatment. Severe reactions were defined as alarming or life-threatening reactions that responded poorly or slowly to treatment or did not respond to treatment.

TABLE 1: Adverse Reactions to Iopamidol and Metrizamide, by Location of Myelography

	No. Reactions after Metrizamide (after Iopamidol)			
	Cervical	Thoracic	Lumbar	Complete
Mild headache	1 (1)	1	5 (2)	0
Moderate headache*	1	0	1	0
Nausea	1	0	1	0
Vomiting	1	0	1	0
Radiculopathy	0	0	0 (1)	0
Stiff neck	0	0	0 (1)	0
Dizziness	0 (1)	0	0	1
Sleep disturbance	1	0	0	0
Backache	0	1	0	0
Total no. reactions	5 (2)	2	8 (4)	1
Total no. patients studied	4 (4)	3 (3)	10 (10)	1 (1)

* Required analgesics but responded quickly.



A

B

Fig. 1.—Cervical iopamidol myelogram via C1–C2 puncture (10 ml of 300 mg I/ml). Anteroposterior (A) and lateral (B) views clearly demonstrate cervical subarachnoid space. Ventral and left lateral extradural lesions at C3–C4 and C4–C5.

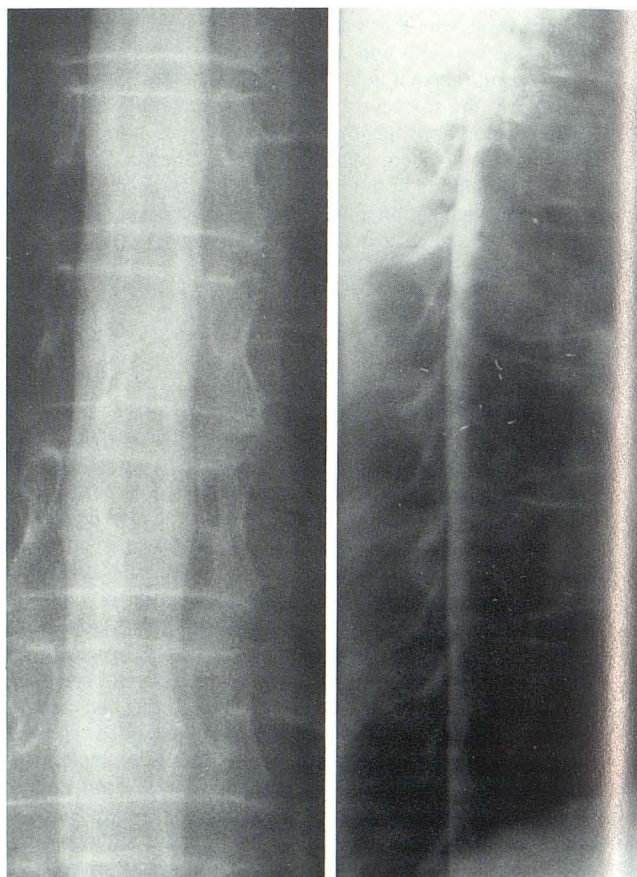
Results

The adverse reactions are summarized in table 1. The procedure was well tolerated by both groups. Sixteen adverse reactions were noted in 10 patients who received metrizamide. Six adverse reactions were reported in five patients who received iopamidol. There were no serious adverse reactions to either contrast material. Eight patients reported headache after metrizamide myelography; two of them required analgesics. Three patients reported headache after myelography with iopamidol; none of them required analgesics. The two groups could be statistically differentiated with $p < 0.1$.

The radiographic opacification was adequate for diagnosis in all patients. The opacity was considered superior in 10 patients who received iopamidol (figs. 1–3) and in nine patients who received metrizamide. There were no abnormalities of the laboratory investigations related to the contrast materials, and the vital signs did not fluctuate appreciably in relation to myelography.

Discussion

Iopamidol is a nonionic compound composed of a triiodinated benzene ring with three highly hydrophilic side chains (fig. 4). It has a molecular weight of 777 and an iodine content of 49%. At a concentration of 300 mg I/ml the osmolality is 0.616 mol/kg and the viscosity at 37°C is 4.5.



A

B

Fig. 2.—Normal thoracic iopamidol myelogram after examination of lumbar region (15 ml of 200 mg I/ml). Anteroposterior (A) and lateral (B) views.

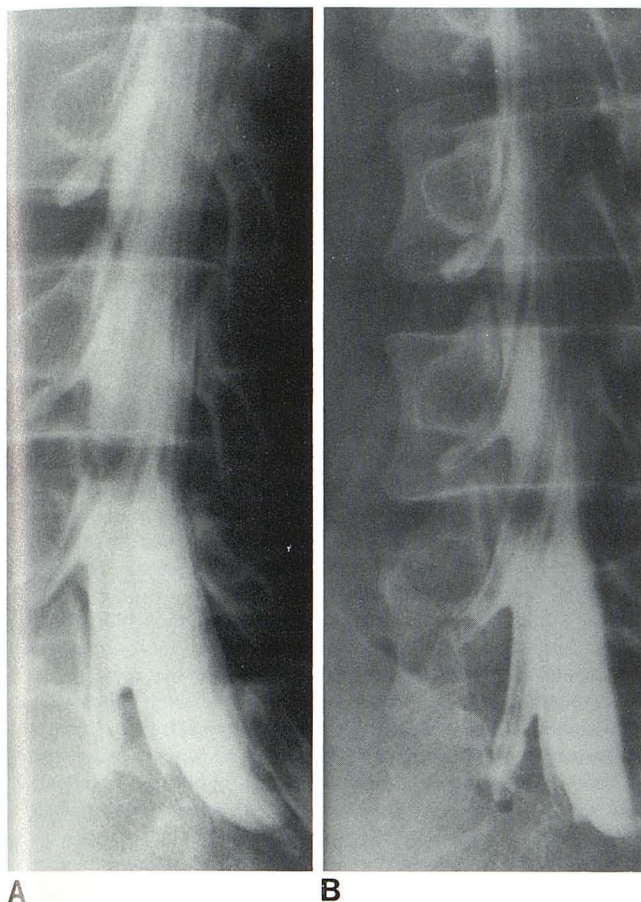


Fig. 3.—Comparison of iopamidol and metrizamide myelograms. **A**, Lumbar iopamidol myelogram (oblique view with horizontal beam) reveals excellent detail of nerve root sheaths. **B**, Previous metrizamide myelogram in same patient.

	 Metrizamide	 Iopamidol
Molecular Weight	789.1	777.09
Iodine Content	48.2%	49%
Viscosity 37° (300 mg 1/ml)	6.24	4.5
Osmolality mol/kg (300 mg 1/ml)	0.45	0.516

Fig. 4.—Chemical properties of metrizamide and iopamidol.

In a double-blind study of 200 patients undergoing lumbar myelography, Hammer and Lackner [7] did not detect any difference in the incidence or severity of adverse reactions between iopamidol and metrizamide. However, Drayer et al. [8] noted that the striking features of the 12 patients in their series (lumbar iopamidol myelography) were the mildness of the reactions and the excellent patient tolerance of the procedures. Similarly, Belloni et al. [9] considered

the most significant aspect of their study with iopamidol for cervical myelography in 65 patients to be the complete absence of neurologic symptoms other than headache.

In our limited experience adverse reactions occurred less often in the group of patients who received iopamidol. The side effects associated with iopamidol were generally mild and of shorter duration than those of the metrizamide group. Of particular note, there were no alterations in consciousness or seizure activity in any of the patients receiving iopamidol.

The potential of iopamidol for producing arachnoiditis has been investigated in macaque monkeys. The preliminary results indicate iopamidol is equivalent to metrizamide with respect to the risk of arachnoiditis [10].

Iopamidol is absorbed from the subarachnoid space slightly faster than metrizamide [7]. It enters the intracranial subarachnoid spaces following the normal pathways of CSF resorption. Electroencephalography after lumbar myelography revealed three or four bursts of diffuse intermittent delta activity with no epileptiform spiking [8]. The exact epileptogenic potential of iopamidol has not been clearly defined in man.

In this investigation only 18 patients were studied with each contrast material and it is therefore not possible to draw any firm conclusions regarding the relative toxicity. However, iopamidol produced fewer adverse reactions than metrizamide and those that were encountered were mild in nature. Iopamidol has the additional advantages of being stable in solution and having a long shelf life.

REFERENCES

1. Keiffer SA, Binet EF, Esquerre JV, Hantman RP, Gross CE. Contrast agents for myelography: clinical and radiologic evaluation of Amipaque and Pantopaque. *Radiology* 1978;129:695-705
2. Sackett JF, Strother CM, Quaglieri CE, Manucher JJ, Levin AB, Duff TA. Metrizamide—CSF contrast medium: analysis of clinical application in 215 patients. *Radiology* 1977;123:779-782
3. Skälpe IO. Adverse effects of water-soluble contrast media in myelography, cisternography, and ventriculography. *Acta Radiol [Suppl]* (Stockh) 1977;355:409-416
4. Gelmers HJ. Adverse side effects of metrizamide in myelography. *Neuroradiology* 1979;18:119-123
5. Schmidt RC. Mental disorders after myelography with metrizamide and other water-soluble contrast media. *Neuroradiology* 1980;19:153-157
6. Bertoni JM, Schwartzman RJ, Van Horn G, Partin J. Asterixis and encephalopathy following metrizamide myelography: investigations into possible mechanisms and review of literature. *Ann Neurol* 1981;9:366-370
7. Hammer B, Lackner W. Iopamidol, a new non-ionic hydrosoluble contrast medium for neuroradiology. *Neuroradiology* 1980;19:119-121
8. Drayer B, Suslavich F, Luther J, et al. Clinical trial of iopamidol for lumbosacral myelography. *AJNR* 1982;3:59-64
9. Belloni G, Bonaldi G, Moschini L, Quilici N. Cervical myelography with iopamidol. *Neuroradiology* 1981;21:97-99
10. Haughton VM, Ho KC. Arachnoiditis from myelography with iopamidol, metrizamide, and iocarmate compared in the animal model. *Invest Radiol* 1980;15:S267-S269