



Get Clarity On Generics

Cost-Effective CT & MRI Contrast Agents



FRESENIUS
KABI

WATCH VIDEO

AJNR

Radiologic investigation of craniopagus twins (partial type).

P Stanley, F M Anderson and H D Segall

AJNR Am J Neuroradiol 1983, 4 (2) 206-208

<http://www.ajnr.org/content/4/2/206.citation>

This information is current as
of August 7, 2025.

Radiologic Investigation of Craniopagus Twins (Partial Type)

Philip Stanley,¹ Frank M. Anderson,² Hervey D. Segall¹

Conjoined twins are uncommon, occurring in about 1:50,000 live births [1]. The most common form is thoracopagus with the junction in the region of the sternum, and the rarest is craniopagus where the two skulls are joined. The latter occurs once in about 2.5 million births [2].

In most cases of craniopagus twins, surgical separation is attempted. Radiologic methods may be used in evaluating the site of contact between the two heads and the relation of one brain to the other. Vascular anatomy and continuity at the junction may also be assessed. The information derived from these examinations is helpful in planning the details of surgical separation if operation is thought feasible. We describe the radiologic investigation of one pair of partial type craniopagus twins with survival of one twin after surgery.

Case Report

Craniopagus twins which had been delivered by cesarean section were transferred to Childrens Hospital of Los Angeles on the second day of life. Twins (but not the conjunction) had been diagnosed prenatally with the mother, a 31-year-old gravida 3, para 3, being large for dates. Together the twin girls weighed 5,108 g at birth. The junction was between the occipital region of twin A and the parietooccipital region of twin B. Twin B had extensive facial deformities with bilateral harelip and cleft palate, a bifid nose, and widely separated eyes with a right microphthalmia and a coloboma involving the iris. A soft-tissue mass superior to the right eye was present, which was later found to be a pinched-off encephalocele (fig. 1). No other abnormalities were seen in twin B. Twin A had dextroposition of the heart but no other extracranial abnormality.

Each twin had her own individual motor and autonomic functions, and hematologic and biochemical values were the same for both children. Tilting the children caused pallor in the uppermost twin and congestion in the other. After discussion with the parents, radiologic investigations were undertaken to determine the feasibility of surgical separation.

Skull Radiography

A single vertical radiograph on the second day of life with the children supine demonstrated some flattening of the vault at the

junction between the occipital region of twin A and the parietal region of twin B (fig. 2). It could not be assessed whether there was complete bony separation of the two cranial vaults at the level of the junction because no second projection was taken.

Nodular and curvilinear calcification was noted in the midline of the cranium of twin B. Absence of the hard palate was seen in twin B along with cervical vertebral anomalies.

Cranial Computed Tomography (CT)

Routine tomographic films were obtained on an EMI Mark I machine with the children facing upward. Pre- and postenhancement scans were obtained, with both twins being injected.

The initial sections revealed a bony defect between the two cranial vaults as well as a central lucent structure in the anterior midline of twin B (fig. 3A). (At postmortem, this was found to be a tubular collection of fat lying immediately above the corpus callosum.) A more superior section revealed two areas of calcification in the midline intimately related to the corpus callosum in twin B. No ventricular system was identified in twin B; the bodies of the lateral ventricles were seen in twin A and appeared normal. Postenhancement studies demonstrated the superior sagittal sinuses, which did not appear to communicate (fig. 3B). The lateral sinuses were not visualized.

Cerebral Angiography

The twins were unstable during all the investigations, particularly arteriography. There was a tendency to develop hypotension, hypothermia, and apnea.

On the second day of life, an arch aortogram and left carotid arteriogram were obtained on twin A via an umbilical artery cut-down. On day 24, a right carotid arteriogram was obtained on twin B via a percutaneous femoral artery approach, and, on day 29, bilateral carotid and left vertebral arteriograms were undertaken on twin A. On day 35, a superior sagittal sinogram was attempted on twin A.

Bilateral carotid arteriography on twin A demonstrated no arterial crossover. Left carotid injection showed indentation of the left occipital pole seen in the arterial capillary and venous phases. There was inward displacement of the superior sagittal sinus and the left lateral sinus by the herniating brain from twin B (fig. 4). There was no filling of the venous system of the other twin. The left

Received April 15, 1982; accepted after revision August 18, 1982.

¹ Department of Radiology, Childrens Hospital of Los Angeles, P.O. Box 54700, Los Angeles, CA 90054. Address reprint requests to P. Stanley.

² Division of Neurosurgery, Childrens Hospital of Los Angeles, Los Angeles, CA 90054.

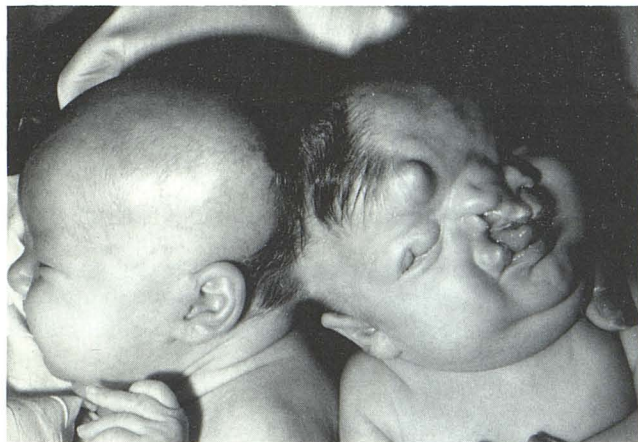

Fig. 1.—Frontal view shows site of conjunction and angulation of twin heads. Facial deformities of twin B and right eye abnormalities are well seen.

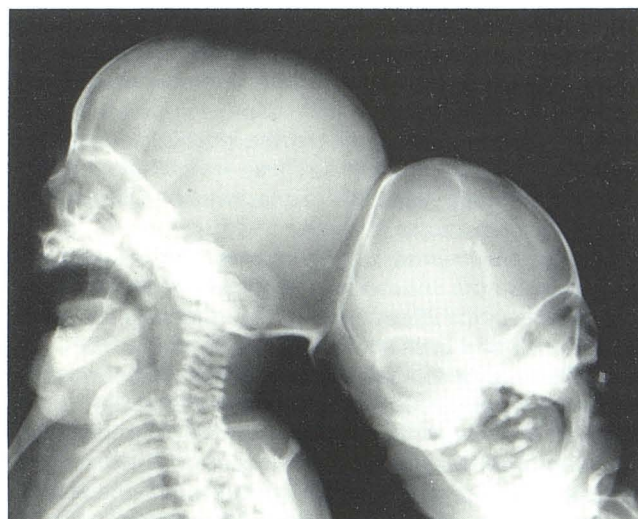

Fig. 2.—Vertical projection demonstrates conjunction of two cranial vaults. Calcification aligned with falx cerebri in twin B; hard palate and upper cervical spine anomalies are present.

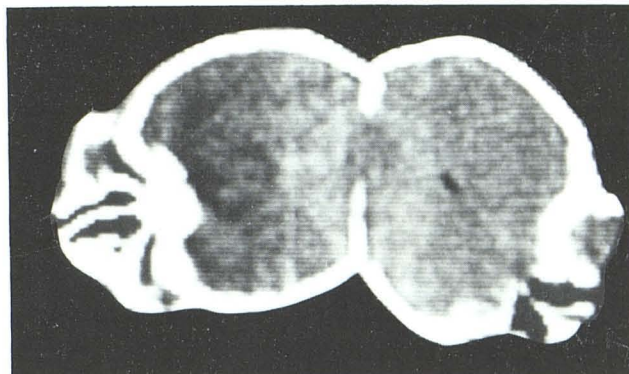
vertebral injection showed similar inward displacement of brain and venous sinuses.

Right carotid arteriography in twin B demonstrated ingress of the parietooccipital region across the skull defect into the cranial cavity of twin A (fig. 5A). The venous phase showed veins draining centrally to a normal venous system with no drainage into twin A (fig. 5B). The superior sagittal sinus was well seen and did not communicate with the other twin.

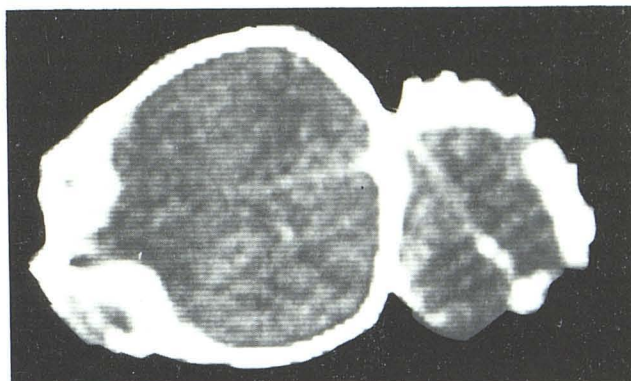
To obtain further information regarding the venous anatomy, a superior sagittal sinogram was attempted on twin A via an anterior fontanelle puncture, but satisfactory flow was not obtained.

Surgery

Operation to separate the twins was carried out when they were 6 weeks of age. A scalp flap was reflected and bone was removed from the skull of twin B, including the dense line of skull fusion. This exposed the 3 × 7 cm defect between skulls where the occipital lobe of twin B protruded into the other cranial space indenting the dura and great sinuses. These dural layers were



A



B

Fig. 3.—A, Preenhancement CT scan demonstrates attitude of skulls to each other and bony defect. Midline lucency within brain of twin B immediately superior to the corpus callosum. B, Enhancement scans at this and other levels showed no apparent junction of two superior sagittal sinuses. Calcification aligned with falx is in twin B.

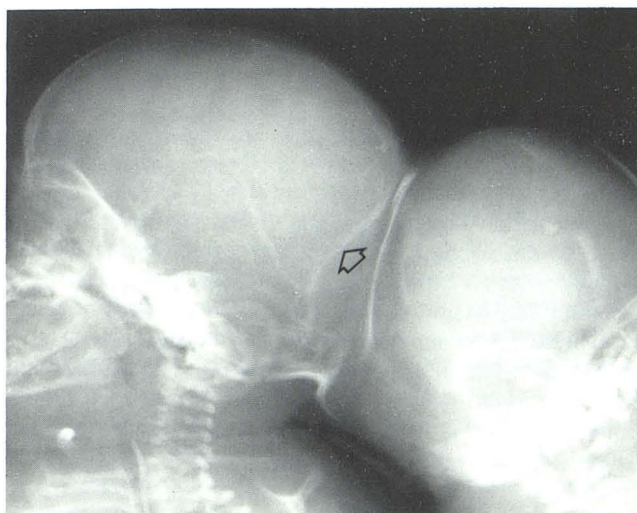


Fig. 4.—Venous phase of left carotid artery injection in twin A. Inward displacement of superior sagittal sinus (arrows) and left transverse sinus.

densely adherent to one another in this region. Five or six irregular short veins were found to bridge between the lateral sinus of twin B and dura overlying the torcular of twin A. However, the major venous sinuses showed no direct communication. Additional bone was taken off along the attachment, disconnecting the skulls; this

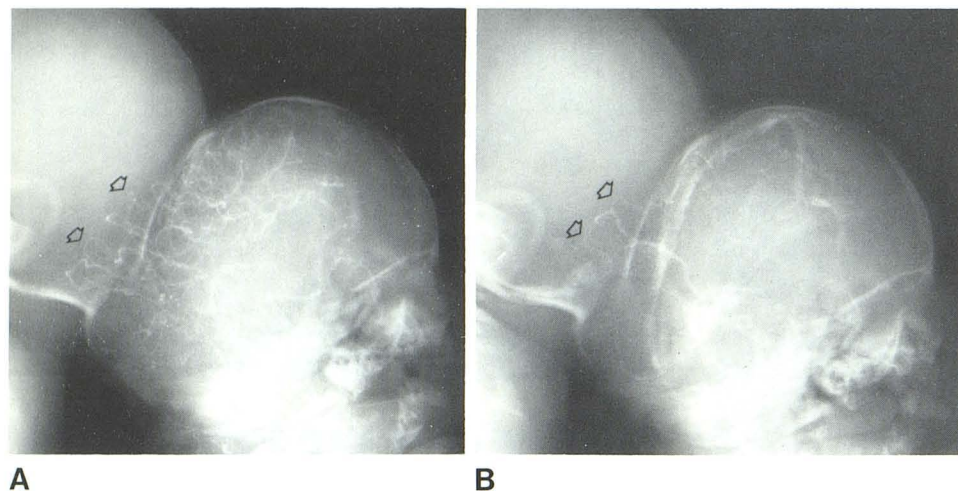


Fig. 5.—Right carotid injection of twin B. A, Late arterial phase with cortical arteries indicate ingress of brain tissue into cranial cavity of twin A. B, Venous phase. Central drainage with no crossover into twin A. Edge of herniated brain (arrows).

provided improved access to these veins which were then divided. Fused dura was left intact in twin A and partially resected from the occipital pole of twin B. The separation was then complete. The scalp flap was closed over twin A's skull defect and the other child's wound was protected with a heavy sterile dressing preparatory to later grafting.

Postoperative course in the first twin was excellent; she showed no neurologic defects and progressed well. Twin B had only a slight left hemiparesis and no other new problems until the fourth day when sepsis developed, and she did not respond to appropriate antibiotics. This patient died on postoperative day 8. Twin A is now 6 years old. She has remained well, is above average in intelligence, and her physical development is normal. New bone growth has filled in about half of the skull defect and this area feels quite secure, but cranioplasty may be advisable in the future.

Discussion

O'Connell [2] broadly classified craniopagus twins into partial and total. In the partial form, the area of contact between the two skulls is small and there may be a bony septum separating the two brains. If not separated by bone, there is usually dura between the two brains and each brain has its own leptomeninges. Rarely there may be a defect within the dura. There is usually no cross circulation in this variety of craniopagus twins. In the total form, there is extensive contact between the two skulls. There is either arachnoid only separating the two brains or there may be actual brain continuity in a common cranium [2].

With craniopagus, the embryologic defect appears to be reasonably clear. The conjunction occurs as a result of incomplete fission of a single developing embryo and not as a result of fusion of two separate embryos. This defect occurs at about the end of the second week of development [3] before the ectomeninx, which gives rise to the dura and skull, has developed. With total craniopagus, there is no dura separating the two brains. The absence of the dura mater means that the superior sagittal sinus cannot develop [2]. Venous drainage is often into a communal circumferential vein lying in a thin shelf of dura at the junction of the two twins. This single vein has in the past proved essential for the survival of both twins and thus limited surgical

success [2, 4]. In our case, the dura was partly fused in the area of skull attachment, and there were some small anastomotic veins extending between the lateral sinuses close to the confluence, but without a communal venous sinus. In addition, herniation of the occipitoparietal lobe of twin B through the skull defect caused some indentation and compression of the brain of twin A. These features are unusual for partial craniopagus, a defect described by O'Connell as essentially an extracranial abnormality [2].

The object of therapy with craniopagus twins is surgical separation. Before this can be contemplated, demonstration of certain aspects of cranial and intracranial anatomy is essential. CT and plain skull radiographs are mandatory to demonstrate bony and soft-tissue attachments between the skulls and cerebral hemispheres and angiography is very important to show all details of the complex vascular anatomy. Good contrast studies of the venous circulation of both twins must be obtained [5]. While the venous phase of an arterial injection may be sufficient, to obtain better definition it may be necessary to either directly puncture the anterior fontanelle or perform a retrograde injection by catheterization of an internal jugular vein [6]. In our case, there did not appear to be major venous sinus sharing on angiography and this was confirmed at surgery.

REFERENCES

1. Potter EL. *Pathology of the fetus and infant*, 2d ed. Chicago: Year Book Medical, 1961
2. O'Connell JEA. Craniopagus twins: surgical anatomy and embryology and their implications. *J Neurol Neurosurg Psychiatry* 1976;39:1-22
3. Benirschke K, Kim CK. Multiple pregnancy. *N Engl J Med* 1973;288:1276-1284, 1329-1336
4. Grossman HJ, Sugar O, Greeley PW, Sadove MS. Surgical separation in craniopagus. *JAMA* 1953;153:201-207
5. du Boulay GH. Radiological examination of two pairs of craniopagus twins. *Br Med J* 1964;1:1337-1339
6. Wolpert SM. Vascular studies of congenital anomalies. In: Newton TW, Potts DG, eds. *Radiology of the skull and brain*. St. Louis: Mosby, 1974:2752-2753