



Get Clarity On Generics

Cost-Effective CT & MRI Contrast Agents

**FRESENIUS
KABI**

WATCH VIDEO

AJNR

**Diazepam Prophylaxis of Contrast
Media-Induced Seizures during Computed
Tomography of Patients with Brain Metastases**

John J. Pagani, L. Anne Hayman, Robert H. Bigelow, Herman I.
Libshitz, Ronald A. Lepke and Sidney Wallace

This information is current as
of August 23, 2025.

AJNR Am J Neuroradiol 1983, 4 (1) 67-72
<http://www.ajnr.org/content/4/1/67>

Diazepam Prophylaxis of Contrast Media-Induced Seizures during Computed Tomography of Patients with Brain Metastases

John J. Pagani^{1, 2}
 L. Anne Hayman³
 Robert H. Bigelow⁴
 Herman I. Libshitz¹
 Ronald A. Lepke¹
 Sidney Wallace¹

The effect of 5 mg of intravenous diazepam (Valium) on contrast media-associated seizure incidence was studied in a randomized controlled trial involving 284 patients with known or suspected brain metastases undergoing cerebral computed tomography. Of these patients, 188 were found to have brain metastases, and it is estimated that for this subgroup prophylactic diazepam reduces the risk of contrast-associated seizure by a factor of 0.26. Seizures occurred in three of 96 patients with metastases on diazepam and in 14 of 92 patients with metastases but without diazepam. Factors related to increased risk of contrast media-associated seizures are: (1) prior seizure history due to brain metastases and/or prior contrast, (2) progressive cerebral metastases, and (3) prior or concurrent brain antineoplastic therapy. Factors not related to an increased risk of these seizures are: (1) contrast media dosage, chemical composition, or osmolality, (2) computed tomographic appearance of metastases, and (3) type of primary malignancy. Concomitant therapeutic levels of diphenylhydantoin (Dilantin) do not protect completely against contrast media-associated seizures. Pathophysiology of contrast media-associated seizures is discussed in view of the risk factors determined by this study.

Seizures in the general population after intravenous contrast media administration are rare, occurring in about 0.01% of patients [1]. However, their incidence is reported as 6%–19% in patients with brain metastases undergoing contrast cerebral computed tomography (CT) [2, 3]. We undertook a prospective, randomized study to identify risk factors in these patients and assess the value of the prophylactic use of diazepam before intravenous contrast media administration during cerebral CT in an attempt to assess its effect on seizure incidence in this patient population.

Subjects and Methods

A total of 284 consecutive patients with known or suspected brain metastases underwent contrast cerebral CT. They were randomized with every other patient receiving 5 mg of diazepam (Valium, Roche) immediately before contrast injection: 142 patients (diazepam group) received diazepam while 142 patients (nondiazepam group) did not. Diazepam was administered as a slow intravenous injection over at least 1 min and followed immediately by the contrast media. In 26 patients, CT was performed immediately after receiving 300 ml (40 g iodine) of meglumine diatrizoate by a slow drip infusion technique. In 258 patients, a 1 hr delayed CT scan was obtained after receiving 600 ml (80 g iodine) of 30% meglumine diatrizoate (Reno-M-Dip, Squibb) as an immediate 300 ml bolus given over 4–9 min and followed by a 300 ml drip infusion during the next 10–15 min [4]. When a patient developed a seizure, the administration of contrast media was stopped immediately and treated appropriately. A seizure was defined as paroxysmal, uncontrolled motor activity, which was either focal or generalized and followed by an alteration of consciousness [5].

This article appears in the January/February 1983 issue of *AJNR* and the April 1983 issue of *AJR*.

Received February 5, 1982; accepted after revision August 3, 1982.

¹Department of Diagnostic Radiology, University of Texas System Cancer Center, M. D. Anderson Hospital and Tumor Institute, Houston TX 77030.

²Present address: Department of Radiology, Beth Israel Hospital, 330 Brookline Ave., Boston, MA 02215. Address reprint requests to J. J. Pagani.

³Department of Radiology, Baylor College of Medicine, U.S. V.A. Medical Center Hospital, and University of Texas Medical School, Houston, TX 77030. Present address: Massachusetts General Hospital, Boston, MA 02114.

⁴Department of Neurology, University of Texas Medical School, Houston, TX 77030.

AJNR 4:67–72, January/February 1983

0195–6108/83/0401–0067 \$00.00

© American Roentgen Ray Society

TABLE 1: Underlying Primary Malignancies in Patients with Known or Suspected Brain Metastases by CT out of Total Number of Patients with Tumor

Primary Malignancy	No. Patients with Metastases/Total (%)			
	Diazepam Group		Nondiazepam Group	
Breast	37/53	(70)	38/53	(72)
Lung	28/38	(74)	26/41	(63)
Melanoma	15/24	(63)	18/20	(90)
Testis	5/9	(56)	3/3	(100)
Renal cell	3/4	(75)	2/4	(50)
Leukemia	1/5	(20)	0/14	
Other	7/9	(78)	5/7	(71)
Total	96/142	(68)	92/142	(65)

Note.—“Other” includes lymphomas (eight patients), sarcomas (two), and carcinomas of the stomach, colon, esophagus, bladder, and head and neck region (six).

TABLE 2: Diazepam Administration and Brain Metastases Related to CT-Associated Seizures

Group: Presence of Metastases	No. Patients		
	Seizure	No Seizure	Totals
Diazepam:			
Present	3	93	96
Absent	0	46	46
Nondiazepam:			
Present	14	78	92
Absent	0	50	50

The patient's medical records and CT scans were analyzed to determine: (1) primary malignancy; (2) number, type, and duration of prior seizures and anticonvulsant therapy at the time of the CT scan; (3) prior or concurrent central nervous system (CNS) therapy; (4) presence, site, activity, and number of brain metastases; and (5) contrast media dosage and administration technique. Particular attention was paid to the clinical and CT features of the patients who developed seizures after contrast media administration. The exact amount of the contrast media administered and the time of development of the seizures after the start of contrast media infusion were noted.

The patients in the study population were 14–78 years old; there were 121 males and 163 females. Underlying primary malignancies and their frequencies are listed in table 1.

Results

Ninety-six of the 142 patients in the diazepam group and 92 of the 142 patients in the nondiazepam group had brain metastases identified on CT. The other patients in each group had no relevant abnormalities detected on CT. Three (3%) of the 96 patients with brain metastases on CT in the diazepam group and 14 (15%) of the 92 patients with brain metastases on CT in the nondiazepam group developed focal or grand mal seizures after contrast media administration (table 2). Seizures did not occur in the other 46 patients

in the diazepam group nor in the other 50 patients in the nondiazepam group without metastases. The association of seizure incidence with each of the following factors was studied:

Type of Primary Malignancy Producing Cerebral Metastases in Patients with Seizures

No significant difference was observed among the primary malignancy types with respect to the incidence of contrast-associated seizure in either group ($\chi^2 = 0.69$, 1 df, $p > 0.4$ in the diazepam group; $\chi^2 = 2.12$, 3 df, $p > 0.3$ in the nondiazepam group).

Number, Type, and Duration of Prior Seizures and Anticonvulsant Therapy

The three patients in the diazepam group with brain metastases who developed seizures after contrast media had a previous history of seizures caused by metastatic disease. These seizures occurred from 1 day to 7 months before contrast CT. Two of these three patients had therapeutic blood levels of diphenylhydantoin (Dilantin, Parke-Davis) at the time of CT, while one had subtherapeutic levels. Of the other 93 patients with brain metastases in the diazepam group who did not seize with contrast, 13 had a prior seizure history caused by their metastases disease that had been diagnosed on prior CT or radionuclide brain scans from 1 day to 11 months previously. Eight of these 13 patients had therapeutic blood levels of diphenylhydantoin while five were receiving no anticonvulsant therapy at the time of CT.

Of the 14 patients with brain metastases who did not receive diazepam but who developed seizures at the time of CT, 10 had a prior seizure and four had their first seizures at the time of the contrast CT. The seizure history in the 10 patients ranged from 1 day to 3.5 months prior to CT. Eight of these 10 patients had therapeutic blood levels of diphenylhydantoin while two did not. A seizure history due to metastatic disease was present in 21 of the other 78 patients in the nondiazepam group with brain metastases who did not seize at the time of CT. Seizures were noted in this group from 2 days to 6 months before CT. Therapeutic anticonvulsant blood levels were present at the time of CT in all 21 of these patients.

Eighty of the 284 patients had prior contrast cerebral CT scans from 1 week to 11 months preceding entry into the present study. Five of the 80 patients developed seizures at the time of their previous contrast CT. Two of the five were randomized to the diazepam group and three to the nondiazepam group during the present study. They all developed seizures at the time of CT during the present study irrespective of their diazepam group randomization. Of the three patients in the nondiazepam group who seized before and after entry into the present study, one had a grand mal seizure at the time of both CT scans. The other two patients had focal seizures during both CT studies. All three patients had CT evidence of progressive cerebral metastatic disease. The two patients in the diazepam group who seized at the

previous and present CT scans had grand mal seizures in both instances. The seizures after diazepam were of subjectively lesser clinical severity (shorter duration and lesser magnitude of motor activity) than at the time of the previous scan.

Prior or Concurrent CNS Therapy

Two of the three patients in the diazepam group with brain metastases and seizures had prior total brain irradiation (2,000–3,600 rad [20–30 Gy] in 10–18 fractions) 2–7 months before CT. One of these two patients was also receiving intrathecal methotrexate and cytosine arabinoside for treatment of CNS leukemia at the time of CT. The third patient had received no prior CNS therapy. Of the other 93 patients in the diazepam group with brain metastases and without seizures at the time of CT, 24 had a history of brain metastases. Of these 24 patients, 13 had received 2,000–4,600 rad (20–46 Gy) in 10–28 fractions from 1 to 8 months before CT. Eleven of these 24 patients had ongoing CNS radiotherapy at the time of CT.

Of the 14 patients in the nondiazepam group with brain metastases and seizures at the time of CT, eight had prior total brain irradiation (1,800 to 2,400 rad [18–24 Gy] in 8–12 fractions) 1.0–3.5 months before CT. The other six patients in this group had no prior brain irradiation. None of the 14 patients had intrathecal chemotherapy. Of the remaining 78 patients in the nondiazepam group with brain metastases and without seizures at the time of CT, 21 had a history of brain metastases and were treated (2,000–4,600 rad [20–46 Gy] in 10–32 fractions) 1–10 months before CT. None of the 46 patients in the diazepam group and none of the 50 patients in the nondiazepam group without brain metastases on CT had prior brain metastases or radiotherapy.

Presence, Site, Activity, and Number of Brain Metastases on CT

The CT appearance in the patients with brain metastases were identical in the diazepam and nondiazepam groups. The abnormalities consisted of single or multiple regions of increased attenuation with surrounding edema in the cerebral and/or cerebellar hemispheres after contrast media administration. There were no characteristic CT abnormalities in the patients who developed contrast media-associated seizures to distinguish them from patients who did not seize. Metastases were seen in all but one patient who seized. This latter patient received diazepam and developed status epilepticus 1 hr after contrast media injection. CT was not performed. An autopsy 48 hr after contrast injection demonstrated a focal cerebellar meningeal metastasis from breast carcinoma. There were no brain parenchymal metastases identified.

Table 3 relates the status of the brain metastases to the presence or absence of contrast-associated seizures for the diazepam and nondiazepam groups. All seizures in both groups occurred in patients with either newly diagnosed metastases or in patients with progression in number or size

TABLE 3: CT Status of Metastatic Activity in Diazepam and Nondiazepam Groups and its Relation to Contrast-Associated Seizures

Group: Presence of Seizures	No. Patients by Status of Metastases			
	New Diagnosis	Progression	Response to Treatment	Totals
Diazepam:				
Absent	69	7	17	93
Present	1	2	0	3
Nondiazepam:				
Absent	57	5	16	78
Present	6	8	0	14

TABLE 4: Amount of Contrast Material Given Relative to Presence of Seizure

Iodine (g)	No. Patients with Seizure	
	Diazepam Group	Nondiazepam Group
≤20	1	5
21–40	1	6
41–60	0	1
61–80	1	1
Totals	3	13*

* Excludes one patient to whom an unknown amount of contrast material was administered prior to development of seizure activity.

of CNS metastases during therapy. Seizures did not occur in patients demonstrating a response (as determined by serial CT scans) to CNS antineoplastic therapy.

Contrast Media Dosage and Administration Technique

Of the 284 patients under study, 258 received the high 80 g iodine dose and 26 received the 40 g iodine dose. Table 4 shows the grams of iodine administered by the time of onset of seizure activity in 16 of the 17 patients with seizures. Thirteen patients seized with 40 g or less of iodine and three seized after receiving 41 to 80 g of iodine. Of the 258 patients who received the 80 g iodine dose, 173 had brain metastases. Of these 173, 91 were in the diazepam group and 82 were in the nondiazepam group. Three of the 91 patients in the diazepam group and 12 of the 82 patients in the nondiazepam group developed contrast-induced seizures. Of the 26 patients who received the 40 g iodine dose, 15 had brain metastases. Five of these 15 patients were in the diazepam group and 10 were in the nondiazepam group. Two of the latter 10 patients developed contrast-induced seizures.

Contrast-associated seizures were successfully treated with varying amounts of intravenous diazepam in all but the one patient previously described with a cerebellar meningeal metastasis at autopsy who died in status epilepticus. No serious adverse side effects were produced by the diazepam administration.

Analysis of our data demonstrated that factors that had a statistically significant effect on the incidence of contrast

TABLE 5: Findings Relative to the Presence or Absence of Diazepam, Brain Metastases, Seizure, and CNS Therapy

Diazepam, CNS Therapy	No. Patients with Seizures/No. in Group	
	+ Seizure History	- Seizure History
Diazepam yes, therapy yes:		
+ Metastases	2/15	0/11
- Metastases	0/0	0/0
Diazepam yes, therapy no:		
+ Metastases	1/1	0/69
- Metastases	0/1	0/45
Diazepam no, therapy yes:		
+ Metastases	8/29	0/0
- Metastases	0/0	0/0
Diazepam no, therapy no:		
+ Metastases	2/2	4/61
- Metastases	0/0	0/50

Note. — + = present; — = absent.

media-associated seizure were: prior seizure history, prior or concurrent CNS antineoplastic therapy, the presence of brain metastases, and the intravenous administration of 5 mg of diazepam. Table 5 lists a series of contingencies showing the distribution of study patients categorized by the above factors. In the group without metastases, five out of eight possible entries were empty and no contrast media-associated seizures were noted among the 96 patients without brain metastases in both the diazepam and nondiazepam groups. For these reasons, evaluation of the effect of diazepam within the group without metastases was not possible and the analysis was limited to the group with brain metastases.

The randomization used failed to obtain comparable groups in the category positive for both seizure history and prior or concurrent CNS therapy. The diazepam group had 15 such patients while the nondiazepam group had 29. To adjust for this difference, logit analysis [6, 7] with seizure as the outcome was used to identify models which best "fit" table 5 (restricted to the group with metastases). The best fitting logit model included seizure history, diazepam, and CNS therapy (likelihood ratio goodness of fit $\chi^2 = 2.39$, 2 df), while removal of any of these factors from the model resulted in a significantly poorer fit (SH: $p < 0.0005$; RX: $p = 0.01$; D: $0.01 \leq p \leq 0.025$). Examination of table 5 shows that for this group of patients the administration of diazepam tended to reduce the risk of contrast media-associated seizures, while seizure history or previous or concurrent CNS therapy tended to increase this risk.

Using the Mantel-Haenszel method [8] of estimating the odds ratio (approximate relative risk) by looking at table 2 as four separate 2×2 contingency tables, we estimate the odds ratio to be 3.9. Thus the risk of contrast media-associated seizure was about 3.9 times greater in the nondiazepam group than in the diazepam group.

Using the logit analysis described previously, the status of metastases (table 3) was found to be significantly associated with the risk of seizure ($\chi^2 = 28.17$, 3 df, $p < 0.0005$). The patients with progression of CNS metastatic disease during CNS antineoplastic therapy had a much higher risk of contrast-associated seizure than either pa-

tients with newly diagnosed metastases or patients showing a response to therapy.

Discussion

The reported incidence of contrast media-associated seizures during cerebral CT in patients with brain metastases is 6%–19% [2, 3]. In our series, seizures occurred in 15% of patients who did not receive prophylactic, precontrast diazepam. The administration of a 5 mg intravenous bolus of diazepam immediately before contrast media injection decreased this seizure incidence to 3%. Indeed, the relative risk of developing a contrast media-associated seizure was about 3.9 times greater in the nondiazepam than in the diazepam group. Previous seizure history and either prior or concurrent CNS antineoplastic therapy had a statistically significant effect in increasing the risk of contrast media-associated seizures. The risk of developing such a seizure was also statistically significantly increased in those patients with progressive cerebral metastases who underwent contrast cerebral CT. No relation was observed between the underlying primary malignancy; number, site and CT appearance of brain metastases; and contrast media dosage and the risk of developing a contrast media-associated seizure. The patient population potentially benefiting from the prophylactic injection of diazepam before contrast media administration includes any patient with either known or suspected brain metastases.

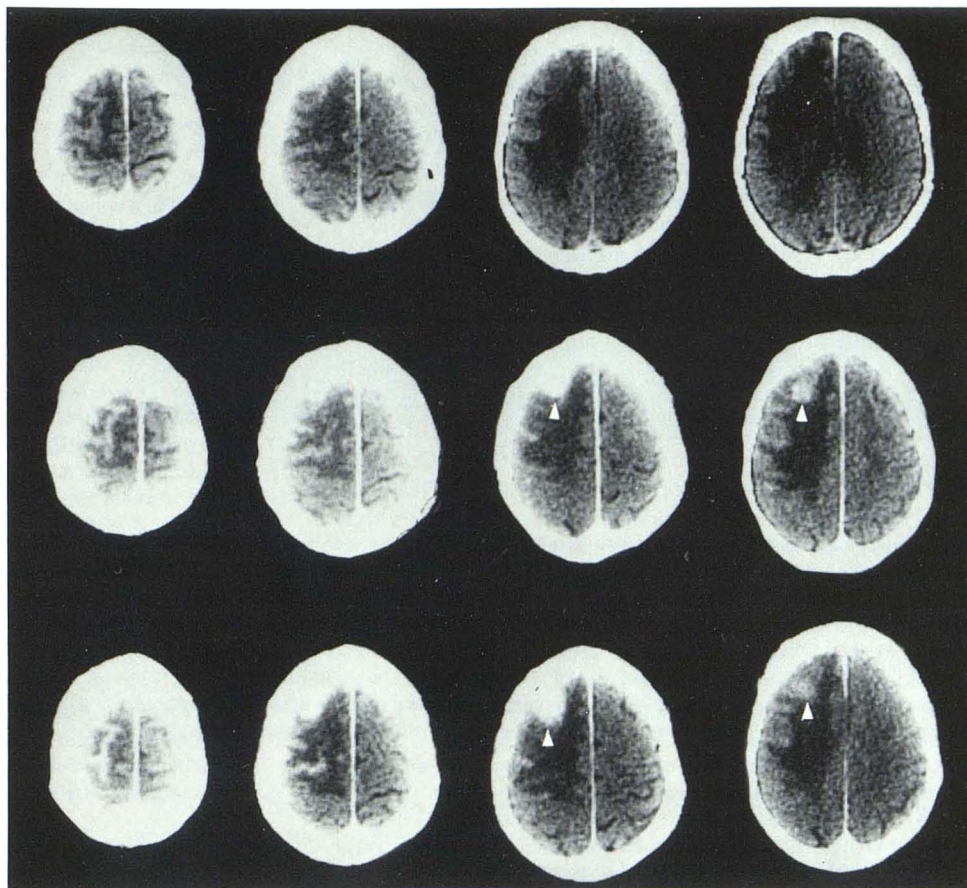
It should be noted that anticonvulsant medication (diphenhydantoin), which is satisfactory by clinical and biochemical criteria, did not protect against contrast media-provoked seizures in 23% of patients with brain metastases who were receiving this medication. We consider precontrast prophylactic diazepam administration a safe and efficacious manner to prevent or diminish this complication of iodinated contrast media administration in patients with brain metastases.

Drowsiness and lethargy are the most common diazepam side effects. Occasionally, transient episodes of hypotension, bradycardia, or apnea are noted after its administration [9]. The latter, more serious side effects are most likely to develop in the elderly or very ill patients and those with limited pulmonary reserve [9–14]. It is important to inject diazepam slowly, taking at least 1 min for each 5 mg administered (Valium Comprehensive product information, Roche Labs.). Concomitant use of barbiturates increases CNS depression with increased risk of these serious side effects, especially apnea [15, 16].

Experiments in feline and simian models have shown that diazepam increases the inhibitory mechanisms that arrest or suppress epileptiform activity from experimentally induced seizure foci [17–19]. The postulated mechanism of diazepam action is through enhancement of postsynaptic inhibition mediated by the neurotransmitter gamma aminobutyric acid (GABA) [20–23].

The exact mechanism of contrast media seizure induction is unknown. Certain factors, however, influence contrast media neurotoxicity. Contrast media consistently induce seizures in patients when injected in large amounts into the subarachnoid space [24] or rapidly and repeatedly in high

Fig. 1.—Cerebral edema in 83-year-old with metastasis in right cerebral hemisphere. *Top row:* noncontrast scans. *Middle row:* high-dose contrast scans 1 hr after infusion illustrate metastatic focus (arrowheads) and enhancement of motor cortex. *Bottom row:* findings intensified on 2 hr delayed scans. Despite persistent accumulation of contrast media, patient did not seize. Window settings were adjusted to maximize enhancement. Intensity of contrast enhancement should be compared with normal cortex of left hemisphere.



osmolar solutions (1,000 mosm/l) into the carotid artery [25]. However, the same contrast media given intravenously cause a seizure in only one of every 10,000 patients undergoing excretory urography [1]. This incidence of intravenous contrast media-associated seizures increases 600- to 1,900-fold if the patient population receiving the contrast media is restricted to those with brain metastases [2, 3]. An even greater 3,000-fold increase will occur if the patient population is limited to those with brain metastases and either a seizure history (caused by the neoplasm) and/or prior or concurrent CNS antineoplastic therapy. Clearly, it is a preexisting seizure focus in patients with brain metastases that allows the intravenous administration of contrast media to induce a seizure. Furthermore, this focus is peculiar to the metastatic lesion, as patients with either other focal brain lesions, such as infarctions, or epileptic foci, such as in idiopathic epilepsy, have a much lower risk of intravenous contrast media-associated seizures.

While it is not clear precisely how contrast media induce seizures, it is obvious that extravasation of contrast media into the brain, which has been linked to contrast media neurotoxicity after intrathecal [25] and intracarotid [17] administration, is not the sole determinant of neurotoxicity after its intravenous administration. Indeed, three of the seven patients in a series by Scott [3] who seized after intravenous contrast media infusion had no CT detectable brain enhancement. Conversely, contrast media extravasa-

tion may be massive in patients with cerebral neoplasms, as seen in our and other series [26], without inducing seizures. In addition, the rapid high-iodine dose technique, which produces increased CT enhancement of a variety of cerebral lesions due to greater contrast media extravasation into the brain, as compared with 40 g iodine doses, is not associated with an increased incidence of seizures, as witnessed by the data in this series (table 4). Clearly, the route of contrast media administration and the particular type of underlying brain pathology are important neurotoxic determinants of contrast media. Contrast media extravasation into the brain per se after its intravenous injection is not a sufficient explanation for its mechanism of neurotoxicity.

The vasogenic brain edema that accompanies metastases produces a local slowing of the cerebral circulation. Fischer [27] postulated this produces a prolonged exposure of vascular endothelium to contrast media, thus allowing a greater opportunity for contrast material to exert its *direct* "permeability changing effect." This allows contrast extravasation, which, he postulates, is the probable cause of seizures in patients with metastases. However, this focal slowing of the cerebral circulation produces a relative degree of ischemia at the margin of the edematous brain surrounding a metastasis. This ischemia may damage vascular endothelium, increase blood-brain barrier permeability, and allow contrast media leakage. Indeed, the observed pattern of enhancement at the edema margin (fig. 1) occurs

in the gray matter and is identical to that seen in strokes and transient ischemic attacks [28]. Pathologic examination of these regions demonstrates small focal cortical infarcts corresponding to the CT contrast enhancing regions [28]. In our series, none of the patients with contrast-associated seizures had the described gray matter enhancement surrounding peritumoral edema, and numerous other patients did have this pattern and did not seize. Therefore, the theory postulated by Fischer does not appear to be an adequate explanation.

Many chemical and physical potentially neurotoxic features of contrast media have been intensively studied. Contrast media seizure induction has occurred with similar frequency in our and other series [2, 3] that used contrast media containing both sodium and meglumine diatrizoate and iohalamate, varying in osmolality from 643 mOsm/l to 2,150 mOsm/l and containing 14%–40% iodine. This wide range of physical and chemical properties indicates that such properties are not important determinants of seizure production after intravenous contrast media injection.

REFERENCES

- Witten DM, Hirsch FD, Hartman GW. Acute reactions to urographic contrast medium. *AJR* **1973**;119:832–840
- LoZito JC. Convulsions: a complication of contrast enhancement and computerized tomography. *Arch Neurol* **1977**;34:649–650
- Scott WR. Seizures: a reaction to contrast media for computed tomography of the brain. *Radiology* **1980**;137:359–361
- Shalen PR, Hayman LA, Wallace S, Handel SF. Protocol for delayed contrast enhancement in computed tomography of cerebral neoplasia. *Radiology* **1981**;139:397–402
- Merritt HH. *Textbook of neurology*. Philadelphia: Lea & Febiger, **1974**:740
- Bishop Y, Fienberg S, Holland P. Discrete multivariate analysis. Cambridge, MA: MIT, **1975**
- Goodman L. The multivariate analysis of qualitative data: interactions among multiple classifications. *J Am Statistical Assoc* **1970**;65:225–256
- Fleiss JL. *Statistical methods for rates and proportions*. New York: Wiley, **1973**:117–118
- Greenblatt DJ, Shader RI. Benzodiazepines. *N Engl J Med* **1974**;291:1011–1015
- Tandon MK. Effect on respiration of diazepam, chlorpromazine and haloperidol in patients with chronic airways obstruction. *Aust NZ J Med* **1976**;6:561–565
- Fleckenstein L, Lifshay A. Respiratory depression from intravenous alphaprodine and diazepam. *Clin Pharmacol Ther* **1979**;25:224
- Gasser JC, Bellville JW. The respiratory effects of hydroxyzine, diazepam and pentazocine in man. *Anaesthesia* **1976**;31:718–723
- Mandelstam P, Sugawa C, Silvis SE. Complications associated with esophagogastroduodenoscopy and with esophageal dilatation. *Gastrointest Endosc* **1976**;23:16–19
- Patrick JM, Sempik AK. The effect of diazepam on the threshold of the ventilatory response to CO₂. *Br J Clin Pharmacol* **1978**;6:462–463
- McNabb TG, Goldwyn RM. Blood gas and hemodynamic effects of sedatives and analgesics when used as a supplement to local anesthesia in plastic surgery. *Plast Reconstr Surg* **1976**;58:37–43
- Aukburg SJ, Miller J, Smith TC. Interaction between meperidine and diazepam on the ventilatory response to CO₂. *Clin Res* **1976**;24:506
- Guerrero-Figueroa R, Rye MM, Heath RG. Effects of two benzodiazepine derivatives on cortical and subcortical epileptogenic tissues in the cat and monkey. *Curr Ther Res* **1969**;11:27–39
- Guerrero-Figueroa R, Rye MM, Guerrero-Figueroa C. Effects of diazepam on secondary subcortical epileptogenic tissues. *Curr Ther Res* **1968**;10:150–166
- Ito T, Hori M, Yoshida K, Shimizu M. Effect of anticonvulsants on cortical focal seizure in cats. *Epilepsia* **1977**;18:63–71
- Kobayashi K, Mori A. Brain monoamines in seizure mechanism. *Folia Psychiatr Neurol Jpn* **1977**;31:483–489
- Haefely W, Kulcsar A, Mohler H, Pieri L, Polc P, Schattner R. Possible involvement of GABA in the central actions of benzodiazepines. *Adv Biochem Psychopharmacol* **1975**;14:131–151
- Mao CC, Guidotti A, Costa E. Evidence for an involvement of GABA in the mediation of the cerebellar cGMP decrease and the anticonvulsant action of diazepam. *Arch Pharmacol* **1975**;289:369–378
- Markovich VV, Ostrovskaya RU. Cortical inhibition processes and the anticonvulsant action of benzodiazepine derivatives. *Biull Eksp Biol Med* **1977**;84:431–433
- Caille JM, Guilbert-Trainer F, Howa JM, Billerey J, Calavet A, Piton J. Cerebral penetration following metrizamide myelography. *J Neuroradiol* **1980**;7:3–12
- Hilal SK. Hemodynamic responses in the cerebral vessels to angiographic contrast media. *Acta Radiol [Diagn]* (Stockh) **1976**;5:211–231
- Neuwelt EA, Diehl JT, Vu LH, Hill SA, Michael AJ, Frankel EP. Monitoring of methotrexate delivery in patients with malignant brain tumors after osmotic blood-brain barrier disruption. *Ann Intern Med* **1981**;94:449–454
- Fischer HW. Occurrence of seizure during cranial computed tomography. Opinion. *Radiology* **1980**;137:563–564
- Kinkel WR, Jacobs L, Kinkel PR. Grey matter enhancement. A computerized tomographic sign of cerebral hypoxia. *Neurology* (NY) **1980**;30:810–819