



**Providing Choice & Value**  
Generic CT and MRI Contrast Agents



CONTACT REP

# AJNR

## **Extracranial Venous Drainage Patterns in Patients with Multiple Sclerosis and Healthy Controls**

R.A. McTaggart, N.J. Fischbein, C.J. Elkins, A. Hsiao, M.J. Cutalo, J. Rosenberg, M.D. Dake and G. Zaharchuk

This information is current as of July 24, 2025.

*AJNR Am J Neuroradiol* 2012, 33 (8) 1615-1620

doi: <https://doi.org/10.3174/ajnr.A3097>

<http://www.ajnr.org/content/33/8/1615>

R.A. McTaggart  
N.J. Fischbein  
C.J. Elkins  
A. Hsiao  
M.J. Cutalo  
J. Rosenberg  
M.D. Dake  
G. Zaharchuk

# Extracranial Venous Drainage Patterns in Patients with Multiple Sclerosis and Healthy Controls

**BACKGROUND AND PURPOSE:** CCSVI hypothesizes an association between impaired extracranial venous drainage and MS. Published sonographic criteria for CCSVI are controversial, and no MR imaging data exist to support the CCSVI hypothesis. Our purpose was to evaluate possible differences in the extracranial venous drainage of MS and healthy controls using both TOF and contrast-enhanced TRICKS MRV.

**MATERIALS AND METHODS:** Healthy subjects ( $n = 20$ ) and patients with MS ( $n = 19$ ) underwent axial 2D-TOF neck MRV (to assess flattening) and TRICKS MRV (to assess collaterals) at 3T. Two neuro-radiologists blinded to cohort status scored IJV flattening and the severity of non-IJV collaterals by using a 4-point qualitative scale (normal = 0, mild = 1, moderate = 2, severe = 3).  $\kappa$  was used to assess reader agreement. Comparisons between groups were performed by using the Wilcoxon rank sum test. The Spearman rank correlation was used to assess the relationship between IJV flattening and collateral scores and, in patients with MS, EDSS scores.

**RESULTS:** The 2 groups were matched for age and sex (MS,  $45 \pm 8$  years, 79% female; healthy controls,  $47 \pm 10$  years, 65% female). Reader agreement for IJV flattening and collateral severity was good ( $\kappa = 0.74$ ) and moderate ( $\kappa = 0.58$ ), respectively. While IJV flattening was seen in both patients with MS and healthy controls, scores for the patients with MS were significantly higher ( $P = .002$ ). Despite a trend, there was no significant difference in collateral scores between groups ( $P = .063$ ). There was a significant positive correlation between flattening and collateral scores ( $\rho = 0.32$ ,  $P = .005$ ) and EDSS and flattening scores ( $\rho = 0.45$ ,  $P = .004$ ) but not between EDSS and collateral scores ( $\rho = 0.01$ ,  $P = .97$ ).

**CONCLUSIONS:** These results indicate that patients with MS have greater IJV flattening and a trend toward more non-IJV collaterals than healthy subjects. The role that this finding plays in the pathogenesis or progression of MS, if any, requires further study.

**ABBREVIATIONS:** ADEM = acute disseminated encephalomyelitis; CCSVI = chronic cerebrospinal venous insufficiency; EDSS = Expanded Disability Status Scale; IJV = internal jugular vein; MIP = maximum intensity projection; TOF = time-of-flight; TRICKS = time-resolved imaging of contrast kinetics; US = sonography

CCSVI is a hypothesis proposed by an Italian vascular surgeon, Paolo Zamboni,<sup>1</sup> that MS may be, in part, a vascular disease with insufficient extracranial venous drainage. The theory appeals to logic when one considers the perivenular or venocentric location of most MS plaques.<sup>2,3</sup> Five sonography criteria were proposed that were said to perfectly distinguish patients with MS from healthy controls.<sup>1</sup> Furthermore, this group believes that patients with MS may benefit from “liberation” angioplasty to relieve lesions that obstruct extracranial venous drainage of the brain.<sup>4</sup> Since Zamboni’s original report,<sup>1</sup> there has been a flurry of Doppler sonography studies that either fail to reproduce his findings<sup>5–8</sup> or demonstrate a weaker association between the proposed US criteria and MS.<sup>9,10</sup>

While a recent study has shown substantial agreement between MRV and findings on contrast venography in patients with MS,<sup>11</sup> early results with MRV demonstrated no differences between patients with MS and healthy controls.<sup>12</sup> We

undertook the current study to evaluate possible differences in the extracranial venous drainage of patients with MS and healthy controls by using both TOF and contrast-enhanced TRICKS MRV.

## Materials and Methods

### Patient Population

We obtained approval from our institutional review board for this prospective study of patients with MS and healthy subjects who underwent MRV, which included axial 2D-TOF and 3D contrast-enhanced TRICKS neck imaging. All subjects were recruited between July 2010 and June 2011. All subjects with MS had definite MS as defined by the 2005 revised McDonald criteria; patients with neuromyelitis optica, MS mimics, transverse myelitis, ADEM, and clinically isolated syndrome were excluded. The EDSS score was self-reported for each MS patient. Inclusion and exclusion criteria were the same as those for the healthy controls (see below), with the exception of findings related to MS. We did not exclude patients on the basis of whether they have or will receive disease-modifying or “step-up” therapies.

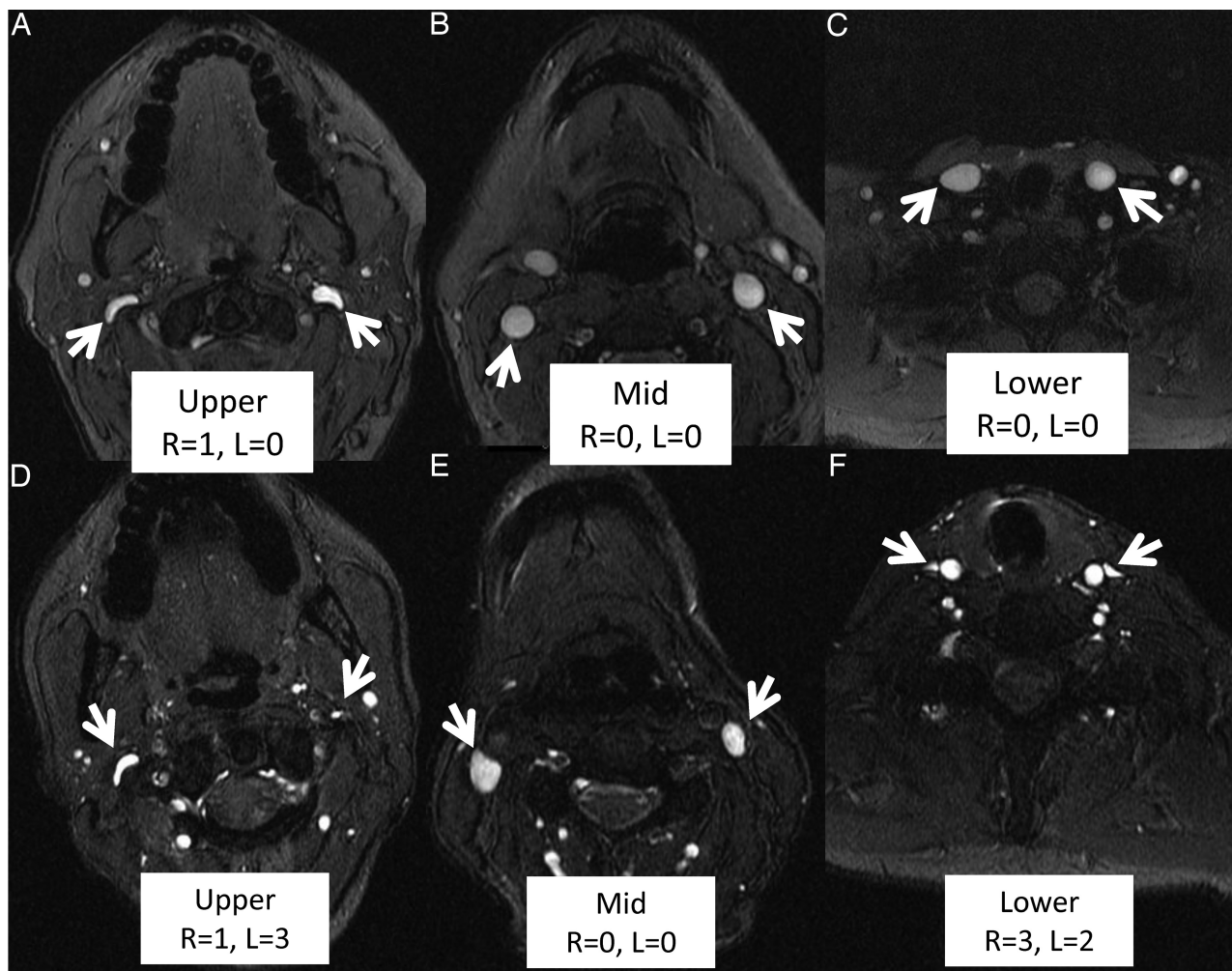
Healthy subjects, men and nonpregnant women at least 21 years of age, were identified by using postings on the Stanford Clinical Trials Directory Web site (<http://med.stanford.edu/clinicaltrials>), San Francisco Bay area Craigslist volunteer section (<http://sfbay>).

Received August 31, 2011; accepted after revision November 10.

From the Departments of Radiology (R.A.M., N.J.F., C.J.E., A.H., M.J.C., J.R., G.Z.) and Cardiothoracic Surgery (M.D.D.), Stanford University, Stanford University Medical Center, Stanford, California.

Please address correspondence to Ryan A. McTaggart, MD, Department of Radiology, Stanford University Medical Center, Grant Bldg S047, Stanford, CA 94305; e-mail: [ryanmct@stanford.edu](mailto:ryanmct@stanford.edu)

<http://dx.doi.org/10.3174/ajnr.A3097>



**Fig 1.** Qualitative grading of IJV flattening in the upper neck in a healthy subject and a patient with MS. *A–C*, Representative images from a healthy subject demonstrating only mild flattening of the right internal jugular vein in the upper neck segment (*A*). *D–F*, Representative images from a patient with MS with more severe flattening. While there is no flattening in the midneck segment on the right or left side (*E*), there is mild and severe narrowing in the upper neck segment on the right and left sides (*D*), respectively, and severe and moderate narrowing in the lower neck segment on the right and left sides (*F*).

craigslist.org/vol/), and advertisements on campus bulletin boards and local newspapers. We ensured age and sex matching by basing our recruitment on the demographics from recruited patients with MS.

Exclusion criteria were the following: 1) evidence of demyelinating disease, including MS and ADEM, based on either clinical history or imaging; 2) evidence of prior large-vessel-territory ischemic event, psychiatric or substance abuse disorder, or dementia that interferes with neurologic assessment; 3) coexisting or terminal systemic disease that limits life expectancy or otherwise interferes with the study; 4) prior indwelling catheter or thrombosis in either jugular vein; 5) any prior external radiation, trauma, or surgery to the neck; and 6) dialysis-dependent renal failure or renal failure as documented by creatinine clearance levels below 30 mL/min.

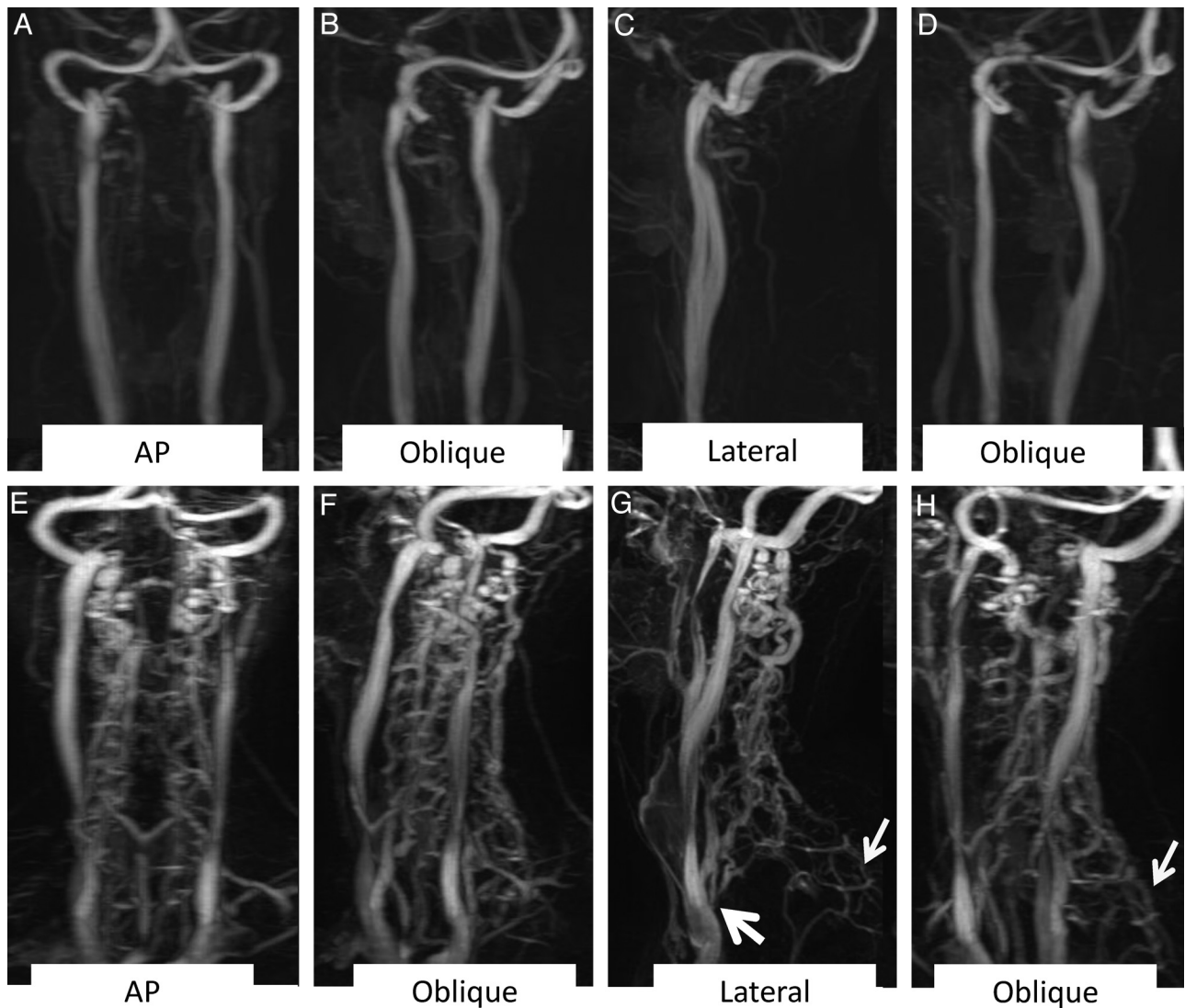
### Imaging Methods

All patients were imaged at 3T (MR 750; GE Healthcare, Milwaukee, Wisconsin) by using the head-neck vascular array coil. To assess IJV flattening, precontrast axial 2D-TOF venography was performed from the skull base to the superior vena cava–azygous junction with inferior saturation bands and the following parameters: TR/TE, 34/9 ms; flip angle, 30°; section thickness, 3 mm; skip, 0 mm; FOV, 24 cm; matrix, 384 × 192. To assess the presence and severity of collaterals,

contrast-enhanced sagittal TRICKS venography was performed during the bolus administration of gadobenate dimeglumine (MultiHance; Bracco Diagnostics, Princeton, New Jersey) at a dose of 0.05-mmol/kg and a flow rate of 3 mL/s, with the following parameters: TR/TE, 6/1.3 ms; flip angle, 30°; section thickness, 1.7 mm; skip, 0; FOV, 40 cm; matrix, 416 × 192. Time-resolved MIP images at 6.4-second intervals were created. On the basis of this, the phases with the most arterial opacification and the most venous opacification were identified and subtracted from one another to create an image depicting only the veins. In addition, a rotating MIP image from these raw data was generated.

### Data Analysis

Images from the precontrast axial 2D-TOF venography (flattening) and contrast-enhanced sagittal TRICKS venography (collaterals) were scored by 2 neuroradiologists (N.F. and G.Z.) blinded to cohort status. Axial 2D-TOF images were assessed in the upper (C1–C3), mid (C3–C5), and low (C6–T2) neck. Vein-flattening scores were assigned as follows: 0, normal (0%–25% narrowed); 1, mild flattening (25%–50% narrowed); 2, moderate flattening (50%–75% narrowed); and 3, absent, nearly absent, or pinpoint (75%–100% narrowed) (Fig 1).<sup>11</sup> Collaterals were evaluated by using the TRICKS images with particu-



**Fig 2.** Qualitative grading scale for the presence and severity of neck collaterals in a healthy subject and a patient with MS (same subjects as in Fig 1). Select images from rotating MRV maximum-intensity-projection images are displayed (both source and rotating MIP images were available for review). *A–D*, Representative images from a healthy subject demonstrating the absence of significant collaterals (right side scored 0, left side scored 0). *E–H*, Representative images from a patient with MS with severe collaterals bilaterally, demonstrating prominent veins in the posterior paraspinal soft tissues of the upper neck with clear insertion of the vertebral artery venous plexus and deep cervical vein on the low IJV near the confluence (*thick arrow*). In addition, there are prominent upper thoracic paraspinal collateral veins (right side scored 3, left side scored 3) (*thinner arrows*).

lar focus on the venous structures in the posterior paraspinal soft tissues. Score assignments were as follows: 0, none (no collaterals seen in the posterior paraspinal soft tissues of the upper neck); 1, mild (collaterals present in the posterior paraspinal soft tissues of the upper neck, but neither the vertebral artery venous plexus nor the deep cervical vein could be seen inserting on the low IJV near the IJV-subclavian confluence); 2, moderate (prominent collateral veins with clear insertion of the deep cervical vein on the low IJV near the confluence); and 3, severe (same as 2, but with additional prominence of upper thoracic paraspinal collateral veins) (Fig 2). For both axial 2D-TOF and TRICKS images, the right and left sides were scored separately.

### Statistical Analysis

Scores for each patient were evaluated per side and per segment for axial TOF imaging (flattening) and only per side for TRICKS imaging (collaterals). Agreement between readers was assessed with linearly weighted  $\kappa$  and an exact Bowker test of symmetry. Differences in

flattening and collaterals between patients with MS and healthy subjects were tested by the Wilcoxon test in both pooled analyses and with dichotomization into groups with scores of 0 and 1 versus scores of 2 and 3. To assess the relationship between IJV flattening scores and collateral scores, for each subject, the 6 IJV flattening scores (lower, mid, and high IJV on both sides) were summed and compared with the sum of the 2 collateral scores (left and right). To assess the relationship of EDSS scores in patients with MS to flattening scores and collateral scores, the EDSS score was compared with pooled summed flattening scores and pooled summed collateral scores, respectively. Correlation was calculated by using the Spearman rank coefficient. All statistical analyses were done with STATA, Release 9.2 (StataCorp, College Station, Texas) by a biostatistician (J.R.). A *P* value of .05 was considered significant.

### Results

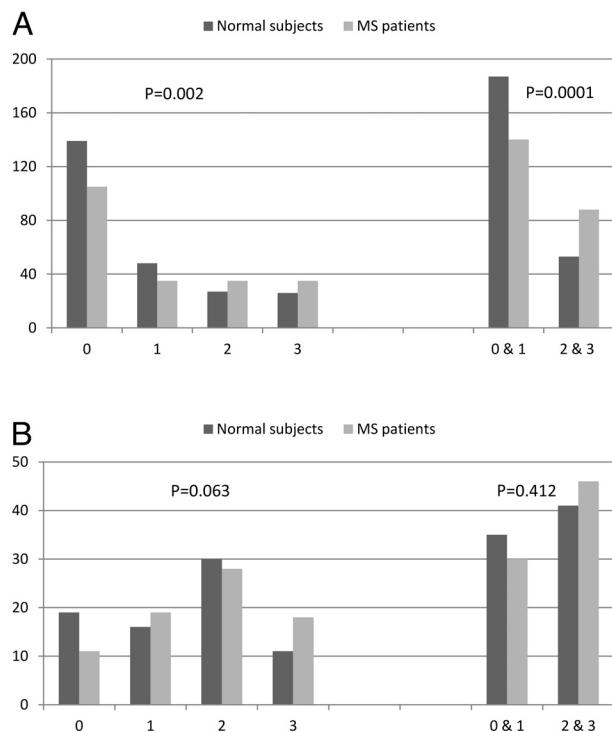
Twenty healthy subjects and 19 patients with MS were imaged. All 39 patients had axial TOF for analysis. TRICKS data were



**Reader agreement for axial TOF imaging to assess the presence and severity of flattening and TRICKS imaging to assess the presence and severity of collaterals<sup>a</sup>**

	Right	Left	Overall ( <i>P</i> value)
Flattening	0.75	0.73	0.74 (<.0001)
Upper	0.71	0.68	
Mid	0.41	0.55	
Lower	0.79	0.77	
Collaterals	0.57	0.59	0.58 (<.0001)

<sup>a</sup> Numbers presented are linear-weighted  $\kappa$ .



**Fig 3.** Pooled and dichotomized analyses of IJV flattening scores (A) and collateral scores (B) in healthy subjects and patients with MS. The y-axis represents the number of segments (A) or sides (B) score at this level.

available for 38 patients (the power injector failed for 1 healthy subject). The healthy subjects and MS cohorts were age- ( $45 \pm 8$  versus  $47 \pm 10$  years;  $P = .59$ ) and sex-matched (65% female versus 79% female;  $P = .48$ ). Patients with MS had an average EDSS score of 4.2 (range, 1–7). Eighteen (95%) of our patients with MS had relapsing-remitting MS; 1 had secondary-progressive MS.

Reader agreement for axial TOF imaging (flattening) was good, and for TRICKS imaging (collaterals), it was moderate (Table). We observed segments of IJV flattening and frank nonvisualization in both the healthy subjects and patients with MS. However, despite this finding, in both our pooled and dichotomized analysis of vein-flattening scores, patients with MS had significantly higher score assignments compared with the healthy controls ( $P = .002$ , Fig 3A), which became more pronounced by using the dichotomized scores. Despite a trend toward higher scores in patients with MS, no significant differences in collateral scores were present between groups ( $P = .06$ , Fig 3B). The relationship became weaker after dichotomizing the scores.

We found a small but significant correlation between flat-

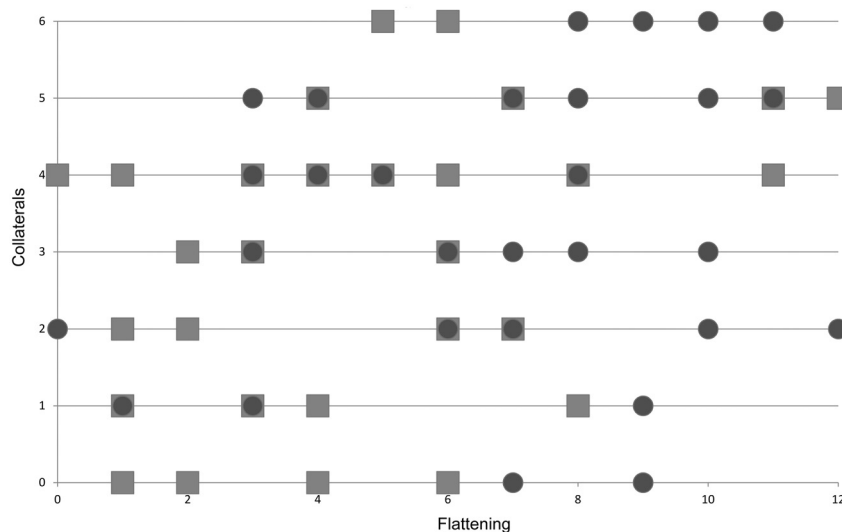
tening and collateral scores ( $\rho = 0.32$ ;  $P = .005$ ). A scatterplot of summed flattening versus summed collateral scores illustrates this, showing the tendency for patients with MS to have higher flattening and collateral scores than healthy controls (Fig 4). Examples of the correlation between IJV flattening and collaterals for healthy subjects and patients with MS are shown as Figs 1 and 2. We found a positive correlation between EDSS and composite flattening scores ( $\rho = 0.45$ ,  $P = .004$ ) but no correlation between EDSS and composite collateral scores ( $\rho = 0.01$ ,  $P = .97$ ) in patients with MS.

## Discussion

This study presents the first report of differences in the extracranial venous drainage of patients with MS and healthy controls by using MRV, to our knowledge. A linear ordinal scale ranging from no flattening to severe flattening or absence of the vein was shown to have good inter-reader agreement. Patients with MS had greater flattening of the IJVs than healthy controls. Despite a trend, no significant differences were seen in collateral scores between patients with MS and healthy controls. However, there was a small but significant correlation between higher flattening scores and higher collateral scores. Most interesting, the self-reported EDSS scores in our patients with MS correlated with IJV flattening scores.

Our results contradict those of Zivadinov et al,<sup>12</sup> who found no significant differences in the extracranial venous systems between patients with MS and healthy controls. This apparent contradiction may be due to the differences in the scoring systems and patient populations between the 2 studies. In their study, an ordinal scale of absent, pinpoint, flattened, crescentic, and ellipsoidal was used to score IJV flattening. Many of these groups had poor agreement between readers (ranging from  $\kappa = 0.2$  for crescentic to  $\kappa = 0.59$  for ellipsoid; an overall  $\kappa$  was not presented). In contrast, the current study used a more linear scale that led to better inter-reader agreement ( $\kappa = 0.74$ ), which may have increased the odds of detecting a difference in the pooled analysis. Furthermore, they had a higher percentage of patients with secondary-progressive MS, and the overall mean EDSS score was lower (2.5 versus 4.2 in the current study). Despite these methodologic differences, it is interesting that in this prior study, 51% of patients with MS had either absent or pinpoint IJV morphology, whereas only 33% of the healthy subjects had this morphology.

With regard to the presence and severity of collaterals (defined as vein prominence by Zivadinov et al<sup>12</sup>), our methods again differ, but not arbitrarily. We believe that the major extracranial cerebral venous outflow pathway other than the internal jugular veins is mediated by the anterior condylar confluence and the vertebral venous plexus;<sup>13</sup> this is the primary extracranial venous drainage system in the upright system. Our collateral scoring system emphasizes this pathway because we assessed primarily the prominence of veins in the posterior paraspinal soft tissues with particular attention to the presence of the vertebral venous plexus and deep cervical vein insertion (grade 2) on the low IJV and the presence of this finding in combination with prominent upper thoracic collaterals (grade 3). Unlike Zivadinov et al, we ignored the facial, external jugular, and anterior jugular veins. While Zivadinov et al concluded that there were no significant differences in



**Fig 4.** Relationship between summed (per side) collateral scores and summed (per side and per segment) IJV flattening scores. Each data point represents a single individual. There is a small but significant correlation between higher IJV flattening scores and higher collateral scores ( $p = 0.32$ ;  $P = .005$ ). In addition, patients with MS (circles) tend to cluster in the upper right compared with healthy subjects (squares), who cluster in the lower left, though there is significant overlap.

vein prominence between patients with MS and healthy subjects, they did report that 21% (12/57) of patients with MS versus 0% (0/21) of healthy subjects had prominent deep cervical veins ( $P = .03$ ). Unfortunately, the extracranial venous drainage pathways are immense and complicated, and no perfect scoring may exist for collaterals in the supine position. However, if obstructing lesions of the internal jugular veins are indeed present in patients with MS, it seems logical that these would lead to unexpected prominence of the vertebral venous system in the supine position.

We previously reported a poor correlation between increasing collateral scores and flattening scores with MRV.<sup>11</sup> The correlation in the current study is stronger and significant in this cohort perhaps because these patients were imaged at 3T and a more refined collateral scoring system was used. Furthermore, patients with MS appeared to be over-represented in the right upper quadrant of Fig 4, where patients have higher flattening and collateral scores. We did not expect MRV to recapitulate the CCSVI US criteria; thus, while MRV falls short of the Doppler US protocol of Zamboni et al<sup>1</sup> to distinguish patients with MS from healthy controls, we do see differences that were not detected by others.<sup>5-8,14,15</sup> Despite the fact that we detected differences between patients with MS and healthy controls, we agree with Zivadinov et al<sup>12</sup> that conventional MRV (TOF and even TRICKS) has limited value for assessing IJV anomalies for diagnostic and, if CCSVI is real, posttreatment purposes. Other methods, including quantitative time-resolved 3D phase-contrast imaging (4D flow) may allow the detection of more subtle differences between extracranial venous drainage in patients with MS and healthy controls. While these data were collected in these cohorts, given the complexity and wealth of information, it will be reported separately.

Limitations of our study include our lack of image-reimage reproducibility, lack of a reference standard (such as contrast venography), selection of patients with MS, and a small sample size. We agree with others who claim that MRV may be limited because it is static, and vein flattening seen in some of

our patients may be explained by day-to-day physiologic variance.<sup>12,16</sup> However, if true, this would serve to reduce the likelihood of finding a significant result. In no patient did we find the TOF limited by flow-related artifacts; severe flattening scores assigned on TOF imaging correlated well with flattening findings seen on contrast-enhanced TRICKS imaging as we have previously reported.<sup>11</sup> Finally, although they did not have prior vascular imaging, the patients with MS included in our study were referred for possible angioplasty and thus may not accurately represent MS in general.

While our study points to an association between IJV flattening and the presence of MS, it in no way implies a causative role or that a treatment such as angioplasty or stent placement would have any effect on disease progression or symptoms. While MRV in our study does detect a difference between patients with MS and healthy controls, the MRV techniques used herein are not adequately sensitive to detect intrinsic lesions of the IJV that are postulated by others to exist, such as webs, malformed valves, or strictures. Comparison of these qualitative findings with quantitative imaging of 4D flow and cerebral perfusion may help illuminate whether these findings have physiologic consequences on brain perfusion.

## Conclusions

Using a simple scoring system, we found good inter-reader agreement for 2D-TOF MRV to assess IJV flattening and moderate agreement for contrast-enhanced TRICKS MRV to assess the presence and severity of posterior paraspinal collaterals. We found significantly higher flattening scores in patients with MS compared with healthy subjects, but only a trend toward more severe non-IJV collaterals. Self-reported EDSS scores in our patients with MS correlated with IJV flattening scores. Finally, we found a small but significant correlation between IJV flattening and the severity of non-IJV collaterals. Future studies should explore more sophisticated quantitative imaging techniques such as 4D flow and cerebral perfusion imaging, which may help put the current results into physiologic context.

Disclosures: Nancy Fischbein—**UNRELATED:** *Royalties:* Thieme Medical Publishers, *Comments:* small royalties on a cranial nerve and teaching file book, Greg Zaharchuk—**UNRELATED:** *Board Membership:* GE Healthcare, *Comments:* Neuroradiology Advisory Board, *Grants/Grants Pending:* National Institutes of Health, GE Healthcare.

## References

1. Zamboni P, Galeotti R, Menegatti E, et al. **Chronic cerebrospinal venous insufficiency in patients with multiple sclerosis.** *J Neurol Neurosurg Psychiatry* 2009;80:392–99
2. Tallantyre EC, Morgan PS, Dixon JE, et al. **A comparison of 3T and 7T in the detection of small parenchymal veins within MS lesions.** *Invest Radiol* 2009;44:491–94
3. Tan IL, van Schijndel RA, Pouwels PJ, et al. **MR venography of multiple sclerosis.** *AJNR Am J Neuroradiol* 2000;21:1039–42
4. Zamboni P, Galeotti R, Menegatti E, et al. **A prospective open-label study of endovascular treatment of chronic cerebrospinal venous insufficiency.** *J Vasc Surg* 2009;50:1348–58 e1341–1343
5. Baracchini C, Perini P, Calabrese M, et al. **No evidence of chronic cerebrospinal venous insufficiency at multiple sclerosis onset.** *Ann Neurol* 2011;69:90–99
6. Centonze D, Floris R, Stefanini M, et al. **Proposed chronic cerebrospinal venous insufficiency criteria do not predict multiple sclerosis risk or severity.** *Ann Neurol* 2011;70:51–58
7. Doepp F, Paul F, Valdueza JM, et al. **No cerebrocervical venous congestion in patients with multiple sclerosis.** *Ann Neurol* 2010;68:173–83
8. Mayer CA, Pfeilschifter W, Lorenz MW, et al. **The perfect crime? CCSVI not leaving a trace in MS.** *J Neurol Neurosurg Psychiatry* 2011;82:436–40
9. Al-Omari MH, Rousan LA. **Internal jugular vein morphology and hemodynamics in patients with multiple sclerosis.** *Int Angiol* 2010;29:115–20
10. Zivadinov R, Marr K, Cutter G, et al. **Prevalence, sensitivity, and specificity of chronic cerebrospinal venous insufficiency in MS.** *Neurology* 2011;77:138–44
11. Zaharchuk G, Fischbein NJ, Rosenberg J, et al. **Comparison of MR and contrast venography of the cervical venous system in multiple sclerosis.** *AJNR Am J Neuroradiol* 2011;32:1482–89
12. Zivadinov R, Lopez-Soriano A, Weinstock-Guttman B, et al. **Use of MR venography for characterization of the extracranial venous system in patients with multiple sclerosis and healthy control subjects.** *Radiology* 2011;258:562–70
13. San Millan Ruiz D, Gailloud P, Rufenacht DA, et al. **The craniocervical venous system in relation to cerebral venous drainage.** *AJNR Am J Neuroradiol* 2002;23:1500–08
14. Sundstrom P, Wahlin A, Ambarki K, et al. **Venous and cerebrospinal fluid flow in multiple sclerosis: a case-control study.** *Ann Neurol* 2010;68:255–59
15. Wattjes MP, van Oosten BW, de Graaf WL, et al. **No association of abnormal cranial venous drainage with multiple sclerosis: a magnetic resonance venography and flow-quantification study.** *J Neurol Neurosurg Psychiatry* 2011;82:429–35
16. Zivadinov R, Galeotti R, Hojnacki D, et al. **Value of MR venography for detection of internal jugular vein anomalies in multiple sclerosis: a pilot longitudinal study.** *AJNR Am J Neuroradiol* 2011;32:938–46