



Providing Choice & Value
Generic CT and MRI Contrast Agents



CONTACT REP

AJNR

Syndromes of the First and Second Branchial Arches, Part 2: Syndromes

J.M. Johnson, G. Moonis, G.E. Green, R. Carmody and H.N. Burbank

AJNR Am J Neuroradiol 2011, 32 (2) 230-237

doi: <https://doi.org/10.3174/ajnr.A2073>

<http://www.ajnr.org/content/32/2/230>

This information is current as of July 20, 2025.

REVIEW ARTICLE

J.M. Johnson
G. Moonis
G.E. Green
R. Carmody
H.N. Burbank



Syndromes of the First and Second Branchial Arches, Part 2: Syndromes

SUMMARY: A variety of congenital syndromes affecting the face occur due to defects involving the first and second BAs. Radiographic evaluation of craniofacial deformities is necessary to define aberrant anatomy, plan surgical procedures, and evaluate the effects of craniofacial growth and surgical reconstructions. High-resolution CT has proved vital in determining the nature and extent of these syndromes. The radiologic evaluation of syndromes of the first and second BA should begin first by studying a series of isolated defects (cleft lip with or without CP, micrognathia, and EAC atresia) that compose the major features of these syndromes and allow a more specific diagnosis. After discussion of these defects and the associated embryology, we discuss PRS, HFM, ACS, TCS, Stickler syndrome, and VCFS.

ABBREVIATIONS: ACS = auriculocondylar syndrome; BA = branchial arch; CP = cleft palate; EAC = external auditory canal; HFM = hemifacial microsomia; OAV = oculoauriculovertbral; OMIM = Online Mendelian Inheritance in Man; PRS = Pierre Robin sequence; TCS = Treacher Collins syndrome; TMJ = temporomandibular joint; VCFS = velocardiofacial syndrome

Radiographic evaluation of craniofacial deformities is necessary to define aberrant anatomy, plan surgical procedures, and evaluate the effects of craniofacial growth and surgical reconstructions.¹ The recent rapid proliferation of multidetector CT is due, in part, to the increased use of this technique for multiplanar bone and soft-tissue imaging. The definition of the fine bony structure of the craniofacial anatomy on CT images is unmatched by other modalities. There has also been more demand for treatment planning along with the advances in high-resolution CT evaluation and 3D reconstruction techniques.

Knowledge of the genetic basis of human disease and its effect on embryologic development has greatly expanded in recent years. Disorders of the first and second BAs are generally thought to result from a combination of inadequate migration and formation of facial mesenchyma. Because many structures of the head and neck migrate during fetal development, an understanding of embryologic development helps determine the origin and nature of congenital lesions. Familiarity with craniofacial embryology and its associated effects on resultant anatomy also leads to a better understanding of the pathophysiologic basis of craniofacial syndromes. Additionally, it helps to establish a search pattern for characteristic radiologic features of many of these anomalies.

Part 1 of this review established the embryology, developmental anatomy, clinical symptoms, and characteristic imaging features of the isolated defects that compose some of the major features of the syndromes of the first and second BAs. Part 2 of this review discusses the syndromes and their radio-

graphic features: PRS, HFM, ACS, TCS, Stickler syndrome, and VCFS. When applicable, the number is given from the public data base of bibliographic information about human genes and genetic disorders—OMIM (<http://www.ncbi.nlm.nih.gov/omim>).

Syndromes

PRS: OMIM 261800

The original account of PRS in 1923, by a French physician,² described neonates with unusually small mandibles (micrognathia), posterior displacement or retraction of the tongue (glossoptosis), and upper airway obstruction. Because incomplete closure of the roof of the mouth (CP) is present in most patients, Robin later added CP deformity as an associated feature.³⁻⁷ Studies have documented that there is also associated bimaxillary retrognathia, with reduced sagittal length of not only the mandible but also the maxilla.⁸ Although the possibility that the mandible may grow forward and partially or fully catch up during the first years of life has been discussed in the literature, recent studies have suggested that no significant catch-up growth of the mandible in PRS occurs in the first 22 months of life. The differential growth shown in these studies does not improve the size of the pharyngeal airway but does improve the relative size of the oropharynx, which can have a positive effect on breathing difficulties.^{5,8,9}

Glossoptosis may be detected on a lateral radiograph of the soft tissues of the neck by identifying encroachment of soft tissues on the pharyngeal airway.¹⁰ The obstructing mechanism of the tongue is a combination of the backward displacement of the mandibular symphysis causing passive dorsal pressure on the tongue and the backward placement of the genioglossi muscles, the principal means of drawing the tongue forward. The problems seen with glossoptosis are compounded by the lack of adequate skeletal support for the pharyngeal soft tissues seen in isolated micrognathia. Radiographic evaluation typically reveals relatively symmetric hypoplasia of the mandible. There may be associated condylar and coronoid hypoplasia. The tongue may appear prominent in relation to the relative size of the oropharynx. Additionally,

From the Division of Neuroradiology (J.M.J., H.N.B.), Department of Radiology, Fletcher Allen Health Care, Burlington, Vermont; Division of Neuroradiology (G.M.), Department of Radiology, Beth Israel Deaconess Medical Center and Mass Eye and Ear Infirmary, Harvard Medical School, Boston, Massachusetts; Department of Pediatric Otolaryngology (G.E.G.), University of Michigan, Ann Arbor, Michigan; and Division of Neuroradiology (R.C.), Department of Radiology, University of Arizona, Tucson, Arizona.

Please address correspondence to Jason M. Johnson, MD, Department of Radiology, 111 Colchester Ave, Burlington, VT 05401; e-mail: Jason.Johnson@vtmednet.org



Indicates open access to non-subscribers at www.ajnr.org

DOI 10.3174/ajnr.A2073

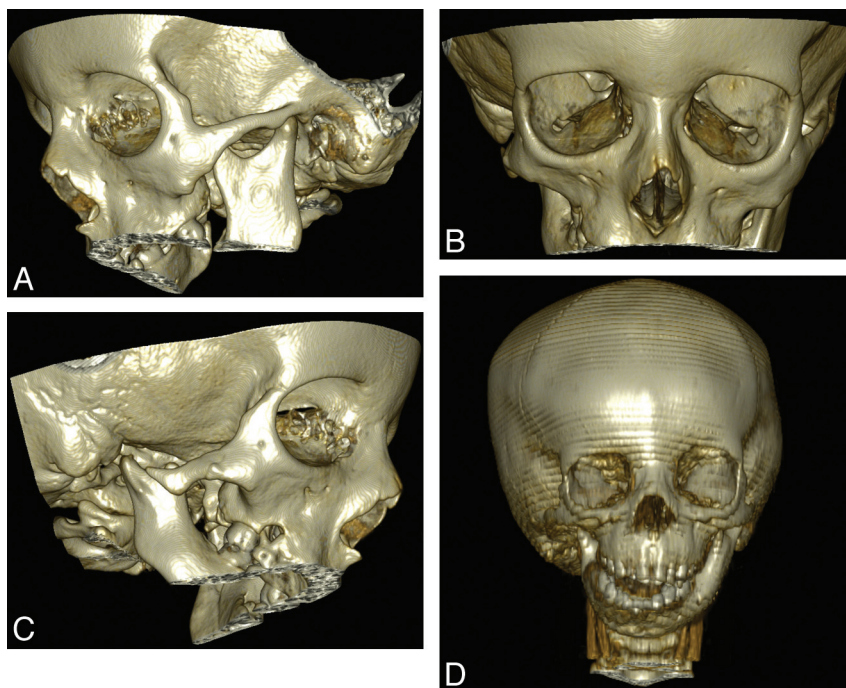


Fig 1. Young adult with hemifacial microstomia. *A–C*, 3D bone reconstruction shows right mandibular and maxillary hypoplasia compared with the normal-appearing left condyle. *D*, A 3-year-old boy with hemifacial microstomia. 3D bone reconstruction shows a more dramatic appearance of asymmetric hypoplasia of the mandible.

various severities of CP are seen, which may involve both the primary and secondary palates, leading to open communication between the nasal and oral cavities.

Stickler syndrome and VCFS are present in as many as one-third of patients with PRS. The sequence can also be seen in ACS, Goldenhar syndrome, and TCS.

HFM: OMIM 164210

HFM is a common facial birth defect involving the first and second BA structures and ranks second in prevalence only behind facial clefting.¹¹ Males are affected more frequently than females. About 45% of patients have affected relatives, and 5%–10% have affected siblings.¹² The phenotype is highly variable. There may be cardiac, vertebral, and central nervous system defects, in addition to craniofacial anomalies. Ear deformities occur along a spectrum from the size and shape of the external auricle to anotia.

When epibulbar dermoids and vertebral anomalies are seen along with other findings of HFM, the syndrome is called Goldenhar syndrome.¹³ Goldenhar¹⁴ first described the triad of epibulbar choristomas, preauricular skin appendages, and pretragal blind-ending fistulas in association with mandibular facial dysplasia. Later patients with associated vertebral anomalies were given the classification of OAV dysplasia.¹³ The combination of OAV features and microtia is termed the “OAV complex.”¹² When the features of the OAV complex are predominantly unilateral and lack vertebral anomalies and epibulbar dermoids, the condition has been called HFM. This pattern is thought to represent a variant of the expanded OAV complex.¹⁵

A variety of terms have been proposed that serve to indicate the spectrum of anomalies associated with the OAV complex. Additional names of these variants include Goldenhar-Gorlin syndrome, first arch syndrome, first and second BA syndrome,

lateral facial dysplasia, unilateral craniofacial microsomia, otomandibular dysostosis, unilateral mandibulofacial dysostosis, unilateral intrauterine facial necrosis, auriculobranchiogenic dysplasia, and facioauriculovertebral malformation complex. The terms and systems of classification have been reviewed multiples times.^{16–20}

Radiographic evaluation of HFM reveals asymmetric hypoplasia of the maxilla and mandible. One side of the face may be normally developed (Fig 1). There are variable degrees of malformation involving the TMJ, including hypoplasia of the condyle and coronoid. A large variation in the TMJ has been observed on the more affected side; however, the degree of TMJ disk dysplasia does not appear to correlate with the degree of mandibular dysplasia.²¹ There is often a unilateral deformity of the external ear. A coloboma of the upper eyelid is frequently encountered and may be seen radiographically on soft-tissue windows. Ear deformities range from isolated preauricular tags to atresia of the EAC. A detailed examination of the temporal bone should be performed to evaluate associated, though uncommon, malformations of the middle ear and an aberrant course of the facial nerve. The OMENS (orbit, mandible, ear, cranial nerve, and soft tissues) system has been proposed to classify the severity of each of the major craniofacial manifestations of HFM.²⁰

ACS: OMIM 602483

The ACS, first described by Uuspää in 1978, is now recognized as a distinct autosomal dominant disorder. The features seen in ACS have previously been ascribed the names “Cosman ear” and the “question mark ear.”^{22,23} Prominent malformed ears, with auricular clefts, mandibular condyle aplasia or hypoplasia, and a number of other auricular and oral abnormalities characterize ACS. In its most severe form, there are severe micrognathia and a characteristically round facial appearance

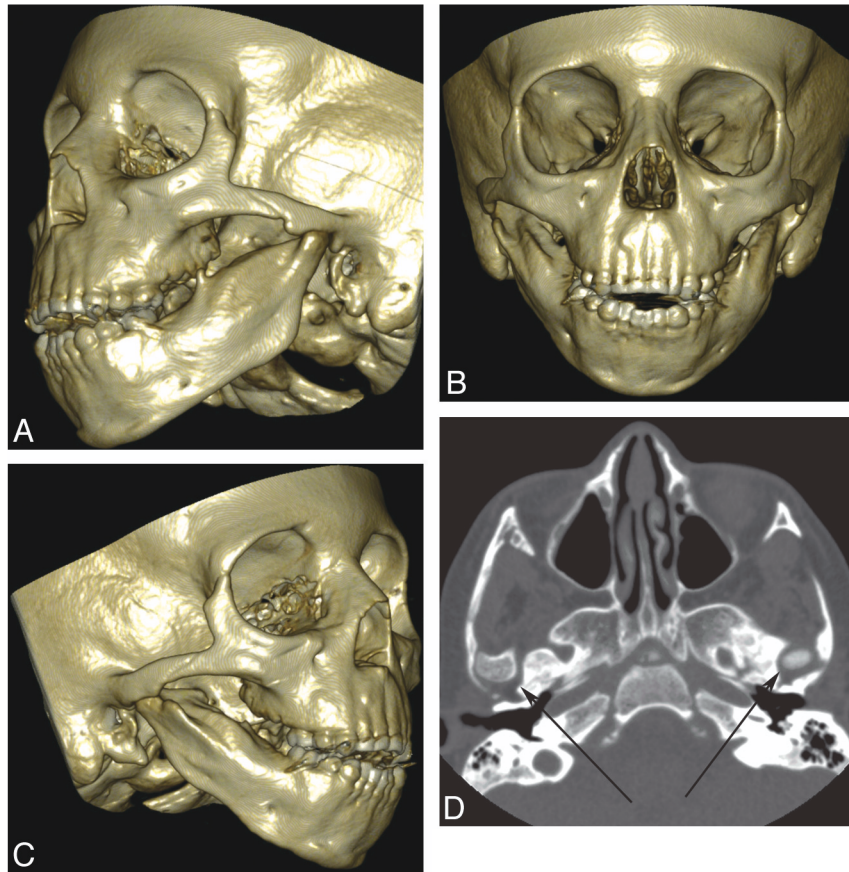


Fig 2. A 5-year-old boy with ACS. *A–C*, 3D bony reconstructions show an absent condylar processes, asymmetric micrognathia, and hypoplastic condyles. *D*, Axial CT scan shows bilateral abnormal TMJs (arrows) with dysplastic condylar processes.

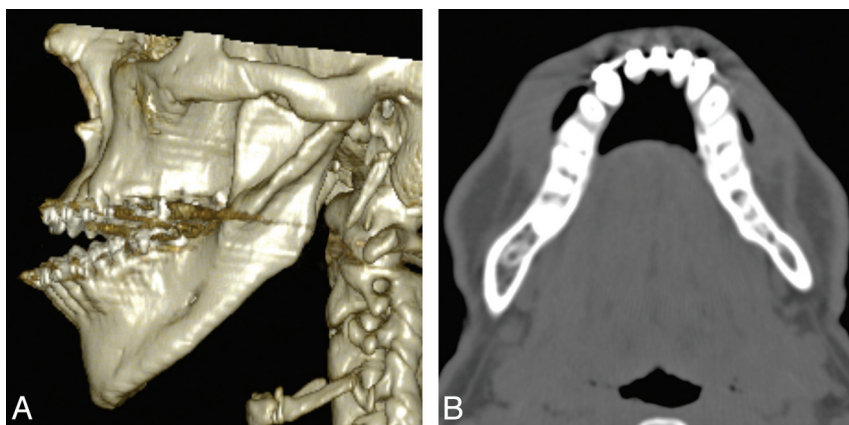


Fig 3. An 18-year-old man with ACS. *A*, 3D bony reconstruction shows micrognathia with overprotrusion of the mandible in relation to the maxilla. The lateral mandibular cleft is a feature commonly seen in ACS (see also Fig 2). *B*, Axial CT scan also shows the asymmetry of the dysplastic protruding mandible.

with prominent cheeks. Inter- and intrafamilial variability is marked, and some obligate carriers are nonpenetrant.^{24–26} A genome-wide search of 2 families with ACS revealed evidence of linkage to 1p21.1–q23.3 in 1 of the families and nonlinkage in the other. These findings suggest evidence for genetic heterogeneity and the existence of at least 2 loci responsible for this syndrome.²⁷

A characteristic auricular cleft malformation is seen in ACS, which consists of a protuberant cupped pinna with a cleft or notching between the lobule and the helix. The cleft may be

subtle or severe enough to detach the lobule from the helix. The anomalies can be unilateral or bilateral and are typically asymmetric. Some individuals have low-set and posteriorly rotated ears. Pre- and postauricular tags may be present. Hearing and middle ear functions are generally normal; however, sensorineural hearing loss has been reported.²⁸

Complete mandibular condyle agenesis, hypoplasia, or more subtle clinical and radiographic anomalies may be present. These findings include micrognathia, short mandibular rami, small coronoid processes, poorly formed TMJs,

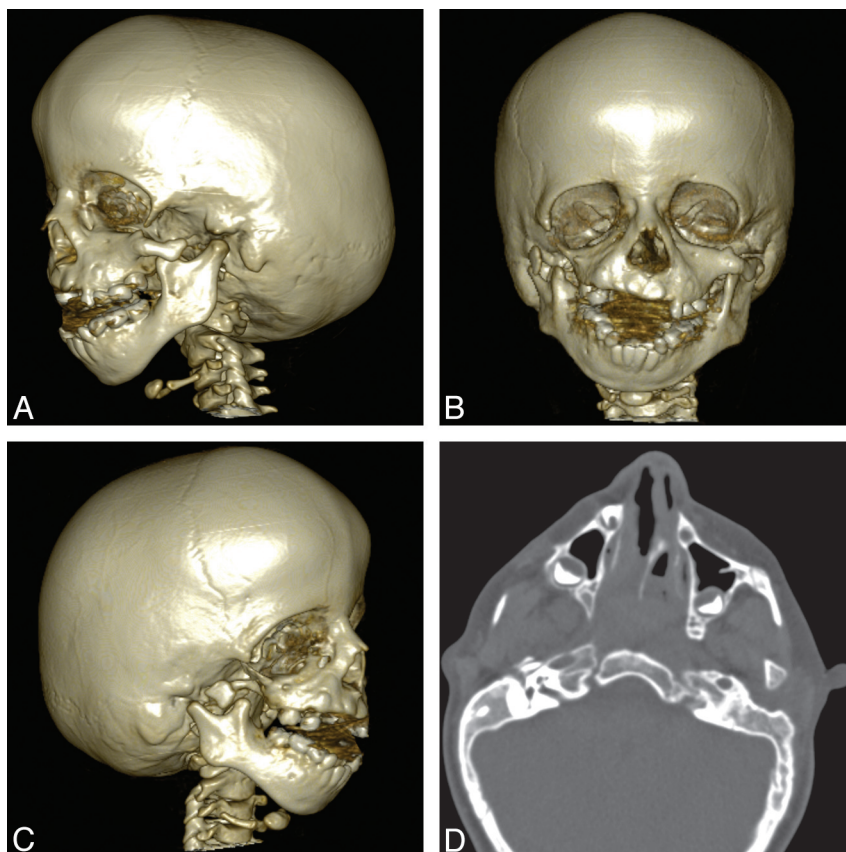


Fig 4. A 4-year-old girl with TCS. A–C, 3D bone reconstructions show bilateral and asymmetric abnormalities of the mandibular condyle and coronoid process as well as maxillary hypoplasia and micrognathia. The EACs are absent bilaterally. D, Axial CT image shows bilateral hypoplastic zygomatic arches, maxillary bone dysplasia, and temporal bone abnormalities.

small condylar necks with anterior placement of the condylar articulations, and increased distances between the EACs and the posterior glenoid fossa (Fig 2).²⁹ In some first-degree relatives of patients with ACS, the auricular malformations may be seen associated with macrognathia (type III malocclusion). Additional anomalies, somewhat specific to ACS, include a prominent bony ridge along the lateral aspect of the mandible (Fig 3). Reconstructive surgical techniques specific to ACS focus on functional improvement in mandibular excursion and the cosmetic appearance of the auricle.³⁰

TCS: OMIM 154500

TCS is a rare congenital disorder of craniofacial development that arises as the result of mutations in the *TCOF1* gene, which encodes a nucleolar phosphoprotein known as “Treacle.”³¹ The condition appears to have been first described by Thompson in 1846³²; however, TCS was given its eponym after E. Treacher Collins, who described the essential components of the condition in 1900.³³ The first extensive review of the condition was published by Franceschetti and Klein in 1949,³⁴ who first used the term “mandibulofacial dysostosis” and also identified its hereditary nature.

TCS is inherited in an autosomal dominant fashion with variable penetrance and phenotypic expression. It occurs in approximately 1 in 50,000 births. Forty percent of patients with TCS have a family history of the disease, and 60% of cases are seen sporadically.³⁵ Anomalous development in TCS is characterized by a combination of findings isolated to the head

and neck. Facial bone hypoplasia, involving the mandible and zygomatic complex in >75% of patients, is an extremely common feature of TCS. The maxilla may also be hypoplastic but sometimes can be seen as overprojecting. Other characteristic abnormalities include downward slanting of the palpebral fissures with notching of the lower eyelids and a scarceness of lid lashes medial to the defect.³⁵ The nose may be broad or protruding. Auricular anomalies include absent EAC, middle ear malformations, and pinna deformities. Craniofacial radiologic abnormalities include hypoplastic or aplastic zygomatic arches, choanal shortening, micrognathia and maxillary narrowing, or overprojection. CP is a common co-occurrence and may be severe. Craniofacial defects in TCS are often bilateral and relatively symmetric (Fig 4). Limb anomalies do not occur in TCS, which helps differentiate it from other syndromes that manifest with similar facial features.^{24,35–38}

Facial deformities are prioritized and addressed based on function and the basis for proper development. Surgical techniques have been described to address most of the anomalous development in TCS. Surgical correction of the zygoma, orbit, and mandible are usually not performed until the patient is 4–10 years of age. Auricular repair is often delayed until after 6 years of age to allow time for adequate costal cartilage development, which is harvested and used for successful reconstruction.^{39,40}

Stickler Syndrome: OMIM 108300

Stickler et al⁴¹ first described this autosomal dominant syndrome, also called hereditary progressive arthro-ophthalmop-

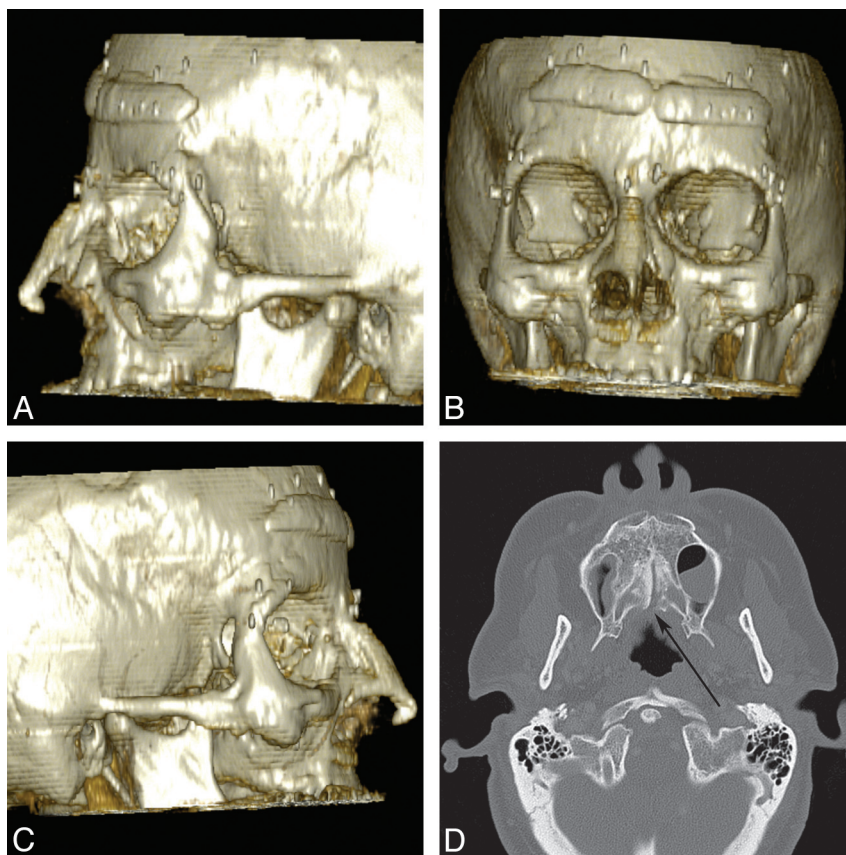


Fig 5. A 47-year-old woman with Stickler syndrome. A–C, 3D bony reconstructions show a flat midface with a depressed nasal bridge, short nose, anteverted nares, and zygomatic hypoplasia. Reconstructive and cosmetic hardware and implants are present. D, Axial CT scan shows incomplete fusion of the palatal bones with a posterior submucosal cleft (arrow).

athy, characterized by ocular and orofacial changes, arthritic changes, and deafness.⁴² The clinical picture is highly variable and sometimes confusing, with phenotypic features varying from dwarfism/marfanoid habitus to phenotypically healthy individuals. This variability can lead to diagnostic difficulties.^{42–44} Phenotypic variation can, in part, be explained by genetic heterogeneity, because the syndrome is often broken into 3 types based on mutations in different genes (type 1, *COL2A1*; type 2, *COL11A1*; and type 3, *COL11A2*). Despite the genotypic heterogeneity, the systemic features are similar for the different types. Diagnostic criteria have been proposed for type 1, comprising most patients with Stickler syndrome, which include molecular or family history data and characteristic ocular, orofacial, auditory, and musculoskeletal findings.⁴⁵

The most serious manifestations of the syndrome are ocular, including retinal detachment, high nonprogressive myopia, and vitreoretinal degeneration. These features may lead to eventual blindness.⁴⁶ Less common ophthalmologic features include perivascular pigmented lattice degeneration and cataracts.⁴² Nonocular features show high variability in expression. Enlarged joints, epiphyseal changes, and mild platyspondyly are typical of the disorder. Mild ligamentous laxity is seen early in life that occasionally leads to generalized ligamentous stiffness. Osteoarthritis typically develops in the third or fourth decade. Mild spondyloepiphyseal dysplasia is often apparent radiologically. Occasional findings include slender extremities and long fingers.^{43,45}

Patients with Stickler syndrome may have congenital sensorineural, congenital conductive, or acquired conductive hearing loss. The association with CP and a high arched palate leads to an increased incidence of serous otitis media, which may lead to conductive hearing loss. Defects of the auditory ossicles can be seen with associated congenital conductive hearing loss. Forty percent of patients show some evidence of sensorineural hearing loss, which in many patients may be clinically occult.^{42,44,47}

Radiographic evaluation of children with Stickler syndrome may reveal a flat midface with a depressed nasal bridge, short nose, anteverted nares, and micrognathia (Figs 5 and 6). These features can become less pronounced with age. Facial clefting is often seen and may range in severity from a cleft of the soft palate to a full PRS. Temporal bone evaluation can reveal ossicular chain abnormalities.⁴⁴ Prenatal detection of polyhydramnios and micrognathia with a family history of Stickler syndrome should be considered diagnostic of the syndrome and appropriate anticipatory care can be given before delivery.⁴⁸

VCFS: OMIM 192430

DiGeorge⁴⁹ first reported the association of the absence of the thymus with aplasia of the parathyroid glands. These observations were appreciated with variable anomalies of the cardiovascular system and craniofacial syndromes.¹⁶ Although there has been debate about the distinct etiologic nature of DiGeorge syndrome and VCFS, there is considerable phenotypic

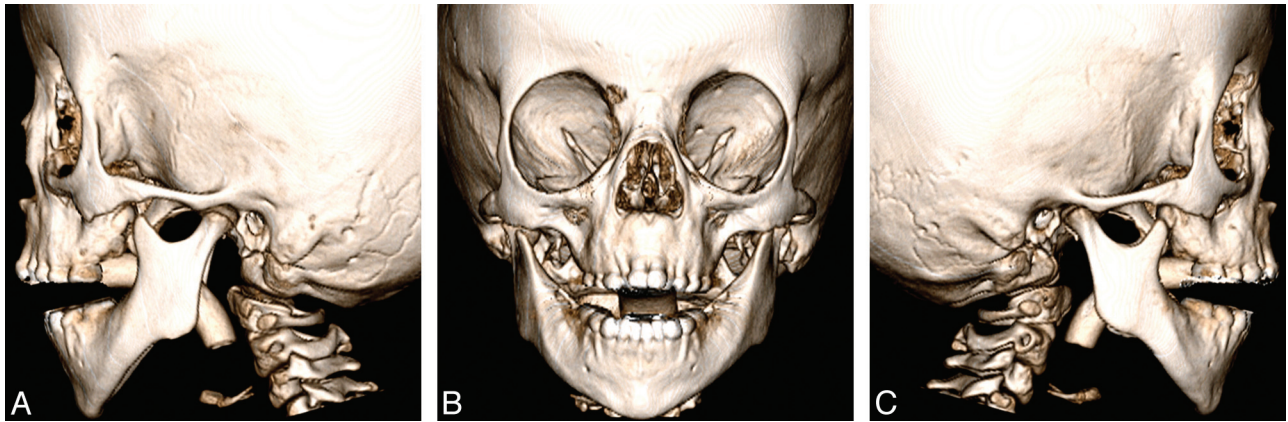


Fig 6. A 6-year-old boy with Stickler syndrome. 3D bony reconstructions show the characteristic flat midface with a depressed nasal bridge. The degree of zygomatic hypoplasia is more subtle. There is mild micrognathia. An endotracheal tube is present. Courtesy of Michael Cunningham.

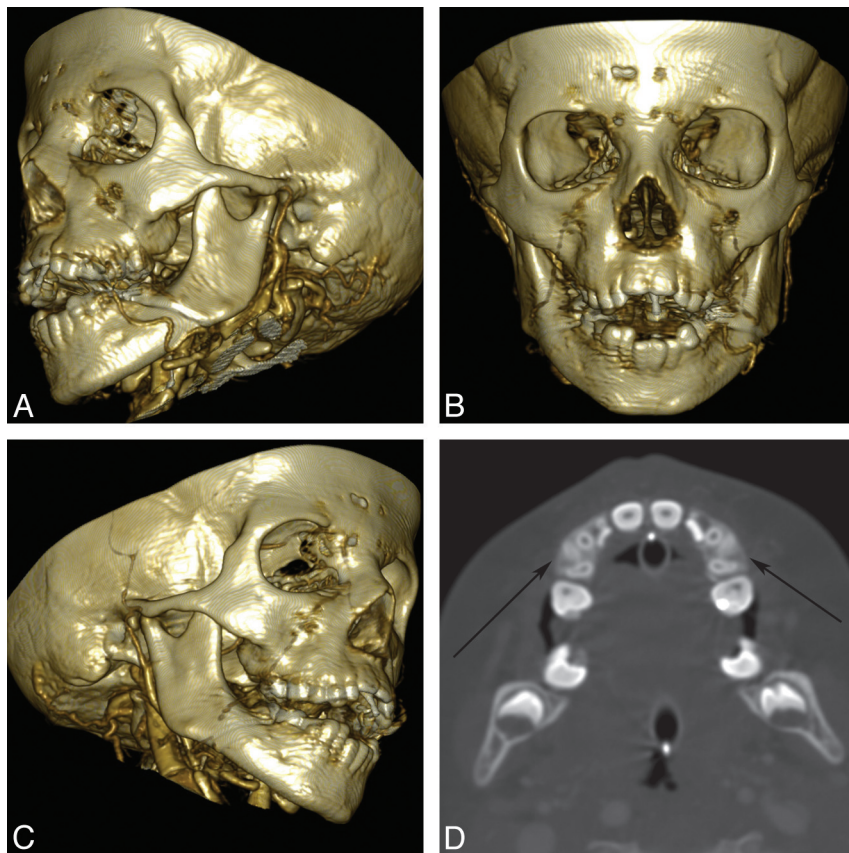


Fig 7. A 6-year-old boy with VCFS. A–C, 3D bone reconstructions show mild micrognathia with normal condyle and coronoid process morphology. D, Axial CT angiogram shows relatively symmetric micrognathia and areas of malocclusion (arrows).

and genotypic overlap. A 1.5- to 3.0-Mb hemizygous deletion of chromosome 22q11.2 causes VCFS.⁵⁰ This monoallelic microdeletion is considered the most common human deletion syndrome.⁵¹ DiGeorge syndrome has been shown to share a genetic defect with VCFS in 45%- 85% of cases in different series.^{16,52}

VCFS consists of CP, cardiac anomalies, typical facies, and learning disabilities. In a recent study, cortical areas of reduced gyration were observed, further substantiating the pattern of cerebral alterations presented with the syndrome.⁵³ Almost all

individuals with 22q11 deletion syndrome have behavior and/or learning problems, with >40% meeting the criteria for either autism spectrum disorder, attention deficit/hyperactivity disorder, or both. More than half of patients, in some series, meet the criteria for mental retardation.⁵⁴ Less frequent features include microcephaly, short stature, slender hands and digits, minor auricular anomalies, and inguinal hernia. Skeletal anomalies are not uncommon.⁵⁵ VCFS is the most frequent clefting syndrome, accounting for approximately 8.1% of children with palatal clefts seen in some centers.⁵⁶ Cardiac anom-

alies have been described in 82% of patients, including isolated ventricular septal defect and tetralogy of Fallot.⁵⁷

Two emergent clinical situations may arise in children with VCFS on the basis of the variable associated defects of the third and fourth BAs. The first is tetany, which can be sudden and fatal, due to hypocalcemia relating to aplasia of the parathyroids.⁵⁸ Although the absence of parathyroid gland function is rare, parathyroid dysfunction is present in approximately half of patients with VCFS.⁵⁹ The second emergent situation is related to infections from deficiencies with the T-cell-mediated response of the immune system due to an absent or hypoplastic thymus. Immunologic evaluation is critical in affected children to identify those that may require either lymphocyte or thymus transplantation.⁶⁰ Both of these situations require special care of patients who may require cardiac surgery.⁵⁸

Radiographic evaluation of a patient with suspected VCFS is multifaceted because the radiologist may be called on to evaluate the central nervous system, craniofacial structures, cardiothoracic contents, or the musculoskeletal system. Focus on the craniofacial system should include an evaluation for PRS, EAC stenosis, prominent nose, thin upper lip, and asymmetric facies (Fig 7). The adenoids are typically hypoplastic, and middle ear anomalies are also sometimes seen. An aberrant course of the internal carotid arteries is often seen, and contrast-enhanced CT is often requested for surgical planning involving the head and neck.

Conclusions

The first and second BAs are the embryologic origin of many of the structures of the face. A wide variety of congenital conditions may arise from their contents. A knowledge of the anatomic formation of this region is important in understanding abnormalities in development, which in turn aids in formulation of precise diagnoses and differential diagnostic considerations.

Acknowledgments

We thank Michael Cunningham, MD, PhD, for his assistance with manuscript preparation.

References

- Marsh JL. *Comprehensive Care for Craniofacial Deformities*. St. Louis, Missouri: Mosby; 1985
- Robin P. La chute de la base de la langue consideree comme une nouvelle cause de gene dans la respiration nasopharyngienne. *Bull Acad de Med* 1923;89:37–41
- Robin P. *La Glossoptose: Un Grave Danger Pour Nos Enfants*. Paris, France: Gaston Doin; 1929
- Robin P. Glossoptosis due to atresia and hypotrophy of the mandible. *Am J Dis Child* 1934;48:541
- Figuerola AA, Glupker TJ, Fitz MG, et al. Mandible, tongue, and airway in Pierre Robin sequence: a longitudinal cephalometric study. *Cleft Palate Craniofac J* 1991;28:425–34
- Caouette-Laberge L, Bayet B, Larocque Y. The Pierre Robin sequence: review of 125 cases and evolution of treatment modalities. *Plast Reconstr Surg* 1994;93:934–42
- Smith JL, Stowe FR. The Pierre Robin Syndrome (glossoptosis, micrognathia, cleft palate): a review of 39 cases with emphasis on associated ocular lesions. *Pediatrics* 1961;27:128–33
- Hermann NV, Kreiborg S, Darvann TA, et al. Early craniofacial morphology and growth in children with nonsyndromic Robin sequence. *Cleft Palate Craniofac J* 2003;40:131–43
- van den Elzen AP, Semmekrot BA, Bongers EM, et al. Diagnosis and treatment of the Pierre Robin sequence: results of a retrospective clinical study and review of the literature. *Eur J Pediatr* 2001;160:47–53
- Caffey J. *Pediatric X-Ray Diagnosis: Textbook for Students and Practitioners of Pediatrics, Surgery and Radiology*. Chicago: Year Book Medical Publishers; 1978
- David DJ, Mahatmarat C, Cooter RD. Hemifacial microsomia: a multisystem classification. *Plast Reconstruct Surg* 1987;80:525–35
- Rollnick BR, Kaye CI. Hemifacial microsomia and variants: pedigree data. *Am J Med Genet A* 1983;15:233–53
- Gorlin RJ, Jue KL, Jacobsen U, et al. Oculoauriculovertebral dysplasia. *J Pediatr* 1963;63:991–99
- Goldenhar M. Associations malformatives de l'oeil et de l'oreille, en particulier le syndrome dermoide epibulbaire-appendices auriculaires-fistula auris congenita et ses relations avec la dysostose mandibulo-faciale. *J Genet Human* 1952;1:243–82
- Cohen MM Jr, Rollnick BR, Kaye CI. Oculoauriculovertebral spectrum: an updated critique. *Cleft Palate J* 1989;26:276–86
- Gorlin RJ, Cohen MM, Hennekam RCM. *Syndromes of the Head and Neck*. Oxford, UK: Oxford University Press; 2001
- Horgan JE, Padwa BL, LaBrie RA, et al. OMENS-Plus: analysis of craniofacial and extracraniofacial anomalies in hemifacial microsomia. *Cleft Palate Craniofac J* 1995;32:405–12
- Jongbloet PH. Goldenhar syndrome and overlapping dysplasias: in vitro fertilisation and ovopathy. *J Med Genet* 1987;24:616–20
- Som PM, Curtin HD. *Head and Neck Imaging*. St. Louis: Mosby; 2003
- Vento AR, LaBrie RA, Mulliken JB. The O.M.E.N.S. classification of hemifacial microsomia. *Cleft Palate Craniofac J* 1991;28:68–76, discussion 77
- Kitai N, Murakami S, Takashima M, et al. Evaluation of temporomandibular joint in patients with hemifacial microsomia. *Cleft Palate Craniofac J* 2004;41:157–62
- Cosman B, Bellin H, Crikelair GF. The question mark ear. *Plast Reconstruct Surg* 1970;46:454–57
- Al-Qattan MM. Cosman (question mark) ear: congenital auricular cleft between the fifth and sixth hillocks. *Plast Reconstruct Surg* 1998;102:439–41
- Passos-Bueno MR, Ormelas CC, Fanganiello RD. Syndromes of the first and second pharyngeal arches: a review. *Am J Med Genet A* 2009;149A:1853–59
- Shkalim V, Eliaz N, Linder N, et al. Autosomal dominant isolated question mark ear. *Am J Med Genet A* 2008;146A:2280–83
- Gerkes EH, van Ravenswaaij CM, van Essen AJ. Question mark ears and post-auricular tags. *Euro J Med Genet* 2008;51:264–67. Epub 2008 Jan 30
- Masotti C, Oliveira KG, Poerner F, et al. Auriculo-condylar syndrome: mapping of a first locus and evidence for genetic heterogeneity. *Eur J Hum Genet* 2008;16:145–52
- Guion-Almeida ML, Zechi-Ceide RM, Vendramini S, et al. Auriculo-condylar syndrome: additional patients. *Am J Med Genet A* 2002;112:209–14
- Storm AL, Johnson JM, Lammer E, et al. Auriculo-condylar syndrome is associated with highly variable ear and mandibular defects in multiple kindreds. *Am J Med Genet A* 2005;138:141–45
- Ozturk S, Sengezer M, Isik S, et al. The correction of auricular and mandibular deformities in auriculo-condylar syndrome. *J Craniofac Surg* 2005;16:489–92
- Positional cloning of a gene involved in the pathogenesis of Treacher Collins syndrome: The Treacher Collins Syndrome Collaborative Group. *Nat Genet* 1996;12:130–36
- Thomson A. Notice of several cases of malformation of the external ear, together with experiments on the state of hearing in such persons. *Edinburgh Journal of Medical Science* 1847;76:420–25 and 730–40
- Collins ET. Cases with symmetrical congenital notches in the outer part of each lid and defective development of the malar bones. *Trans Ophthalmol Soc UK* 1900;20:190–92
- Franceschetti A, Klein D. The mandibulofacial dysostosis; a new hereditary syndrome. *Acta Ophthalmologica* 1949;27:143–224
- Dixon MJ. Treacher Collins syndrome. *J Med Genet* 1995;32:806–08
- Trainor PA, Dixon J, Dixon MJ. Treacher Collins syndrome: etiology, pathogenesis and prevention. *Eur J Hum Genet* 2009;17:275–83
- Fuente del Campo A, Martinez Elizondo M, Arnaud E. Treacher Collins syndrome (mandibulofacial dysostosis). *Clin Plast Surg* 1994;21:613–23
- Lowe LH, Booth TN, Joglar JM, et al. Midface anomalies in children. *Radiographics* 2000;20:907–22, quiz 1106–1107, 1112
- Roddi R, Vaandrager JM, van der Meulen JC. Treacher Collins syndrome: early surgical treatment of orbitomalar malformations. *J Craniofac Surg* 1995;6:211–17
- van der Meulen JC, Hauben DJ, Vaandrager JM, et al. The use of a temporal osteoperiosteal flap for the reconstruction of malar hypoplasia in Treacher Collins syndrome. *Plast Reconstruct Surg* 1984;74:687–93
- Stickler GB, Belau PG, Farrell FJ, et al. Hereditary progressive arthro-ophthalmopathy. *Mayo Clin Proc* 1965;40:433–55
- Snead MP, Yates JR. Clinical and molecular genetics of Stickler syndrome. *J Med Genet* 1999;36:353–59
- Zechi-Ceide RM, Jesus Oliveira NA, Guion-Almeida ML, et al. Clinical evaluation and COL2A1 gene analysis in 21 Brazilian families with Stickler syndrome: identification of novel mutations, further genotype/phenotype

- correlation, and its implications for the diagnosis. *Euro J Med Genet* 2008;51:183–96
44. Temple IK. **Stickler's syndrome.** *J Med Genet* 1989;26:119–26
 45. Rose PS, Levy HP, Liberfarb RM, et al. **Stickler syndrome: clinical characteristics and diagnostic criteria.** *Am J Med Genet A* 2005;138A:199–207
 46. Yokoi T, Koide R, Matsuoka K, et al. **Analysis of the vitreous membrane in a case of type 1 Stickler syndrome.** *Graefes Arch Clin Exp Ophthalmol* 2009;247:715–18, Epub 2008 Dec 17
 47. Szymko-Bennett YM, Mastroianni MA, Shotland LI, et al. **Auditory dysfunction in Stickler syndrome.** *Arch Otolaryngol Head Neck Surg* 2001;127:1061–68
 48. Soulier M, Sigaudy S, Chau C, et al. **Prenatal diagnosis of Pierre-Robin sequence as part of Stickler syndrome.** *Prenat Diagn* 2002;22:567–68
 49. DiGeorge AM. **Discussion on a new concept of the cellular basis of immunology.** *J Pediatr* 1965;67:907
 50. Ryan AK, Goodship JA, Wilson DI, et al. **Spectrum of clinical features associated with interstitial chromosome 22q11 deletions: a European collaborative study.** *J Med Genet* 1997;34:798–804
 51. Oskarsdottir S, Vujic M, Fasth A. **Incidence and prevalence of the 22q11 deletion syndrome: a population-based study in Western Sweden.** *Arch Dis Child* 2004;89:148–51
 52. Rope AF, Cragun DL, Saal HM, et al. **DiGeorge anomaly in the absence of chromosome 22q11.2 deletion.** *J Pediatr* 2009;155:560–65
 53. Schaer M, Glaser B, Cuadra MB, et al. **Congenital heart disease affects local gyrification in 22q11.2 deletion syndrome.** *Dev Med Child Neurol* 2009;51:746–53, Epub 2009 Mar 9
 54. Niklasson L, Rasmussen P, Oskarsdottir S, et al. **Autism, ADHD, mental retardation and behavior problems in 100 individuals with 22q11 deletion syndrome.** *Res Dev Disabil* 2009;30:763–73
 55. Ming JE, McDonald-McGinn DM, Megerian TE, et al. **Skeletal anomalies and deformities in patients with deletions of 22q11.** *Am J Med Genet A* 1997;72:210–15
 56. Shprintzen RJ, Goldberg RB, Lewin ML, et al. **A new syndrome involving cleft palate, cardiac anomalies, typical facies, and learning disabilities: velo-cardio-facial syndrome.** *Cleft Palate J* 1978;15:56–62
 57. Carotti A, Digilio MC, Piacentini G, et al. **Cardiac defects and results of cardiac surgery in 22q11.2 deletion syndrome.** *Dev Disabil Res Rev* 2008;14:35–42
 58. Jatana V, Gillis J, Webster BH, et al. **Deletion 22q11.2 syndrome: implications for the intensive care physician.** *Pediatr Crit Care Med* 2007;8:459–63, quiz 464
 59. Hieronimus S, Bec-Roche M, Pedoutour F, et al. **The spectrum of parathyroid gland dysfunction associated with the microdeletion 22q11.** *Eur J Endocrinol* 2006;155:47–52
 60. Sullivan KE. **Chromosome 22q11.2 deletion syndrome: DiGeorge syndrome/velocardiofacial syndrome.** *Immunol Allergy Clin North Am* 2008;28:353–66