



Get Clarity On Generics

Cost-Effective CT & MRI Contrast Agents



FRESENIUS
KABI

WATCH VIDEO

AJNR

High-resolution CT of the petrous bone: direct vs. Reformatted images.

P Turski, D Norman, J DeGroot and R Capra

AJNR Am J Neuroradiol 1982, 3 (4) 391-394

<http://www.ajnr.org/content/3/4/391.citation>

This information is current as
of August 22, 2025.

High-Resolution CT of the Petrous Bone: Direct vs. Reformatted Images

Patrick Turski^{1,2}
David Norman¹
Jack DeGroot³
Richard Capra¹

Coronal and sagittal reformatted images generated from axial Target scans through the temporal bone compared favorably with direct scans of cadaver specimens. Oblique reformatted images exhibited significant degradation and did not appear to be helpful in identifying anatomic structures. In patients with suspected temporal bone tumors, Target reconstruction of axial scans followed by coronal and sagittal reformation has proved useful.

High-resolution computed tomography (CT) coupled with an alternate algorithm (Target reconstruction) capable of producing high spatial resolution and extended window viewing enables visualization of structures within the middle ear [1-3]. Previously, many disease processes could only be evaluated by complex motion tomography, and various planes of section were developed to optimally visualize the structures of interest. Computer software programs (GEDIS) can create similar images by reformatting axial CT data into the desired plane. The purpose of our investigation was to compare direct versus reformatted images of the temporal bone and to determine whether multiple planes are still necessary for the evaluation of temporal bone pathology.

Materials and Methods

A spatial resolution phantom, two cadaver specimens, and four patients with clinically suspected temporal bone pathology were scanned using a GE CT/T 8800 scanner, 1.5 mm collimation, and a 25 cm elliptical field of view. All scans were target-reconstructed at 3.2 or 5.0 magnification employing the Hardbone Retrospective Review algorithm available from General Electric. The target images were displayed with an extended range of CT numbers at a window width of 4,000 Hounsfield units (H). Target images were reformatted in the desired planes by means of the General Electric software program, GEDIS. A slice thickness of 2 pixels was employed, and the plane of interest was indicated with a cursor.

The spatial resolution phantom consisted of a Lucite cube in which a series of cylindrical holes, decreasing in size, had been drilled. The cylindrical holes ranged from 15 to 0.5 mm in diameter. The phantom was scanned in two planes: perpendicular (coronal) and parallel (axial) to the long axis of the holes. Reformatted target images of the 1 and 0.5 mm holes were generated using both sets of data.

Two formalin-fixed cadaver heads were scanned in the axial plane. Direct scans were also obtained in the coronal, sagittal, Guillen, and Stenvers projections. The axial target images were then reformatted in the coronal, sagittal, Guillen, and Stenvers planes. The direct target images were compared with the reformatted target images for anatomic detail and image quality.

Four patients with clinically suspected temporal bone pathology were scanned in the axial and direct coronal planes. The axial target images were reformatted into coronal, sagittal, and oblique planes. The reformatted images were analyzed for the presence of clinically useful information that could not be detected easily on direct target images.

Received October 9, 1981; accepted after revision February 10, 1982.

Presented at the annual meeting of the American Society of Neuroradiology, Chicago, March 1981.

¹ Department of Radiology, University of California, San Francisco, CA 94143.

² Present address: Department of Radiology, University of Wisconsin, Clinical Science Center, 600 Highland Ave., Madison, WI 53792. Address reprint requests to P. Turski.

³ Department of Anatomy, University of California, San Francisco, CA 94143.

AJNR 3:391-394, July/August 1982
0195-6108/82/0304-0391 \$00.00

© American Roentgen Ray Society

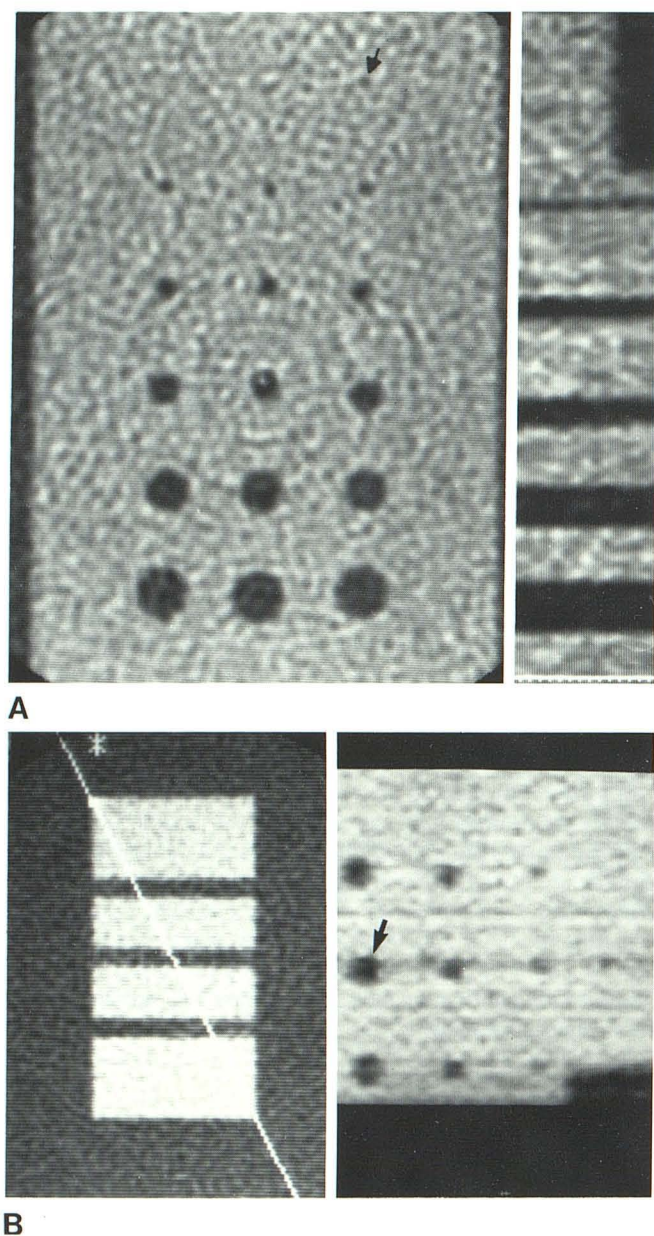


Fig. 1.—Direct and reformatted images of spatial resolution phantom. **A**, Left. Target scan in coronal plane perpendicular to axis of cylindrical holes. Plane of reformation (arrow). **A**, Right. Sagittal reformatted image demonstrates series of cylindrical holes increasing in size. **B**, Left. Target scan in plane parallel to long axis of holes (axial). Three 5 mm cylindrical holes are displayed. White cursor line indicates oblique plane transecting phantom. **B**, Right. Oblique reformatted image demonstrates distortion of even largest holes (arrow).

Results

In the spatial resolution phantom, the 1 mm holes were clearly identified in both cross section and along their horizontal axis. The 0.5 mm holes were barely discernible on the direct target images. Although the 1 mm holes could be easily discriminated on the reformatted images, the 0.5 mm holes could not be identified. Oblique reformatted images

(General Electric software program GEDIS) produced significant distortion of the holes and edge sharpness diminished (fig. 1).

The reformatted coronal and sagittal target images from cadaver specimens exhibited minimal image degradation and compared favorably with the direct target images (fig. 2). Degradation was more pronounced for anatomic structures that lay in a plane relatively oblique to the plane of reformation. Degradation was more marked in the specimens than in the phantom, primarily because the phantom was composed of linear structures. In the oblique planes, a marked difference was observed. Anatomic detail of the direct Guillen and Stenvers target images was far superior to reformatted Guillen and Stenvers target images (fig. 2). Neither direct nor reformatted oblique images added significant anatomic information to justify their routine use in CT evaluation of the temporal bone. Anatomic structures (osseous and soft tissue) could be easily identified in the axial, coronal, and sagittal images.

Three patients with tumors (acoustic neuroma, cholesteatoma, and glomus jugulare) and one patient with a temporal bone fracture were scanned in the axial plane with supplemental coronal and sagittal image reformation. Axial target images with reformatted coronal and sagittal target images were adequate for the diagnosis and surgical planning for the three patients with tumors (figs. 3A and 3B). In the patient in whom bone detail was the critical issue (i.e., fracture), direct scans were necessary to adequately demonstrate the fracture line (fig. 3C).

Discussion

Target reconstruction (Hardbone Retrospective Review) improves spatial resolution by decreasing the pixel size and using different convolutional filters [2]. The "raw" scan data may be reprocessed at any magnification factor yielding a high-resolution reconstruction of a selected portion of scan data. Spatial resolution approaches 0.5 mm, as demonstrated in our target images of the phantom.

Multipanar reformatted images have proved useful in the evaluation of the lumbar spine [4], orbital lesions, and in the localization of intracranial neoplastic processes. We found the coronal and sagittal reformatted images of the temporal bone approached but did not equal the quality of the direct scans. In the clinical setting, direct coronal scans are easily obtainable, but sagittal images of the temporal bone can only be obtained by means of computer manipulation of the axial or coronal data. The sagittal images were useful in the diagnosis and management of important clinical problems, such as the analysis of cholesteatoma extension and the extent of bone destruction from a glomus jugulare tumor.

Oblique images were not found to be helpful, primarily due to degradation of the images. Oblique images were affected by several problems inherent in the display of small objects on a digital matrix. Along the edges of small structures, the surface appeared ragged or "stair-cased." When oblique reformations are made with only 1 pixel thickness there are problems with sampling frequency and holes ap-

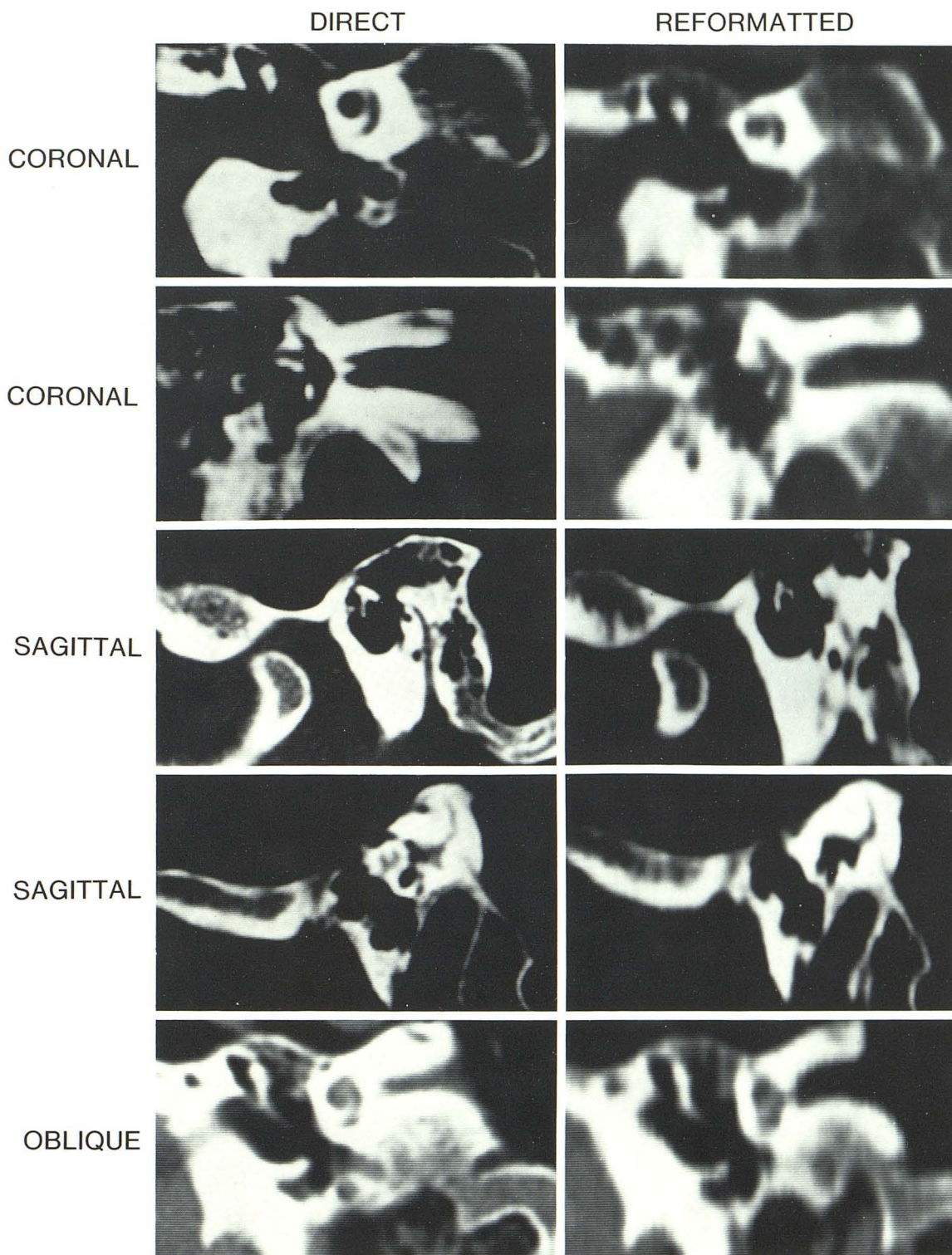
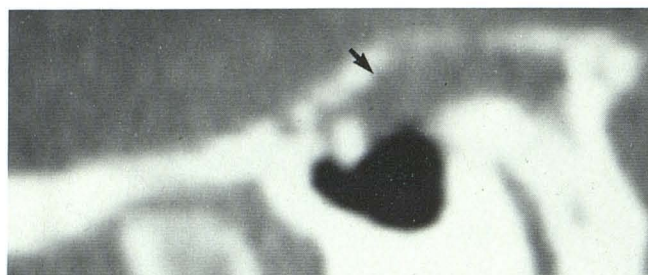

Fig. 2.—Direct and reformatted images of cadaver specimens.

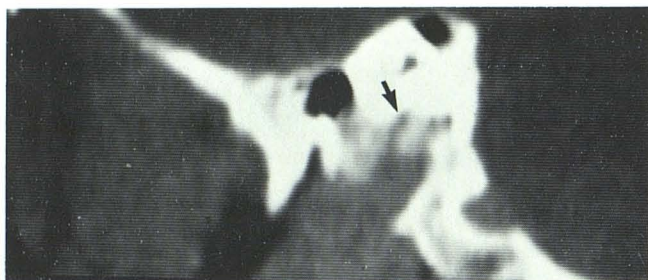pear in the image, since some pixels are written over their neighbors ("aliasing"). Increasing the thickness of the slice to 2 pixels increases sampling rates and improves image data resolution. Another problem is the transection of a

digital cube by an oblique plane. Adjacent pixels may only share a common edge and a "rough" surface is produced [5].

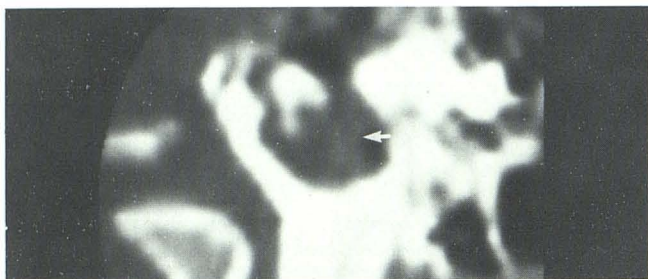In conclusion, our experience suggests that patients with



A



B



C

Fig. 3.—Reformatted sagittal images. A, Surgically-proven cholesteatoma (arrow). B, Glomus jugulare tumor. Bone destruction (arrow). C, Temporal bone fracture. Blood visible within middle ear (arrow). Fracture line cannot be identified.

suspected temporal bone tumors may be efficiently evaluated by Target reconstruction of axial scans followed by coronal and sagittal reformations, thus eliminating the need for a second series of direct coronal scans. In situations where bone detail is the primary concern, direct coronal scans are still necessary. Oblique images corresponding to classical geometric tomographic planes have not proved to be useful.

REFERENCES

1. Shaffer KA, Haughton VM, Wilson CR. High resolution computed tomography of the temporal bone. *Radiology* 1980;134:409-414
2. Shaffer KA, Volz DS, Haughton VM. Manipulation of CT data for temporal-bone imaging. *Radiology* 1980;137:825-829
3. DeSmedt E, Potvliege R, Pimontel-Appel B, et al. High resolution CT-scan of the temporal bone: a preliminary report. *J Belge Radiol* 1980;63:205-212
4. Glen WV, Rhodes ML, Altschuler EM, Wiltse LL, Kostanek C, Kuo YM. Multiplanar display of computerized body tomography applications in the lumbar spine. *Spine* 1979;4:282-352
5. Rhodes ML, Glen WV, Azzawi YM. Extracting oblique planes from serial CT sections. *J Comput Assist Tomogr* 1980;4:649-657