



## Get Clarity On Generics

Cost-Effective CT & MRI Contrast Agents



FRESENIUS  
KABI

WATCH VIDEO

# AJNR

## Vertebroplasty in Multiple Myeloma: Outcomes in a Large Patient Series

R.J. McDonald, A.T. Trout, L.A. Gray, A. Dispenzieri, K.R. Thielen and D.F. Kallmes

*AJNR Am J Neuroradiol* 2008, 29 (4) 642-648

doi: <https://doi.org/10.3174/ajnr.A0918>

<http://www.ajnr.org/content/29/4/642>

This information is current as  
of August 11, 2025.

## ORIGINAL RESEARCH

R.J. McDonald  
A.T. Trout  
L.A. Gray  
A. Dispenzieri  
K.R. Thielen  
D.F. Kallmes

# Vertebroplasty in Multiple Myeloma: Outcomes in a Large Patient Series

**BACKGROUND AND PURPOSE:** Despite the literature supporting the efficacy of vertebroplasty for treatment of osteoporotic vertebral compression fractures, few reports exist documenting its use in the treatment of compression fractures in multiple myeloma patients. Accordingly, we sought to characterize the imaging characteristics, clinical course, and outcomes in myeloma patients treated with vertebroplasty.

**MATERIALS AND METHODS:** We performed a retrospective review of clinical outcome data from 67 multiple myeloma patients treated with vertebroplasty since October 2000. Quantitative outcome data including the Roland Morris Disability Questionnaire (RDQ) and Visual Analog Scales for pain and qualitative outcome data (self-reported pain, mobility, and narcotic use) were collected preoperatively, immediately after vertebroplasty, and at 1 week, 1 month, 6 months, and 1 year after treatment.

**RESULTS:** Significant improvements in all of the outcome measures were observed postoperatively and throughout the duration of follow-up. Quantitative outcome measures (RDQ, analog pain scale 0–10, with rest and activity) improved by 11.0 (48%;  $P < .0001$ ), 2.7 (25%;  $P < .001$ ), and 5.3 (48%;  $P < .0001$ ) points, respectively, with persistent improvement at 1 year ( $P < .01$ ;  $P < .03$ ;  $P < .001$ ). Eighty-two percent and 89% of patients experienced a significant improvement in subjective rest pain and activity pain, respectively. Subjective scores achieved durable improvements, with 65% of patients requiring fewer narcotics after vertebroplasty and 70% having improved mobility.

**CONCLUSION:** Vertebroplasty provides significant and durable pain relief for patients with intractable spinal pain secondary to compression fractures resulting from multiple myeloma.

Percutaneous vertebroplasty, initially conceived and developed in Europe for use in painful spinal compression fractures of malignant etiology,<sup>1–4</sup> has predominantly been used in the United States for treatment and palliation of painful benign vertebral compression fractures secondary to osteoporosis. The rapid adoption and use of the procedure are, in part, due to the enormous success of this treatment in conferring rapid and long-lasting improvements in pain and mobility.<sup>5,6</sup>

Patients with multiple myeloma are at high risk for vertebral compression fracture, and use of vertebroplasty is expanding into this patient population.<sup>1–4</sup> Myeloma patients are susceptible to compression fractures due to osteoporosis, which results from both the molecular pathophysiology of their disease and frequent use of corticosteroids in the medical management of their disease. Most myeloma patients have both diffuse and focal bone involvement due to direct invasion by myeloma cells. In addition, a cytokine-mediated imbalance of osteoclast (bone resorption) and osteoblast (rebuilding) function leads to systemic osteoporosis and spontaneous fracture.

Although many large prospective studies demonstrating the efficacy of vertebroplasty in the treatment of benign vertebral compression fractures have been published,<sup>1,4,5,7–16</sup> the data supporting its use in the treatment of compression fractures in patients with multiple myeloma remain limited. Several small studies and case series have demonstrated a benefi-

cial effect,<sup>1,2,17–31</sup> but the largest sample size is composed of only 18 patients. Many barriers prevent the accumulation of a large patient cohort in the myeloma population, and these include reduced survival time of myeloma patients, the relative rarity of vertebroplasty treatment in myelomatous fractures, and a higher threshold of treatment criteria for patients with diffuse disease. In addition, some of these reports did not fully quantify postprocedural improvements in clinical outcomes, such as pain and mobility, making it difficult to assess the efficacy of vertebroplasty in their study population. In an effort to address concerns and limitations of small sample size and to better quantify the efficacy of vertebroplasty in the myeloma population, we describe a retrospective study of 67 patients with pathologic and radiographic evidence of multiple myeloma who underwent vertebroplasty with follow-up after treatment of 1 year to assess the change(s) in pain, mobility, and function.

## Methods

We performed a retrospective analysis of 67 patients with multiple myeloma within our pool of more than 800 study participants who were treated with vertebroplasty between October 2000 and March 2007. Three of these patients have been included in a previous report not specifically related to their disease process.<sup>10</sup> Institutional review board (IRB) approval was obtained for this study, and all of the pertinent data and records were handled in a manner consistent with Health Insurance Portability and Accountability Act guidelines. Data included in this study were limited to the first vertebroplasty procedure in a given patient with a biopsy-proven diagnosis of multiple myeloma, plasmacytoma, or plasma cell-proliferative disease. This was done to limit the potential confounding effects of recurrent fracture and treatment. Eighteen patients were disqualified from vertebroplasty based on the following criteria: 1) lack of compression fracture, 2) improvement with conservative management, 3) technical

Received September 12, 2007; accepted after revision October 29.

From the Medical Scientist Training Program (R.J.M.), Mayo Clinic College of Medicine (R.J.M., A.D., K.R.T., D.F.K.), Mayo Clinic, Rochester, Minn; Department of Radiology (A.T.T.), University of Michigan, Ann Arbor, Mich; Departments of Radiology (L.A.G., K.R.T., D.F.K.) and Hematology (A.D.), Mayo Clinic, Rochester, Minn.

Please address correspondence to David F. Kallmes, Mayo Clinic, Department of Radiology, 200 1st St SW, Rochester, MN 55905; e-mail: kallmes.david@mayo.edu

DOI 10.3174/ajnr.A0918

contraindications, or 4) noncorrelating pain to avoid confounding outcome effects in the data analysis. In patients with multiple fractures, identification of painful levels was done by both physical examination and imaging. Pain on palpation and/or marrow edema within the vertebral body were used to target which levels to treat with vertebroplasty.

Treatment data, including procedure dates, diagnosis dates, approximate onset of symptoms, procedural data, and procedural notes, including radiologic interpretations, were obtained from archived institutional electronic medical records. Outcome data were retrieved from a single IRB-approved electronic vertebroplasty database composed of approximately 800 patients treated at our medical center since the study inception in 1999. Responses from study participants had previously been collected in person (for immediate prevertebroplasty and postvertebroplasty responses) and over the telephone (for follow-up at 1 week, 1 month, 6 months, and 1 year after treatment).

### Diagnostic Evaluation

The diagnosis of myeloma or plasmacytoma was made by using standard clinical criteria.<sup>32</sup> Radiographic evaluation of myeloma patients consisted primarily of MR imaging supplemented with CT imaging and/or bone radiographs for osteoporotic involvement. Electronic archives of the primary imaging results and radiologic interpretations were reviewed by experienced staff radiologists for this study (including K.R.T. and D.F.K.). MR imaging of 66 of the 67 patients, by using appropriate spin-echo enhancement and signal intensity-suppression techniques to enhance malignant marrow lesions, was assessed for typical radiologic criteria (eg, low T1-weighted signal intensity and high T2-weighted signal intensity) and pattern of spinal involvement. In an effort to characterize the nature of the treated compression fractures, preoperative MR images were assessed to group the fractures into 3 categories. Type 1 compression fractures were classified by using the following morphologies: 1) at least some portion of the vertebral body with normal-appearing fatty marrow; 2) no evidence of pedicle involvement or epidural or paraspinal disease; and 3) absence of focal or diffusely abnormal marrow signal intensity from treated vertebral body (may or may not have been present in other vertebrae). Type 2 compression fractures were considered indeterminate for underlying lesion and were classified as follows: diffusely low T1 marrow signal intensity of the treated vertebral body with no evidence of normal, high T1, signal intensity and absence of paraspinal disease that would suggest underlying focal lesion. Type 3 compression fractures were defined with the following characteristics: MR evidence of underlying lesions with obvious focal involvement and pedicle involvement, paraspinal disease, and/or epidural disease. The appearance of adjacent or surrounding marrow from the treated vertebrae had no impact on these categories. We also characterized MR findings in vertebral bodies separate from the treated vertebra as follows<sup>33</sup>: (grade 1) presence of fracture, no vertebral lesions (ie, normal appearing bone); (grade 2) presence of fracture, 1 or several focal vertebral lesions consistent with myeloma (<10 lesions); or (grade 3) presence of fracture, diffuse vertebral bone marrow involvement (>10 lesions).

### Vertebroplasty Procedure

Vertebroplasties were performed by 7 experienced staff radiologists at our medical center using methods as described previously.<sup>16</sup> Intravenous conscious sedation and regional local anesthesia for superficial and deep tissues of the targeted spinous pedicle(s) were used as necessary. Needle trajectory, advancement, and guidance were moni-

tored using biplanar fluoroscopy. Polymethylmethacrylate (PMMA) cement was prepared as described previously.<sup>3,16</sup> Cement injection was terminated when the PMMA level approached the posterior one fourth of the vertebral body as visualized on the lateral projection or in any case when epidural, venous, or transendplate extravasation was observed. After needle removal, patients were discharged after 1 hour of strict bed rest.

### Outcome Measures

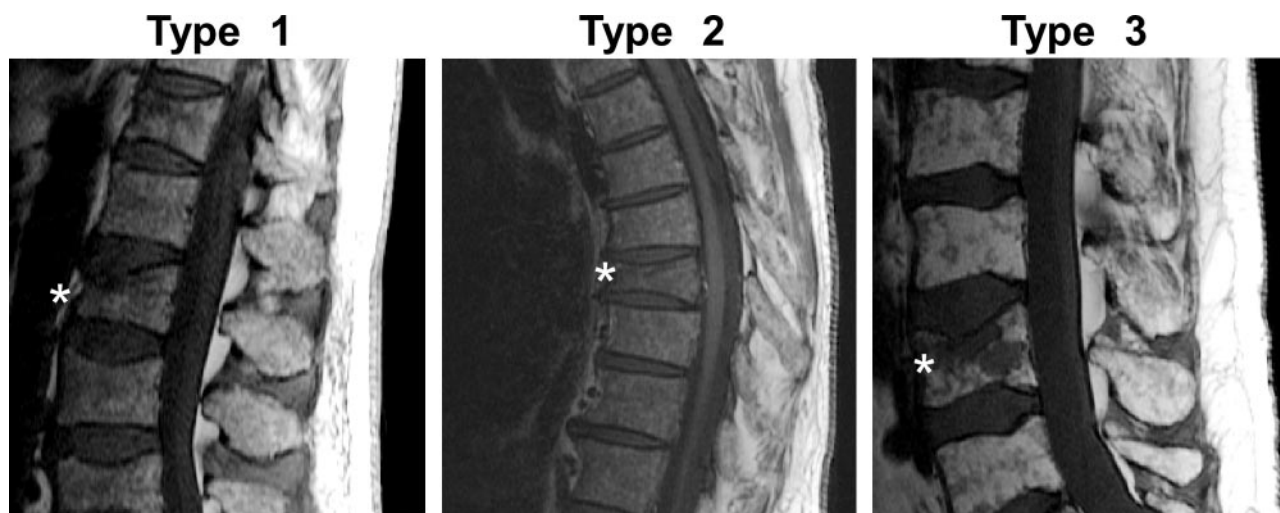
Quantitative outcome measures, including the Roland-Morris Disability Questionnaire (RDQ; graded 1–23 as described previously<sup>34–36</sup>) and derivatives of the Visual Analog Scales for “pain at rest” and “pain with activity” (analog pain scale, graded 0–10), were collected at each time point by trained nurses in the hospital (preoperatively and postoperatively) and over the phone (later time points, 1 week, 1 month, 6 months, and 1 year). In addition, qualitative measures of clinical outcome (mobility change, narcotic medication use, and pain improvement) were similarly collected. Qualitative outcomes after vertebroplasty were numerically transformed for analysis as follows: complete resolution (+2), improvement (+1), no change (0), and worse than before procedure (–1). Responses for each numerically transformed qualitative measure were averaged at each time point to approximate the qualitative change in response relative to other time points. Patients who were unable to be reached by phone, after 3 attempts, were designated as nonrespondents for that specific time point. Nonrespondent status of a patient at a given time point did not exclude the patient from contact at a later time point unless the patient no longer wished to participate in the study.

### Statistical Analysis

Continuous and ordinal datasets are presented as continuous range data, whereas nominal data are presented as discrete percentage data. Pairwise nonparametric correlations between continuous datasets were interpreted by using Spearman Rho coefficient, whereas nonparametric pairwise correlations between nominal and continuous datasets were analyzed by using the Wilcoxon rank-sum test. Significance was estimated by *P* values (eg, the probability that 2 observations are not meaningfully different), reported at or below the fifth percentile. Confidence intervals were presented at the 95th percentile in all of the cases. Statistical analyses were performed by using JMP version 6.0 software (SAS Institute, Cary, NC).

### Results

We identified 67 patients with a diagnosis of myeloma (mean age, 66.2 years old; 37 of 67 men [55%]) from our population of more than 800 patients treated with percutaneous vertebroplasty from October 2000 to May 2007. Some of these patients have been included in a previous publication detailing our complete vertebroplasty experience, but they were not specifically evaluated separately from the entire database.<sup>37</sup> Sixty-six of the 67 patients had concomitant preoperative MR imaging studies, with 7 of these patients having outside imaging and the remaining 59 having MR imaging performed at our medical center. Among these 66 patients, MR imaging modalities identified 16 patients with diffuse (stage III) disease (24%), whereas the remaining 50 patients (76%) had myeloma limited to 10 or fewer vertebral bodies, consummate with more localized (stage II) disease. Of the treated vertebral levels in patients with available imaging studies (eg, digital copies of MR studies), 37 patients (64%) had no obvious myelomatous



**Fig 1.** Sagittal T1 MR imaging demonstrating fracture types. Stars indicate treated fractures. A, Type 1 fracture, considered probably osteoporotic in nature. Areas of preserved, high T1 signal intensity within the fractured vertebral body, without focal intravertebral lesion and no evidence for pedicle involvement or epidural or paraspinal disease (not shown). B, Type 2 fracture, indeterminate for underlying lesions. Diffusely low signal intensity marrow throughout the spine. No focal lesion or epidural or paraspinal lesion within the treated vertebral body. C, Type 3 fracture, with clear evidence for myelomatous lesion within the treated vertebral body.

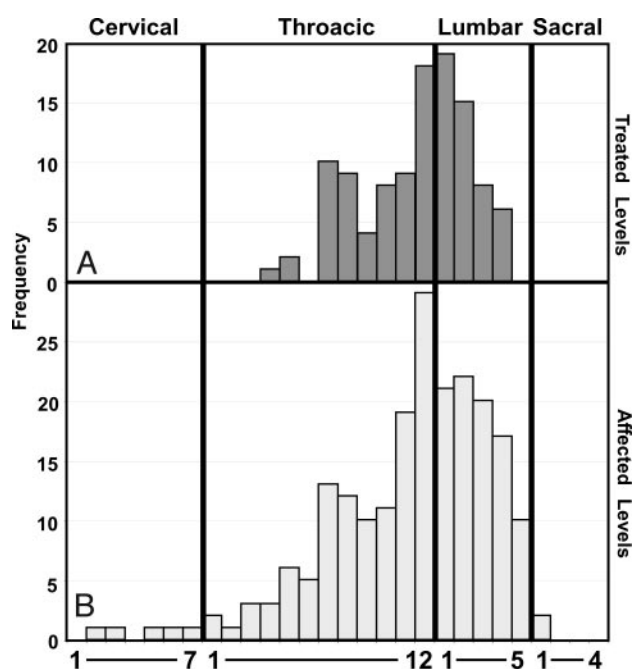
involvement of the symptomatic compression fracture site (type 1), 14 patients (24%) had indeterminate myelomatous involvement (type 2), and 7 patients (12%) appeared to have symptomatic compression fractures in vertebral bodies associated with myeloma (type 3). Representative examples of each compression fracture type are shown in Fig 1.

Twelve (17%) of our patients showed subsequent radiographic evidence of compression fractures after vertebroplasty. Of these 12 fractures, 5 were deemed symptomatic and were treated with a second vertebroplasty, and 7 were deemed asymptomatic. Of the symptomatic cases, 2 (40%) occurred within 12 months (2 and 3 months) of the original vertebroplasty, and 3 were adjacent to the site of treatment. Of the asymptomatic cases, 4 (57%) occurred within 12 months (2, 6, 8, and 10 months) of the original vertebroplasty, and 4 were adjacent to the site of treatment. Exclusion of these 5 patients from our data analysis did not significantly affect outcomes presented below.

Thirteen patients (19%) experienced some form of minor procedural complication, including 6 patients (9%) with inadvertent disk-space injection, 4 (6%) with paravertebral space injection, and 3 (4%) with cement embolus to the epidural vein without clinical sequelae. None of these complications were found to be symptomatic at the time or were felt to confound subsequent objective or subjective clinical outcome measures.

### Treated Levels

Vertebroplasty was performed on 114 vertebral levels in the 67 patients in our study group. In this patient group, the mean number of fractured vertebrae (mean, 5.4; SD, 3.1) was much greater than the mean number of treated vertebrae (mean, 1.7; SD, 0.8) per patient (Fig 2). The mean number of untreated asymptomatic vertebral compression fractures was 4.2 per patient. No significant differences were observed in affected or treated levels between male and female patients (affected level  $P = .68$ ; treated level  $P = .82$ ). As described previously, a bimodal distribution of fractures was observed, centering at

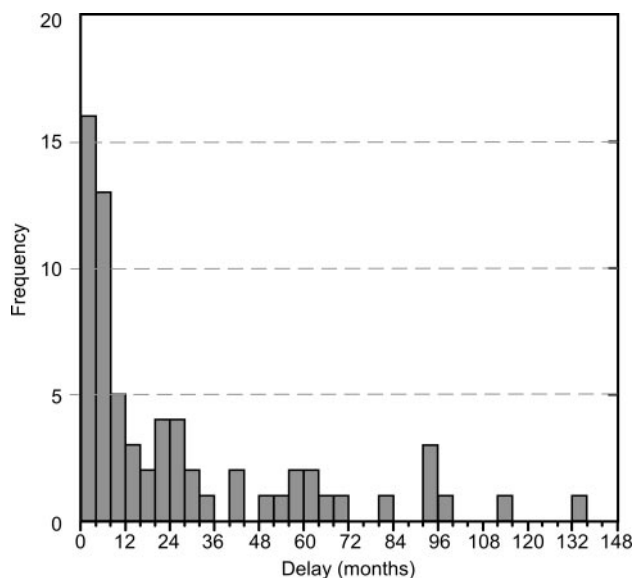


**Fig 2.** Treated and affected levels. Vertebral level frequency histograms of 114 treated vertebral levels (A) and 216 affected vertebral levels (B) in the 67 patients composing the myeloma study population. Diffuse myeloma involvement ( $>10$  vertebral bodies) was not included in this histogram.

T7/T8 and at the thoracolumbar junction (T12–L2) in both the treated (Fig 2A) and affected (Fig 2B) vertebral levels.<sup>10</sup> Cervical involvement, though rare, was never treated with vertebroplasty, because all of these patients had concomitant disease at lower symptomatic load-bearing vertebral levels.

### Time to Treatment

The median time between diagnosis of myeloma and treatment was 27 months, with a range of 1–133 months (Fig 3). Thirty four (50%) of the patients received treatment (eg, vertebroplasty) within 12 months of diagnosis. Specific review of the medical records suggests that a shorter time to vertebro-



**Fig 3.** Time to treatment. Time to treatment of myeloma study participants is shown as a function of a frequency histogram with each bin representing a 4-month period.

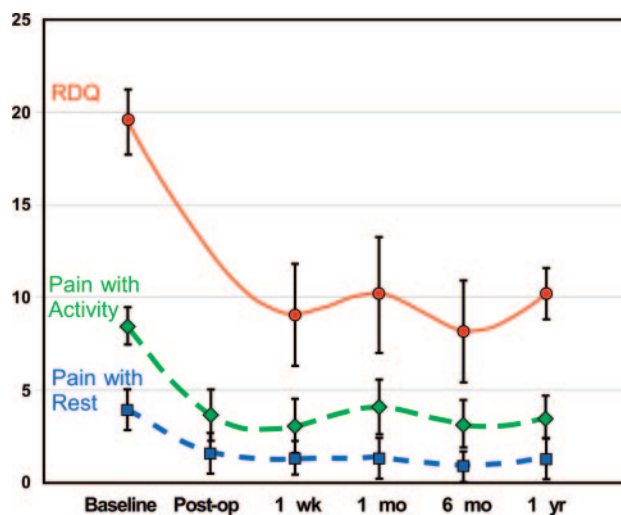
plasty was a function of a painful compression fracture being the presenting symptom of disease. With this in mind, we decided to further investigate the temporal relationship between onset of symptoms, diagnosis, and treatment. The median time between onset of symptoms (back pain with subsequent radiologic evidence of compression fracture) to treatment was 1.6 months, with a range of 0.6–24.0 months in 66 of the 67 patients. Similarly, the median time between diagnosis of myeloma and onset of symptoms (back pain with subsequent radiologic evidence of compression fractures) was 23.5 months, with 5 patients having symptoms longer than their initial diagnosis (range of 8.0 months to 0.5 months before diagnosis) and 61 patients having symptoms of shorter duration than their diagnosis (range of 0–132 months after diagnosis).

#### Clinical Outcome Analysis

Analog pain scale data were collected postoperatively on all 67 of the patients. To date, 62 of the 67 patients had quantitative (analog pain at rest/activity and RDQ) and qualitative (change in mobility, change in narcotic drug use, and change in pain with rest and pain with activity) subjective outcome data collected at the 1-month end point, 60 of the 67 at the 6-month end point, and 42 at the 1-year end point. Lack of postprocedure outcome data was either due to insufficient follow-up time due to recent treatment, loss to follow-up for unknown reasons, or death. Of the 25 patients missing follow-up data 1 year after vertebroplasty, 11 (44%) had vertebroplasty recently (<1 year ago), 6 (24%) were lost to follow-up for unknown reasons, and 8 (32%) had died.

#### Semiquantitative Outcome Analysis

All 3 of the quantitative outcome measures of pain (analog scale rest pain, analog scale activity pain, and RDQ score) showed significant decreases in postoperative scoring (Fig 4; note RDQ score was not collected immediately postoperatively). Before vertebroplasty, mean scores ( $\pm$  SD) were 19.5 ( $\pm$  3.44), 3.9 ( $\pm$  0.65), and 8.5 ( $\pm$  0.35) for the RDQ and



**Fig 4.** Objective clinical outcome scores over time. Mean ( $\pm$  SD) RDQ and analog pain scale (pain with rest and activity) scores are shown preoperatively (baseline), postoperatively, and 1 week, 1 month, 6 months, and 1 year after vertebroplasty.

analog measures of “pain at rest” and “pain with activity,” respectively. RDQ scores were significantly improved ( $P < .0001$ ) 1 week after vertebroplasty (median improvement of 11 points; 48%; 95% confidence interval [CI]:  $-7.7$  to  $-14.3$ ) with persistence of this improvement at 6 months ( $P < .0001$  compared with preprocedure scores) and 1 year ( $P < .01$  compared with preprocedure scores) with no statistically significant differences among the postprocedure scores. Analog pain scale data for “pain at rest” significantly improved after vertebroplasty ( $P < .01$  immediately after the procedure;  $P < .001$  at 1 week after) with a median improvement of 2.7 points at 1 week (25%; 95% CI:  $1.7$  to  $-3.7$ ) and remained improved at 6 months ( $P < .01$  compared with preprocedure scores) and 1 year ( $P < .03$  compared with preprocedure scores), with no significant intervening change in score. Analog pain scale data for “pain with activity” significantly improved after vertebroplasty ( $P < .0001$ ; median 5.3 point improvement at 1 week; 48%; 95% CI:  $-4.2$  to  $-6.4$ ) and remained improved at 6 months ( $P < .001$  compared with preprocedure scores) and 1 year ( $P < .001$  compared with preprocedure scores) with some intervening fluctuation in scores.

#### Subjective Outcome Analysis

Subjective assessments of pain (rest and activity), relative to preprocedural levels, were monitored over the 1-year follow-up period beyond vertebroplasty treatment. Much like the objective pain outcome results, subjective pain assessments showed a significant reduction in both rest- and activity-associated pain immediately after vertebroplasty. With regard to rest pain, 22 patients (45%) reported complete resolution of pain after vertebroplasty, 18 patients (37%) reported a significant reduction in pain, and 8 patients (16%) reported no change in their pain, whereas 1 (2%) reported increased pain immediately after vertebroplasty treatment. With regard to activity-associated pain, 11 patients (22%) reported complete resolution of pain after vertebroplasty, 33 patients (67%) reported a significant reduction in pain, and 4 patients (8%) reported no change in their pain, whereas 1 (2%) reported increased pain immediately after vertebro-

**Subjective outcome scores collected throughout follow-up**

Variable	Time				
	Postoperation	1 Week	1 Month	6 Months	1 Year
Rest pain	+1.25	+1.33	+1.29	+1.53	+1.49
Active pain	+1.10	+1.12	+1.00	+1.33	+1.12
Mobility		+0.76	+0.67	+0.83	+1.00
Narcotic use		+0.81	+0.84	+0.93	+0.94

**Note:**—Subjective outcome scores as compared with preoperative status: +2 indicates total improvement; +1, some improvement; 0, no change; −1, worse. Scores were calculated as described in the Methods section. Mobility and narcotic use were not determined until 1 week had passed after treatment.

plasty treatment. Numeric transformation of these outcome data, as summarized in the Methods section, further simplified analysis of these outcome data over time (Table) and shows that this reduction in pain persists over the year after treatment.

Subjective reporting of narcotic use was also followed in our study, because 56 (84%) of the 67 patients relied on narcotics for pain management before treatment. One week after treatment, 9 patients (16%) reported significant resolution of pain such that they discontinued their narcotic use altogether. 27 patients (49%) reported decreased narcotics use, and 16 patients (29%) reported no change in their narcotic requirements, whereas 3 (5%) reported increased requirements for narcotics after treatment. These relative ratios were used to give a weighted average to summarize the extent of change in narcotic use (Table) and to show that this reduction in narcotic use persisted over the year after treatment.

Determination of the impact of vertebroplasty on postprocedure mobility was measured through self-assessment of preprocedure and postprocedure mobility status. Before treatment, 23 patients (34%) claimed that they were able to walk greater than 1 block without the need to rest or lie down due to pain and/or disability, 21 (31%) claimed to be able to walk less than 1 block, 13 (19%) reported restricted movement such that they were often confined to bed, and 6 (9%) reported complete restriction to their bed. One week after treatment, 47 patients (70%) reported some improvement in their mobility, and 13 (19%) reported no change in mobility. After conversion to a numeric score, this improvement in mobility persisted up to 1 year after treatment (Table). Interestingly, correlation analysis demonstrated that patients with poorer initial mobility were more likely to experience improvement than those patients with good initial mobility (data not shown).

### Semiquantitative Outcome Correlation Analysis

In an effort to determine whether the number of affected or treated levels correlated with clinical outcome parameters, we performed nonparametric correlations comparing the number of affected or treated levels with estimates of pain (RDQ and analog pain scale; preoperatively, postoperatively, and at 1 week after treatment), mobility, and cement volume. The results yielded nonsignificant positive correlations between affected and/or treated levels and pain estimates (analog scale rest pain, analog scale activity pain, and RDQ) at all of the time points with 1 notable exception. Specifically, there was a significant ( $Rho = 0.58$ ) correlation between the number of treated levels and subsequent pain at rest immediately after vertebroplasty. This significant correlation, however, was absent from later time points ( $Rho < 0.2$ ). We did not find a

significant correlation between the number of affected levels and the mobility before or after treatment. Cement volumes positively correlated with both affected levels, nonsignificantly, and, not surprisingly, treated levels, significantly.

In addition, we sought to determine whether preoperative analog scale and RDQ pain scores possessed predictive value with regard to postoperative outcomes (analog scale pain, RDQ, and mobility). Analysis of the data shows that preoperative analog scale pain at rest scores significantly positively correlated with postoperative pain at rest scores immediately postoperatively and 1 week after treatment (positive correlation was observed  $\leq 6$  months; data not shown) in addition to cement volume. No other significant correlations were found to exist between preoperative objective pain measures and perioperative or postoperative outcomes.

Lastly, we studied preoperative imaging findings of grade and fracture type to determine whether they had any correlation on preoperative or postoperative scores and/or outcomes. No significant correlations ( $Rho$  values all  $< 0.2$ ) were observed in preoperative or postoperative pain or disability scores, mobility, narcotic use, or cement volume used during the vertebroplasty procedure.

### Discussion

We embarked on this study to better understand the treatment of myeloma patients with vertebroplasty and to better quantify clinical efficacy of this treatment in these patients. Our results show a dramatic improvement in both objective and subjective outcomes. Correlative analysis suggests that long-term outcomes (pain, mobility, and narcotic use) had no significant association with the extent of spinal involvement (eg, focal or diffuse disease), suggesting that both groups equally benefit from vertebroplasty. We also attempted to characterize the types of fractures treated in these patients, with an emphasis on observing the likelihood of underlying myelomatous lesion within the fractured vertebral body. Preoperative imaging studies suggest that “malignant” compression fractures in myeloma patients are quite heterogeneous, with more than 60% of fractures appearing benign, even in the presence of other myelomatous lesions along the spinal axis. Finally, we discovered that most of the patients in this cohort developed symptomatic compression fractures very shortly before seeking treatment. These results suggest that, whereas myeloma can be a slowly progressive process, symptomatic compression fractures often present rather acutely in a manner similar to benign compression fractures.

To date, this report represents the largest study available specifically addressing the role of vertebroplasty in myeloma patients. Although compression fractures are common in myeloma, it is a relatively rare disease, and many compression fractures are asymptomatic. In addition, many previous studies involving myeloma patients were nonspecific and focused on mixed populations of malignant compression fractures of any etiology or did not discriminate between kyphoplasty and vertebroplasty.<sup>18,19,23,26</sup> We intentionally sought to separate myeloma (a primary osteolytic cancer of the vertebral body) from other malignant neoplasms that can invade the spine because their pathophysiologic mechanisms differ and, thus, may confound or bias the results.

Compared with previous studies from our group and oth-

ers assessing the efficacy of vertebroplasty in benign compression fractures resulting from osteoporosis, we find similar but not identical short- and long-term outcomes. Specifically, our treated-level analysis (Fig 1A) looks remarkably similar to previous benign compression fracture studies in distribution,<sup>10</sup> suggesting that the prevalence/levels of symptomatic compression fractures in myeloma patients are no different from osteoporotic patients with painful compression fractures. This may be a direct effect of the fact that most of the observed compression fractures appeared focally benign. Compared with previous analog measures of pain at rest and with activity, we observed a similar short- and long-term reduction in scores: pain at rest, with previous study<sup>34</sup> as the second number: (baseline) 3.9 versus 4.1, (1 week) 1.3 versus 1.6, (1 month) 1.3 versus 1.3, (6 months) 0.9 versus 1.0, and (1 year) 1.3 versus 1.7; pain with activity, with previous study<sup>34</sup> as the second number: (baseline) 8.4 versus 8.5, (1 week) 3.1 versus 5.0, (1 month) 4.1 versus 4.4, (6 months) 3.1 versus 3.8, and (1 year) 3.5 versus 3.7, with perhaps more rapid equilibration occurring in the myeloma patient group.<sup>10,32</sup> Comparable reductions were also observed in RDQ scores postoperatively with similar long-term durability of score reduction: RDQ with previous study<sup>34</sup> as the second number: (baseline) 19.5 versus 18.2, (1 week) 9.1 versus 11.2, (1 month) 10.2 versus 10.5, (6 months) 8.2 versus 8.9, and (1 year) 10.2 versus 11.8. In total, these parallels in data between myeloma and osteoporotic patient groups give us confidence that myeloma patients have similar short- and long-term outcomes to osteoporotic patients.

Certain limitations to this study can be attributed to the nature of retrospective studies where observation bias (eg, postoperative pain reporting) and loss to follow-up can, in some cases, overestimate the significance of a treatment effect. Before the use of methods to quantify pain by using standardized inventories, such as the RDQ and analog pain scales, there were very few reliable methods to properly quantify pain. Now, even despite these improved quantification strategies, pain remains a subjective complaint that may, over time, become better tolerated, leading to a false perception of pain decline over time. Although this effect may play some role in all of the long-term pain studies, the immediate relief offered by vertebroplasty is suggestive of a real benefit that is unlikely to be a result of enhanced pain tolerance. Second, loss to follow-up is a common and vexing problem that faces all longer-term studies. In this study, 38% of patients were lost to follow-up at 1 year and 71% at 2 years. Third, we did not include data regarding the number of patients with myeloma in whom we did not choose to offer vertebroplasty, so there is probably selection bias in this cohort.

## Conclusions

Vertebroplasty appears to offer rapid and long-lasting treatment of pain associated with vertebral compression fractures in myeloma patients. In addition, correlation analysis suggests that the extent of spinal involvement of myeloma is unrelated to analog pain scale and RDQ pain outcome scores. Taken together, these data show that vertebroplasty is an effective treatment that confers lasting pain relief, enhanced mobility, and reduced narcotic use for all of the stages of myeloma associated with painful compression fractures.

## References

1. Trumm CG, Jakobs TF, Zech CJ, et al. **Vertebroplasty in the treatment of back pain [in German].** *Radiologe* 2006;46:495–505
2. Lieberman I, Reinhardt MK. **Vertebroplasty and kyphoplasty for osteolytic vertebral collapse.** *Clin Orthop Relat Res* 2003;S176–86
3. Kallmes DF, Jensen ME. **Percutaneous vertebroplasty.** *Radiology* 2003;229:27–36
4. Deramond H, Depriester C, Galibert P, et al. **Percutaneous vertebroplasty with polymethylmethacrylate. Technique, indications, and results.** *Radiol Clin North Am* 1998;36:533–46
5. Evans AJ, Jensen ME, Kip KE, et al. **Vertebral compression fractures: pain reduction and improvement in functional mobility after percutaneous polymethylmethacrylate vertebroplasty retrospective report of 245 cases.** *Radiology* 2003;226:366–72
6. McGraw JK, Lippert JA, Minkus KD, et al. **Prospective evaluation of pain relief in 100 patients undergoing percutaneous vertebroplasty: results and follow-up.** *J Vasc Interv Radiol* 2002;13:883–86
7. Voormolen MH, Lohle PN, Lampmann LE, et al. **Prospective clinical follow-up after percutaneous vertebroplasty in patients with painful osteoporotic vertebral compression fractures.** *J Vasc Interv Radiol* 2006;17:1313–20
8. Hochmuth K, Proschek D, Schwarz W, et al. **Percutaneous vertebroplasty in the therapy of osteoporotic vertebral compression fractures: a critical review.** *Eur Radiol* 2006;16:998–1004
9. Chang CY, Teng MM, Wei CJ, et al. **Percutaneous vertebroplasty for patients with osteoporosis: a one-year follow-up.** *Acta Radiol* 2006;47:568–73
10. Trout AT, Gray LA, Kallmes DF. **Vertebroplasty in the inpatient population.** *AJNR Am J Neuroradiol* 2005;26:1629–33
11. Anselmetti GC, Corgnier A, Debernardi F, et al. **Treatment of painful compression vertebral fractures with vertebroplasty: results and complications.** *Radiol Med (Torino)* 2005;110:262–72
12. Gangi A, Guth S, Imbert JP, et al. **Percutaneous vertebroplasty: indications, technique, and results.** *Radiographics* 2003;23:e10
13. Zoarski GH, Snow P, Olan WJ, et al. **Percutaneous vertebroplasty for osteoporotic compression fractures: quantitative prospective evaluation of long-term outcomes.** *J Vasc Interv Radiol* 2002;13:139–48
14. Peh WC, Gilula LA, Peck DD. **Percutaneous vertebroplasty for severe osteoporotic vertebral body compression fractures.** *Radiology* 2002;223:121–26
15. Chang F, Depriester C, Cayrolle G, et al. **Long-term observations of vertebral osteoporotic fractures treated by percutaneous vertebroplasty.** *Rheumatology (Oxford)* 2000;39:1410–14
16. Jensen ME, Evans AJ, Mathis JM, et al. **Percutaneous polymethylmethacrylate vertebroplasty in the treatment of osteoporotic vertebral body compression fractures: technical aspects.** *AJNR Am J Neuroradiol* 1997;18:1897–904
17. Yamazaki E, Takemura S, Sakamoto H, et al. **Efficacy of percutaneous vertebroplasty for multiple myeloma [in Japanese].** *Rinsho Ketsueki* 2007;48:200–03
18. Yang Z, Xu J, Sang C. **Clinical studies on treatment of patients with malignant spinal tumors by percutaneous vertebroplasty under guidance of digital subtraction angiography [in Chinese].** *Zhongguo Xue Fu Chong Jian Wai Ke Za Zhi* 2006;20:999–1003
19. Ryska P, Rehak S, Odraka K, et al. **Role of percutaneous vertebroplasty and kyphoplasty in the treatment of oncology disorders of the spine [in Czech].** *Cas Lek Cesk* 2006;145:804–09; discussion 809–10
20. Rodriguez-Catarino M, Blimark C, Willen J, et al. **Percutaneous vertebroplasty at C2: case report of a patient with multiple myeloma and a literature review.** *Eur Spine J* 2007; Vol 16, Supplement 3
21. Ramos L, de Las Heras JA, Sanchez S, et al. **Medium-term results of percutaneous vertebroplasty in multiple myeloma.** *Eur J Haematol* 2006;77:7–13
22. Pflugmacher R, Schleicher P, Schroder RJ, et al. **Maintained pain reduction in five patients with multiple myeloma 12 months after treatment of the involved cervical vertebrae with vertebroplasty.** *Acta Radiol* 2006;47:823–29
23. O'Brien J, Brennan D, Taylor D, et al. **Percutaneous vertebroplasty—initial clinical experience in osteoporotic and myelomatous compression fractures.** *Ir J Med Sci* 2006;175:50–53
24. Layton KF, Thielen KR, Cloft HJ, et al. **Acute vertebral compression fractures in patients with multiple myeloma: evaluation of vertebral body edema patterns on MR imaging and the implications for vertebroplasty.** *AJNR Am J Neuroradiol* 2006;27:1732–34
25. Chakrabarti I, Burton AW, Rao G, et al. **Percutaneous vertebroplasty of a myelomatous compression fracture in the presence of previous posterior instrumentation. Report of two cases.** *J Neurosurg Spine* 2006;5:168–71
26. Bartolozzi B, Nozzoli C, Pandolfo C, et al. **Percutaneous vertebroplasty and kyphoplasty in patients with multiple myeloma.** *Eur J Haematol* 2006;76:180–81
27. Shimony JS, Gilula LA, Zeller AJ, et al. **Percutaneous vertebroplasty for malignant compression fractures with epidural involvement.** *Radiology* 2004;232:846–53
28. Diamond TH, Hartwell T, Clarke W, et al. **Percutaneous vertebroplasty for acute vertebral body fracture and deformity in multiple myeloma: a short report.** *Br J Haematol* 2004;124:485–87

29. Tong FC, Cloft HJ, Joseph GJ, et al. **Transoral approach to cervical vertebroplasty for multiple myeloma.** *AJR Am J Roentgenol* 2000;175:1322–24
30. Cortet B, Cotten A, Boutry N, et al. **Percutaneous vertebroplasty in patients with osteolytic metastases or multiple myeloma.** *Rev Rhum Engl Ed* 1997;64:177–83
31. Cotten A, Dewatre F, Cortet B, et al. **Percutaneous vertebroplasty for osteolytic metastases and myeloma: effects of the percentage of lesion filling and the leakage of methyl methacrylate at clinical follow-up.** *Radiology* 1996;200:525–30
32. **Criteria for the classification of monoclonal gammopathies, multiple myeloma and related disorders: a report of the International Myeloma Working Group.** *Br J Haematol* 2003;121:749–57
33. Dimopoulos MA, Mouloupoulos LA, Datsis I, et al. **Imaging of myeloma bone disease: implication for staging, prognosis and follow-up.** *Acta Oncol* 2000;39:823–27
34. Trout AT, Kallmes DF, Gray LA, et al. **Evaluation of vertebroplasty with a validated outcome measure: the Roland-Morris Disability Questionnaire.** *AJNR Am J Neuroradiol* 2005;26:2652–57
35. Roland M, Morris R. **A study of the natural history of back pain. Part I. Development of a reliable and sensitive measure of disability in low-back pain.** *Spine* 1983;8:141–44
36. Patrick DL, Deyo RA, Atlas SJ, et al. **Assessing health-related quality of life in patients with sciatica.** *Spine* 1995;20:1899–908; discussion 1909
37. Layton KF, Thielen KR, Koch CA, et al. **Vertebroplasty, first 1000 levels of a single center: evaluation of the outcomes and complications.** *AJNR Am J Neuroradiol* 2007;28:683–89