



Get Clarity On Generics

Cost-Effective CT & MRI Contrast Agents



FRESENIUS
KABI

WATCH VIDEO

AJNR

Atlas of Ultrasound Measurements, 2nd ed.

AJNR Am J Neuroradiol 2007, 28 (6) 1201-1202

doi: <https://doi.org/10.3174/ajnr.A0523>

<http://www.ajnr.org/content/28/6/1201>

This information is current as
of August 10, 2025.

and the development of lower back pain. Moreover, they find moderate evidence for the sensitivity (88%–94%) and specificity (57%–64%) of CT in detecting herniated disks. However, they found only limited evidence of the value of CT in detecting intrathecal nerve root pathology and could find no data on the accuracy of CT or MR imaging for nerve root impingement.

This analysis is the strength of the book and its *raison d'être*. If one is interested in understanding the current status of the literature on the application of neuroradiology to a particular clinical topic, then each chapter provides a good summary of the state of the art. The evidence-based analysis also imparts a valuable perspective on the degree to which we should rely on some of the common wisdoms. It counters the natural tendency in most publications (journals, books, and so forth) to tout each new discovery as being vitally important to the better care of patients.

Like any review article or book, this analysis has limitations. The assessment will by definition be shortly out of date. The strong focus on the current state of the literature and assessment of its value makes the problem more significant with this work than with a work examining the imaging findings themselves. Moreover, each clinical topic is presented at a relatively cursory level with a short summary of the data. The organization of the chapters by clinical condition paradoxically narrows the focus of the work to more of a technique (MR, CT, and so forth) analysis than the more typical format based on an imaging finding and its differential diagnosis. Moreover, the strength of data analysis (strong, moderate, and so forth) is presented without much, if any, detail as to how each statement was determined. We have to accept the verdict of the authors on the strength of each evidence statement without much supporting information.

Even with those limitations, this book is a significant addition to the radiology literature. It is the first work that emphasizes the importance of an evidence-based perspective toward the appropriate use of imaging technology on the management of patients. The next several years will surely see an increasing focus on these issues in the health care community at large, and radiology needs to be able to respond to the implicit and sometimes explicit challenges that will surely develop. How will we answer the critics of increasing use of diagnostic imaging? How does our research document the value of imaging examinations in the outcome of patients with specific disease states? Many of us may be referring to this book and perhaps others like it increasingly in the future as we respond to these and other such questions.

DOI 10.3174/ajnr.A0522

BOOK REVIEW

Atlas of Ultrasound Measurements, 2nd ed.

Barry B. Goldberg and John P. McGahan, eds. Philadelphia: Mosby-Elsevier, 2006, 512 pages, 400 illustrations, \$110.00.

The *Atlas of Ultrasound Measurements, 2nd Edition* offers insight into established diagnostic criteria detailed by leaders in the field of diagnostic sonography. It serves as a reference

for those establishing a practice, a comprehensive text for study protocol preparation, an essential reference book for those seeking and/or renewing accreditation of their laboratories, as well as a standard text for physicians in training and sonographers.

The editors organized this book into anatomic/specialty segments comprising 13 areas, which allow a quick reference of an area of interest.

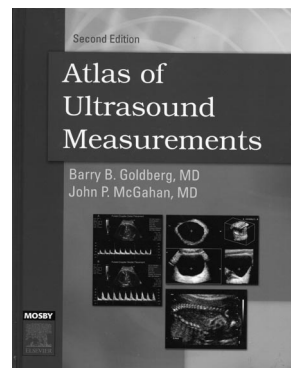
There are a total of 93 chapters blending gray-scale, Doppler, and newer 3D/4D applications in obstetric and genitourinary sonography. The contributors include experts in their fields of medical sonography, as well as newcomers initiating their professional careers in this exciting imaging field.

The book offers a detailed obstetric slate of measurements, divided into 3 parts: first trimester, second and third trimesters, and obstetric Doppler, including placental circulation. These parts are then divided into 43 individual chapters with measurements, charts, illustrations, and state-of-the-art 3D/4D images for easy identification of fetal anatomic landmarks. A very complete gray-scale fetal cardiac evaluation is included, supplemented by a description of Doppler fundamental principles for accurate fetal cardiac evaluation. The authors caution the reader regarding higher energy exposure of the fetus during spectral Doppler evaluation, guiding the reader to localize the area of interest first with color Doppler (remaining within the as low as reasonably achievable recommendations). A comprehensive up-to-date reference list with classic publications and recent literature is provided.

Pediatric sonography measurements are detailed in Part 5, subdivided into 18 chapters. These range from neurosonology to abdominal/pelvic and musculoskeletal evaluations. It is rich in detail regarding scanning techniques to avoid exerting too much pressure (on the fontanelle) and selecting the best transducer. Evaluation of pyloric stenosis is comprehensive. The evaluation of the neonatal hip, endorsed by the American College of Radiology and the American Institute of Ultrasound in Medicine as the best method for the exclusion of developmental hip dysplasia, is complete with angle measurements, femoral head size, and a full description of correct positioning of the patient and anatomic landmarks for accuracy.

An entire part is dedicated to the 3 methods of cardiac evaluation with sonography, encompassing pediatric and adult patients. The author details M-mode, pulsed-Doppler, and 2D echocardiography. All calculations of cardiac and valvular performance are included with current reference articles. Transesophageal echocardiography, due to its specific applications, is not included in this book.

Head and neck imaging comprises gray-scale and Doppler evaluation, described in 2 separate parts. Chapters on internal carotid/vertebral artery surveillance (with endorsement of the consensus conference sponsored by the Society of Radiologists in Sonography) are complete. Transcranial Doppler is approached with detailed descriptions of vessel identification, flow characteristics and direction, interpretation guidelines, as



well as its strengths and limitations. A complete set of criteria for diagnosing stenosis, occlusion, collateral pathways, vasospasm, and elevated velocities in sickle cell disease is included. Another chapter in this part, very well-illustrated, includes scanning techniques and criteria for the diagnosis of temporal arteritis.

The well-established applications of abdominal, pelvic, and Doppler are very complete. However, the newer applications of volume acquisition of sonographic images and their clinical applications of 3D/4D for abdominal/pelvic areas have yet to be established; therefore, they are not included in this edition. Volumetric images of the kidneys and urinary bladder are portrayed in 3D format.

Part 10 represents a complete set of chapters on the role of Doppler in the evaluation of native and transplanted organs and specific applications such as transjugular intrahepatic portosystemic shunts, renal artery stenosis, and chronic mesenteric ischemia. Every chapter discusses in detail normal and abnormal hemodynamics portrayed on spectral waveforms, offering clues to the underlying pathology related either to cardiac disease or to the organ being evaluated.

The entire book has state-of-the-art illustrations, with excellent color, power, or 3D/4D sonographic images. The authors and editors have compiled a very comprehensive text regarding sonography measurements: gray-scale, color/power, and spectral Doppler. Those interested in neuroradiology can derive basic comprehension of the diagnostic sonography field as it pertains to prenatal intracranial assessment and middle cerebral artery flow and its value in the assessment of fetal growth restriction. Neonatal neurosonology, transcranial Doppler, and extracranial carotid occlusive disease are other applications pertaining to neuroimaging.

DOI 10.3174/ajnr.A0523

BOOK REVIEW

Essentials of Nuclear Medicine Imaging, 5th ed.

Fred A. Mettler and Milton J. Guiberteau, eds. New York: Elsevier, 2006, 512 pages, 600 illustrations, \$95.00.

For an imaging textbook to have a 5th edition, the previous 4 editions must have been quite good. Indeed, since the first edition of the text was published in 1983, this historically concise textbook has been a mainstay choice for radiology-resident nuclear medicine education. For many years, the prior editions of this text have been very popular choices as the single nuclear medicine book that radiology residents would read in preparation for their boards. Nuclear medicine has seen great changes in the past 23 years, and this 5th edition follows a full 8 years after the 4th edition. Thus, much innovation has occurred in this time (like nearly all of clinical positron-emission tomography [PET] and now PET/CT), so new material had to be added to make the book relevant to the substantially different and more complex current practice of nuclear medicine.

Including the index, the “concise” book now contains nearly 580 pages. The book is attractive, with substantial use of color in a variety of chapters, including images, tables, and artists’ drawings. There are 14 chapters, a 70-page set of “unknown cases,” and 13 appendices. Although the title of the book is “Imaging,” there is some treatment of the growing area of therapeutic nuclear medicine, especially as it relates to radiation safety issues. The organization of the book is generally logical. The first chapter deals with radioactivity, radionuclides, and, to some extent, radiopharmaceuticals. The second and third chapters cover instrumentation and quality control. Chapters 4–12 deal with organ system imaging, tumor imaging (non-PET), and inflammation imaging. These chapters essentially exclude PET imaging in toto, but chapter 13 is a nearly 70-page minitext on all of PET. Chapter 14 deals with radiation safety and regulations. The 13 appendices follow and include a rather comprehensive and valuable chapter on sample techniques for nuclear imaging (a “how to” section).

In each chapter, there are illustrations, tables, and figures in color and a very useful section at the end of each chapter entitled “Pitfalls,” which has highlights of the chapter. The overall design of the book works reasonably well, but there is a clear lack of integration of the PET physics, chemistry, and imaging results with the rest of the book. This was clearly an easier choice for the authors than trying to break up PET by organ systems and to integrate it into the organ-based sections. It does lead to some discontinuities in the text. For example, if one wants to know how to image thyroid disease, one has to look in 2 places, 1 for single-photon emitters and another for PET. This is somewhat cumbersome, but understandable. Overall, the book is quite reasonably organized and contains useful information, some very hard to acquire easily in other ways, and most of it is accurate.

Although the book covers most nuclear medicine and seems to be a very good choice for a radiology resident in training or someone wishing to update themselves in the field after a lapse in practice, of relevance to readers of this journal is how well it addresses the needs of a practicing neuroradiologist who wishes to brush up on nuclear medicine either to do some PET or some on-call nuclear studies.

The first 3 chapters are quite useful, though the first chapter has very little about radiopharmaceuticals, despite its name. Rather, radiopharmaceuticals are discussed elsewhere in the book by organ system, but their treatment is brief. A minor omission in the chapter on mechanisms of localization is the absence of radiopeptide-receptor imaging methods (eg, somatostatin-receptor imaging). In the instrumentation chapter, the figures are generally good.

Given the overall quality of the paper used in the book and placement of color figures and tables throughout, I had high expectations for the quality of images. However when a 5th

