



Providing Choice & Value

Generic CT and MRI Contrast Agents



**FRESENIUS
KABI**

CONTACT REP

AJNR

**Neuroimaging Clinics of North America.
Stroke II: Imaging Techniques and Future
Direction**

AJNR Am J Neuroradiol 2007, 28 (1) 189-190

<http://www.ajnr.org/content/28/1/189>

This information is current as
of July 29, 2025.

BOOK REVIEW

Neuroimaging Clinics of North America. Stroke II: Imaging Techniques and Future Direction

M.H. Lev, ed. Philadelphia: WB Saunders: 2005. 240 pages, \$84.95.

The wide acceptance of the concept of an ischemic penumbra in acute ischemic brain tissue has encouraged neuro-radiologists and researchers in the field to peruse advanced imaging techniques to demonstrate the extent of the penumbra, which will help guide patient selection for treatment and eventually improve clinical outcome. To meet the rapidly changing concepts in acute stroke imaging and management, the guest editor, Dr. Lev, has endeavored to cover the important topics on acute stroke in 2 volumes. The first offers an overview of differing approaches to stroke prevention and management. The second explores technical development in stroke imaging and its future direction. Although it may appear impossible in a monograph with limited pages, Dr. Lev and the other experts achieved their goal. One will find this volume to be a concise format with in-depth coverage of the most updated stroke-imaging techniques and concepts that are not otherwise available in any single textbook.

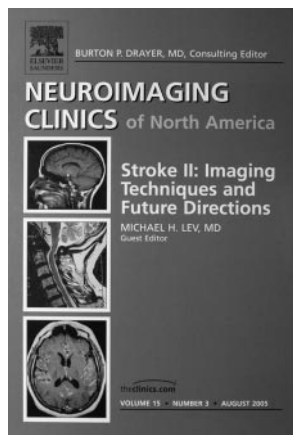
The volume, *Stroke II: Imaging Techniques and Future Direction (Neuroimaging Clinics of North America)*, includes 3 parts: Part 1 consists of 7 chapters focusing on a array of advanced imaging techniques for acute stroke, starting with transcranial Doppler sonography, CT perfusion, diffusion-weighted imaging, xenon CT, and single-photon emission CT (SPECT), to cover concepts of “beyond the clot phenomena” and of extending the time window for thrombolysis. Part 2 has just 1 chapter on “Pediatric Stroke,” emphasizing that the child is not merely a small adult in etiology, and “Pathophysiologic Mechanisms of Stroke”; Part 3 encompasses 7 chapters on “Work in Progress” and “Future Directions,” exploring cutting-edge technology for acute stroke, such as plaque imaging, sodium MR imaging, diffusion tensor imaging and fiber tractography, and functional MR imaging. One feels that the guest editor intended to reach a wide readership, including trainees, practicing neuroradiologists, and researchers interested in this field.

The first chapter describes the utility and potential applications of “Transcranial Doppler (TCD) in the Management of Acute Stroke.” The chapter presents a succinct introduction of the advantages and limitations of TCD, emphasizing its ideal role as a bedside tool. Practical emergency department protocols and grading systems for vascular flow are nicely illustrated with high-quality figures and appropriately labeled legends. Starting

with answering 4 fundamental questions of acute stroke, the chapter on “CT Perfusion in Acute Stroke” nicely introduces this relatively new technique, addressing its role in defining reversible and irreversible ischemic tissue. There is inconsistent quality of the CT and MR images in this chapter. The chapter on “Diffusion-Weighted Images in Acute Stroke” provides a useful overview of the fundamental principle and interpretation of diffusion images, including diffusion-weighted images, apparent diffusion coefficient maps, and exponential images, as well as the potential role of tensor imaging. The images are of good quality.

Two short chapters focus on xenon CT and SPECT imaging. The former chapter starts with concepts of ischemia and penumbra, comparing the quantitative values between imaging techniques and patient selection for treatment. Unfortunately, there is a lack of comparison between xenon CT and CT perfusion in acute stroke. The illustrations are mediocre in quality. The chapter on “SPECT in Acute Stroke” succinctly addresses the potential applications of SPECT, mainly with technetium Tc99m hexamethylpropyleneamine oxime and Tc99m L-ethyl cysteinate dimmer. High-quality SPECT images, along with CT, diffusion MR imaging, and x-ray angiography, are presented to demonstrate the characteristics of SPECT. One minor shortcoming is that the authors did not mention the clinical applications of SPECT with Tc99m diethylenetriamine pentaacetic acid, which is an old application but is particularly useful in evaluating blood-brain barrier damage. The last 2 chapters in Part 1 of the volume describe the collaterals in acute stroke and the therapeutic time windows based on the existing acute stroke trials. The author of the former chapter outlines the concepts of collaterals from within the same or different territories in the setting of acute arterial occlusion by providing superb drawings and corresponding neuroimages taken from his prior article. The vascular collateral concepts are combined with CT and MR perfusions in later sections and form excellent teaching material for trainees and practicing radiologists. The latter chapter outlines a step-by-step approach to characterization of an ischemic lesion that may be affected by specific patient factors, pre-existing lesions, the perfusion deficit, site of occlusion, and permeability.

The reason for adding a separate chapter on “Pediatric Stroke” in this volume is unclear. We are accustomed to categorizing pediatric stroke according to different etiologies because these patients are not eligible for most stroke trials. Examples of this are fetal and perinatal strokes and Moyamoya syndrome. Chapters on “Work in Progress” and “Future Directions” are apparently welcome to neuroradiologists and physicists who are doing serious research. Chapters such as “Plaque Imaging,” “Sodium Imaging,” and “Functional Stroke Imaging” concern techniques that are not familiar to most neuroradiologists, and they are not relevant to the decision making in acute stroke. These chapters, however, provide insight into the trend of the future stroke study. One exception is the technique of MR perfusion, which has been used for a while for stroke diagnosis and brain tumor study. This chapter describes issues related to the absolute quantification of perfusion parameters (in particular the cerebral blood flow with arterial input effects removed) that are important in ischemic stroke. The topic is correctly categorized as “New Develop-



ments” because there are currently many unanswered questions that could lead to erroneous estimates of blood flow. This overview is comprehensive, with superb illustrations, but the chapter might not seem germane from a clinician’s point of view, as far as the decision making for thrombolytic therapy is concerned.

The chapter on “Diffusion Tensor Imaging and Fiber Tractography in Acute Stroke” is succinct but somewhat disappointing, partly because it is not as useful in acute stroke diagnosis as it is for brain tumor management. Half of the chapter introduces the basic principle of diffusion tensors, but to this reviewer’s surprise, no illustrations are provided to help understand this complex phenomenon and theory. On the other hand, several functional imaging tools, such as permeability, cerebrovascular reserves, and blood oxygenation level-dependent–related functional MR imaging, can be used to evaluate the functional status or recovery of the brain after stroke or brain tissue at risk.

Current ischemic stroke therapy is evolving rapidly but has had limited success. The last chapter provides an excellent review of the basic mechanisms of ischemic cell death and introduces the ongoing neuroprotective drug trials and the nonpharmaceutical therapies for acute ischemic stroke. The images and charts are adequate.


The authors have succeeded in what they have set out to accomplish, providing an excellent review of the current state of the art and future directions for imaging techniques in an area that is undergoing rapid evolution. A minor drawback is the lack of consistent internal organization within each chapter, which could have enhanced readability, and a lack of cross-reference between those chapters that primarily focus on imaging techniques. The monograph is recommended to all trainees, neuroradiologists, and neuroscientists who are looking for a quick review of cutting-edge technology on stroke imaging and the evolving concepts for acute stroke treatment.

BOOK REVIEW

Experimental Models of Multiple Sclerosis

E. Lavi and C.S. Constantinescu, eds. New York: Springer: 2005. 901 pages, \$195.

Multiple sclerosis, as noted in the forward of the text, is an enigmatic immune-mediated disease of the central nervous system (CNS) affecting 2–3 million individuals worldwide. There is considerable interest in the investigation of the mechanism of this disease and in the improvement of diagnosis and assessment of prognosis. Multiple sclerosis is not well characterized and no cure exists. Therapeutic agents are in continual development, and there is a need in much of this research for animal models related to disease processes, including demyelination/remyelination, inflammation, and axonal pathology. It has become well-known that no single animal model reproduces the human disease and that many animal models can represent 1 or more facets of the disease. There is considerable overlap between ani-



mal models and other diseases distinct from multiple sclerosis as well. With this in mind, Drs. Lavi and Constantinescu have produced a specialist book that aims to combine and present information about every existing animal model for multiple sclerosis. The target audience for this book includes neuroscientists, neurologists, immunologists, microbiologists, and neuropathologists. Clearly, some neuroradiologists having an interest in basic neuroscience, multiple sclerosis re-

search, and the study of related disorders will also benefit from the information in this book. For the readers of *AJNR*, it is thought that a primary use of this book might be as a reference for those collaborating with basic neuroscientists.

The most common experimental models for multiple sclerosis can be described as immune-mediated or virus-induced, and these distinctions form the basis for the organization of the book into 4 sections. The first and longest section covers “Experimental Allergic (Autoimmune) Encephalomyelitis (EAE).” In these 576 pages and 27 chapters, EAE is given a comprehensive treatment, including history, histopathology, genetics, roles of individual cell types and processes, and a single section devoted to EAE in primates. The second section devotes 119 pages and 9 chapters to “Theiler’s Murine Encephalomyelitis Virus (TMEV)–Induced Demyelination.” The 139 pages and 13 chapters of the third section cover “Corona Virus–Induced Demyelination,” and the final shorter section has 1 chapter each on “Semliki Forest Virus–Induced Demyelination” and canine distemper virus–induced demyelination.

The chapters are organized with clearly labeled subsections and a consistent outline format that breaks the material into easily read focused segments of information. Rather than organization based on animal species, the editors chose to deal, on a chapter basis, with individual cellular and molecular CNS factors and cellular and molecular elements of the immune system. In some, but not all, chapters, individual species models are broken out and discussed in separate sections. A good example of this is in the chapter “Histopathology of EAE,” in which subsections are devoted to mouse, rat, and primate models. The structure of the book was intended to provide the opportunity to compare parallel chapters dealing with the same factor in different model systems. This is probably a very successful approach for the target audience. The organizational choice may be less successful for those who might be interested in practical characteristics of a single animal model of EAE, but the information is in the book for those willing to seek it out. A useful feature of the book is that in many chapters, the relationship of the animal model to human multiple sclerosis is elucidated with background information on multiple sclerosis, even though the chapter titles do not often indicate this content.

One observation on content is that there is relatively less