



## Get Clarity On Generics

Cost-Effective CT & MRI Contrast Agents



FRESENIUS  
KABI

WATCH VIDEO

# AJNR

## MR Imaging in White Matter Diseases of the Brain and Spinal Cord

*AJNR Am J Neuroradiol* 2006, 27 (8) 1800-1801  
<http://www.ajnr.org/content/27/8/1800>

This information is current as  
of August 26, 2025.

find some of the topics of interest. The book is highly recommended for those using magnetic stimulation in clinical neurophysiology. Both the novice and the more experienced will find the book equally useful.

## BOOK REVIEW

### MR Imaging in White Matter Diseases of the Brain and Spinal Cord

M. Filippi, N. DeStefano, V. Dousset, and J.C. McGowan, eds.  
New York: Springer-Verlag; 2005, 478 pages, 610 illustrations, \$279.

**W**hite matter lesions are ubiquitous and are the most common findings on brain MR imaging. This often leads to a laundry list of differential etiologic possibilities. Consequently, publications that attempt to clarify these findings and add more specificity to the diagnoses are welcome. *MR Imaging in White Matter Diseases of the Brain and Spinal Cord* is a relatively short, multiauthored (55 contributors) book that attempts to bring within a single volume these many diseases and their imaging appearances. In many respects, it succeeds.

The book is long on the general physics of MR and advanced applications of MR (nearly a third of the book) but short on pathologic correlates of most of the diseases illustrated. Many of the diseases described and illustrated would have benefited from inclusion of the pathologic counterparts (either histologic or gross anatomic). I was able to find illustrated pathology in just a few instances: for example in Balo concentric sclerosis; the histology and electron microscopy of the primary angiitis; the histology of 3 grades of gliomas and pleomorphic xanthroastrocytoma. This should not, however, be considered a major drawback of the book; it is mentioned with the hope that future editions of the book will include more of this type of material.

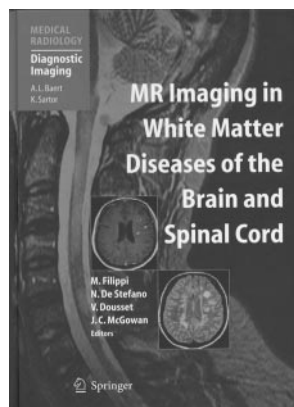
There are 5 major sections in the book: "MR Techniques and Principles," "Disorders of Myelination," "Demyelinating Diseases," "Immune-Mediated Disorders," "White Matter Disorders Related with Aging," and "White Matter Changes Secondary to Other Conditions." Multiple chapters, from 3 to 10, comprise each section.

The first third of the book, contains material on the physics of MR contrast, hardware considerations (magnets, shielding, gradient coils, radiofrequency coils, and so forth), spin-echo and gradient-echo imaging, concepts in fast imaging, magnetization transfer, diffusion imaging, perfusion imaging, functional MR, MR spectroscopy, and high-field MR. Although all of this material is readily available in other textbooks, the authors presumably felt the need to describe these ba-

sic principles for those readers who may have had little to no previous experience with MR. Some of these chapters are more complete than others but, in any event, should serve as basic introductory information.

The strength of the book lies in the clinical imaging and its description. Charles Raybaud, on MR imaging of brain development, describes the problems involved in imaging premature and term infants in addition to presenting sound material on fetal brain imaging and developing/maturation of white matter. This chapter would have been strengthened by more information and illustrations of diffusion-weighted imaging and spectroscopy in infants. "Imaging of Inherited and Acquired Metabolic Brain Disorders," by Mauricio Castillo, is a good survey of these diseases and fortunately contains some spectra obtained in some patients (Canavan disease, adrenoleukodystrophy, Wilson disease). He rightly divides these entities into those associated with head sizes that are normal, enlarged, or small—this is certainly the most logical approach to these diseases, because there are similarities in their white matter abnormalities. Greater in-depth discussion of MR spectroscopy in metabolic disorders is contained in a chapter by Nicola DeStefano and Marzia Mortilla. Although this is a short chapter (12 pages), the reader is exposed to issues other than single voxel technique, such as chemical shift imaging, metabolic maps, and multivoxel analysis in MR spectroscopy. The demyelinating diseases naturally constitute a large part of the book, with, of course, multiple sclerosis (MS) leading the way. MS is discussed in 3 chapters: routine imaging, newer techniques, and variants of MS. Adequate clinical information supplements the imaging features and that helps to bring the MR findings down to clinical realities. Because most MR findings in MS are well known, the chapter by Jack Simon and Bette De Masters is particularly welcome. Here the authors nicely describe some of the historic background to what have been termed MS variants such as Devic, Schilder, Marburg, and Balo concentric sclerosis. The chapter goes a long way in clarifying what these diseases represent and how they present clinically and their MR imaging. It was particularly refreshing that in this chapter, as in some other chapters, radiologists coauthored the material with their clinical counterparts. Neuroradiologists will benefit from the side-by-side presentation of the imaging/clinical/pathologic features of these unusual diseases. Reinforced are a number of facts—such as why it is important from a treatment standpoint to distinguish Devic from MS where there can also be involvement of the cord and optic nerve, what the pathologic difference is between MS and Devic, and how magnetization transfer may potentially be used to distinguish common MS from Devic. In a similar manner the authors describe what the apparent differences are between Marburg disease and acute MS. It is not this reviewer's intent to dwell on this chapter, but it is discussed here because it shows the value of tight neuropathologic correlations, such as what stains and histologic characteristics enable the distinction between differing levels of demyelinating activity. Throughout this chapter, where MS variants are described, the differential diagnoses and the difficulties that arise in these cases are discussed.

In the chapter on acute disseminated encephalomyelitis (ADEM), in addition to describing the imaging and clinical features, the authors do try to come to grips with the issue of whether ADEM is an MS variant or a separate disease entity. This issue is troubling because, as the authors mention, as



many as one third of patients initially diagnosed as having ADEM eventually are diagnosed with MS.

A separate section of the book deals with immune-mediated disorders and their affect on white matter. Included are chapters on primary CNS angiitis, systemic lupus erythematosus, noninflammatory diseases of the CNS, which may affect areas of the brain other than white matter such as Beçhet disease, antiphospholipid antibody syndrome, and Sjogern syndrome. The chapters on the normal aging brain and the ever-present white matter abnormalities in cerebrovascular disease (leukoaraiosis) received special attention; these are clearly important issues, because all interpreters of MR constantly wonder whether the amount of white matter disease is in keeping with the patient's age or reflects some subclinical vascular disease. Other subjects covered well include chapters on viral diseases in immunocompetent and immunocompromised patients, white matter changes in neoplastic disease (which incidentally includes examples of multi-voxel magnetic resonance spectroscopy to show metabolic alterations in surrounding white matter, in addition to demonstrating perfusion MR and functional MR). Head trauma and psychiatric disorders round out the book.

In summary, this text brings under one roof the imaging concepts involved in evaluating white matter disease. It successfully integrates clinical and imaging information and can, for that reason, be recommended as a reference text for a departmental library.

## BOOK REVIEW

### Neuroblastoma: Pediatric Oncology

N.-K.V. Cheung and S.L. Cohn, eds. Heidelberg: Springer-Verlag; 2005, 298 pages, 51 illustrations, 48 tables, \$129.

The "medical enigma" of neuroblastoma, a childhood neoplasm arising from neural crest elements and accounting for approximately 7% of all cancers in children younger than 15 years of age, challenges pediatric oncologists to tackle the genetics, biologic behavior, and the diverse (sometimes unpredictable) clinical course of this disorder. Cheung and Cohn have organized the contributions of an extensive list of pre-eminent researchers and clinicians specializing in neuroblastoma into a concise but information-packed text.

The highly detailed table of contents that opens the volume enables the reader needing specific information to locate accurate and detailed text relevant to an area of concern quickly and precisely.

Beginning with the epidemiology, and various screening methods that were used internationally and subsequently abandoned, the first 2 chapters provide a historical and societal framework in which the reader can understand the impact this

disorder—and screening programs—have had on many industrialized nations. Chapters discussing the complex genetics and molecular cytogenetics of neuroblastoma follow. These are well written and make the complicated subject matter easy to understand. Similarly, the next 2 chapters on molecular and developmental biology and cellular heterogeneity are comprehensive and well written. Chapters on the molecular and developmental biology and cellular heterogeneity outline the unusual biologic behavior of these lesions, including a concise review of neural crest cellular lineage and relevant signaling molecules.

Chapter 7 begins the most relevant of the chapters for the practicing neuroradiologist—specifically, clinical presentation—followed by chapters detailing the macroscopic, microscopic, and molecular pathology of neuroblastoma and related tumors, including the various forms of ganglioneuroblastoma and ganglioneuroma.

The anatomic and functional imaging section (chapter 10) reviews the imaging features and current imaging practice for optimal diagnosis and follow-up of neuroblastoma patients. Tables 10.1 and 10.2 detailing the radiation doses, oral and intravenous contrast administration recommendations, and sedation/general anesthesia required for CT scanning should be considered "guidelines" at best, and readers should refer to their institutions, policies, particularly regarding radiation doses, methods of contrast administration, NPO times, and sedation practices. Table 10.3, which highlights the suggested MR imaging techniques for evaluation of these children, is confusing, as is Table 10.4, which describes the scanning principles and scan techniques for technetium-Tc99 m bone scintigraphy. Appropriately, more emphasis is placed on the section regarding metaiodobenzylguanidine scintigraphy, the highly specific scan for the detection of neuroblastoma in the pediatric patient.

The remainder of the text focuses on the treatment of neuroblastoma. The best of these chapters (chapter 11) includes multiple subsections detailing the current chemotherapy and radiation treatment options for low-, intermediate-, and high-risk neuroblastoma, as well as the unusually behaving stage-4S disease. For radiologists who image these children, familiarity with the various treatment regimens and their common complications is crucial. The most commonly used surgical approaches are nicely outlined in a series of schematic drawings, which can also aid radiologists who interpret the postoperative images in these children.

The final chapter, which would be expected to be of particular interest to the practicing or training neuroradiologist, addresses the management of neurologic complications. These include direct spinal canal involvement from retroperitoneal lesions and hematogenous dissemination to the central nervous system. Perhaps the most unusual, though, is the opsoclonus-myoclonus syndromes, also known as Kinsbourne syndrome, a neurobehavioral paraneoplastic syndrome seen in fewer than 4% of all neuroblastoma patients.

Overall this is a well-written, authoritative text on neuroblastoma and related disorders. The reader searching for a specific piece of information should readily find it via the detailed index of content and the plethora of informative tables and figures. Although this would make an excellent addition to the library of an academic neuroradiology or pediatric radiology department, the average practicing radiologist would have very limited need for this highly specialized monograph.

