



## Get Clarity On Generics

Cost-Effective CT & MRI Contrast Agents



FRESENIUS  
KABI

WATCH VIDEO

# AJNR

## Atlas of Sleep Medicine

*AJNR Am J Neuroradiol* 2006, 27 (3) 722-723  
<http://www.ajnr.org/content/27/3/722.2>

This information is current as  
of August 3, 2025.

## BOOK REVIEW

### Status Epilepticus: A Clinical Perspective

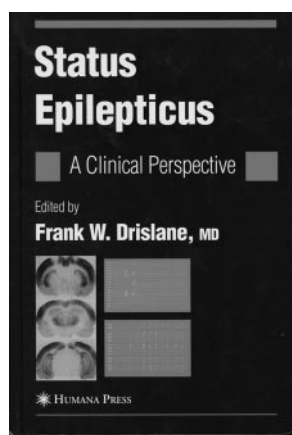
Edited by F.W. Drislane. New York: Humana Press; 2005, \$99.50.

**S**tatus epilepticus is an important clinical problem that is common and associated with significant morbidity and mortality. A growing body of literature focusing on both clinical and experimental issues attests to the significance of status epilepticus and its potential for brain injury. There is thus a need to synthesize more recent developments into a single volume. For these reasons, the inclusion of this book in a series of reviews on neurologic disorders within the *Current Clinical Neurology* series is welcome news.

Let me be clear from the start, however, in saying that the book is explicitly oriented toward treating neurologists, not radiologists. Although it covers a range of subjects across a wide clinical spectrum, including the diagnosis, epidemiology, clinical presentations, and treatment of status epilepticus, no chapters are dedicated to neuroimaging. Additional chapters are devoted to age-related differences in status epilepticus in children and neonates, and, though there is some coverage of basic mechanisms and the histopathology, these chapters appear to round out the clinical chapters and do not provide in-depth discussions.

These qualifications aside, the book does an admirable job of describing the clinical features of status epilepticus. The differential diagnosis of convulsive and nonconvulsive forms of status epilepticus are described clearly, and the reader is guided through the list of conditions that may imitate status epilepticus. Chapter 4, which covers the epidemiology of status epilepticus, is particularly well done. It comprehensively and logically examines the entire set of variables associated with status epilepticus and is data driven. The chapter on the electroencephalogram is all well thought out and provides clear description of electroencephalographic (EEG) abnormalities. Although the figures are clear, they are small and somewhat difficult to read. The figure legends provide appropriate description.

Other strengths of the book include a comprehensive reference list and the inclusion of a chapter on historical perspective to complement the current clinical literature. I found the historical annotations, which illustrate the integration of status epilepticus into the realm of general clinical medicine, particularly interesting. The liberal use of tables throughout the book greatly assists the reader in organizing the information contained in the text. The table of contents is logically subdivided into introductory topics, clinical presentations, basic mechanisms, and treatment. The references



supplied at the end of each chapter are comprehensive, and the final index is easy to use.

One of the book's major drawbacks is its redundancy. Epidemiologic data are repeated in the chapter on generalized tonic-clonic status, the classification of status epilepticus is reiterated in the chapter on nonconvulsive status epilepticus, and EEG classification is presented in both the EEG and classification chapters. The only neuroimaging figure, on page 152, depicts serial single-photon emission tomographic images in a patient with status epilepticus that reveal an area of hyperperfusion that subsequently resolves. The image quality is poor and will surely disappoint neuroradiologists accustomed to more enhanced resolution.

In summary, this volume is recommended primarily for clinicians, and it is doubtful that radiologists will find much to take away. Although it is well written, well referenced, and easy to use, its adherence to clinical data makes it more suitable for physicians who are treatment oriented.

## BOOK REVIEW


### Atlas of Sleep Medicine

Edited by Sudhansu Chokroverty, Robert J. Thomas, and Meeta Bhatt. Philadelphia: Elsevier Butterworth Heinemann; 2005, \$95.

**T**he atlas is a substantial work of some 15 contributors that provides examples of clinical sleep recordings and also illustrates techniques used to evaluate sleep and sleep disorders. As the title implies, the work is essentially a collection of data displays from sleep recordings with accompanying explanatory text. In that sense, it is more like an organized album of interesting graphic findings along with descriptions and clinical correlations. As expected, the authors provide abundant examples of polysomnography and other sleep-recorded data. The material is reasonably laid out and logically organized. I found the listed price reasonable at \$95. Readers who have some familiarity with sleep-recording techniques and the format of related data displays are likely to find the material more understandable than those who are new at looking at such representations.

The accompanying text of the atlas for the most part is authoritative and well prepared. In a work of this kind, there is understandably some unevenness of style. Some page numbers are not shown, but the corresponding figures are numbered.

The bibliography for some chapters is limited to a few entries, including some of the author's own articles, but other chapter bibliographies are more extensive. I found the index to be well prepared and useful. Unfortunately, the abbreviations table before the first chapter does not include abbreviations used elsewhere in the book. An example is the trade marked



acronym BiPAP, used for a commonly employed bi-level nasal positive airway–pressure device.

There are also informative sections on actigraphy, pulse transit time, and peripheral arterial tonometry, as well as periodic limb movements, restless legs syndrome, and other movement disorders of sleep. There is relatively little to be found in the volume on REM behavior disorder or other nocturnal behaviors. There is some scattered information and a few examples of insomnia cases but no single chapter related to this common sleep disorder. This is perhaps understandable, because the techniques presented are of greater value in the diagnosis and treatment of sleep-related breathing problems. There is only a short reference to nocturnal penile tumescence studies somewhat obscurely included under recording techniques and apparently to indicate that the procedure is not typically employed in the principal author's laboratory. The chapter on special recording considerations and illustrative cases for pediatric sleep disorders is informative.

Most of the images in the atlas are of good quality. Some legends for the illustrations provide clear explanations. In general, illustrations are not marked with arrows or other indicators that identify the particular abnormalities or areas of interest. Many figures have other numbers or letters that may be misleading for the novice reader or those less familiar with their significance. The scales are barely readable on some of the illustrations. Some legends are conjectural or inconclusive and may leave the reader unsure of what the example is meant to illustrate.

Despite the title, the atlas is more of an introduction with illustrations and brief explanations than a comprehensive guide to treatment of sleep disorders and sleep medicine. There are other similar works extant. These include the older *Primer of Polysomnogram Interpretation*, by Mark Pressman (Butterworth-Heinemann; 2002), and the *Atlas of Digital Polysomnography*, by James D. Geyer (Lippincott Williams & Wilkins; 2000). The somewhat older and more expensive set of 2 volumes entitled *Atlas of Clinical Polysomnography*, by Nic Butkov, contains hundreds of fine illustrations of recorded sleep data and supporting text. *Principles and Practice of Sleep Medicine*, 3rd ed., edited by Meir H. Kryger, Thomas Roth, and William C. Dement (Saunders; 2000) is an outstanding comprehensive reference, but not an atlas.

Because visual recognition of recorded data takes some experience and practice, novices may find the experience of looking at many of the illustrations in this atlas somewhat akin to the uninitiated looking at axial tomographic sections. Individuals who are used to looking at recorded sleep data will find the illustrations more familiar than those who are not. Particularly the section on hypnogram analysis (153–70) may seem obscure to someone who is not used to looking at this form of graphic representation even with the clinical correlation.

It is a bit of a reach to see how most neuroradiologists would use this book. It is certainly fair to say that anyone involved in conscious sedation should be aware of the high prevalence of sleep-related breathing disorders, not only in the general population but especially in the subjects who may be presenting for neuroradiologic procedures. Neuroradiologists may frequently encounter hypertensive, obese, and morbidly obese subjects who may perhaps be undergoing imaging for commonly associated cerebrovascular, spinal, or other clinical

problems. These individuals have a much higher prevalence of sleep apnea than the general population. We now know that sleep apnea may affect as many as 30%–40% of stroke patients. An atlas of this type is probably not essential for bringing home these realities. The book may be helpful to gain a better appreciation of the limitations of sleep recording in relation to various imaging studies. The usual techniques of sleep recording, for instance, would not be well suited to a typical MR imaging suite. There is, however, a good section by Dr. Robert Thomas in the atlas on the use of positive airway pressure in sleep apnea subjects. This may help one better understand these commonly used devices and their role, and perhaps use, in patients receiving conscious sedation or otherwise sleeping during neuroradiology procedures.

In a more general sense, the present volume will perhaps find its greatest usefulness for those readers who are looking for illustrations of common, as well as uncommon, findings in sleep recording. Polysomnographic technologists, sleep specialists, and others needing examples and explanations of the evaluation of sleep by these recording techniques should find the work of interest. The book would be worthwhile for individuals studying for certification by the American Board of Sleep Medicine. The work would also be well chosen for a course on evaluation and interpretation of sleep recordings. The book may also be of interest for those who only wish to learn what sleep recordings look like and the information they can provide. In that capacity, the book would serve as a useful reference for medical libraries and sleep disorders centers.

## BOOK REVIEW

### Pediatric Brain and Spine: An Atlas of MRI and Spectroscopy

Edited by L.M. Ketonen, A. Hiwatashi, R. Sidhu, and P.L. Westesson. New York: Springer-Verlag; 2005, 494 pages, 1427 illustrations, \$239.

This MR imaging atlas is a comprehensive outline of pediatric brain and spine imaging, including modern techniques such as MR spectroscopy written by experienced North American authors. The book is divided into 12 chapters. Most

of the chapters pertain to brain imaging, with added chapters on spine, head and neck, and fetal imaging. The description of each condition is well integrated into clinical presentation, imaging, and discussion, followed by recent and appropriate references. The book starts with a chapter on imaging of normal brain myelination and variants. In this chapter, brain myelination at various ages is accompanied by high-quality im-

