



Providing Choice & Value
Generic CT and MRI Contrast Agents



CONTACT REP

AJNR

2006: A Stroke Odyssey

Thomas A. Tomsick

AJNR Am J Neuroradiol 2006, 27 (10) 2019-2021
<http://www.ajnr.org/content/27/10/2019>

This information is current as
of July 25, 2025.

2006: A Stroke Odyssey

The Interventional Management of Stroke (IMS) III Study for acute ischemic stroke, a clinical trial funded by the National Institutes of Health (NIH), is about to begin. The purpose of IMS III is to determine if clinical outcomes achieved with standard intravenous (IV) recombinant tissue plasminogen activator (rtPA) treatment can be improved with a reduced dose of IV rtPA plus a more aggressive intra-arterial (IA) revascularization approach. Nine hundred forty subjects younger than 81 years, NIH Stroke Scale (NIHSS) score of ≥ 10 , will be randomized to either standard IV rtPA or reduced-dose IV rtPA, followed by arteriography and IA revascularization treatment if an eligible occlusion is identified. The IA arm will be treated by standard microcatheter thrombolysis (supplied by Cordis Neurovascular, Miami Lakes, Fla), thrombolysis assisted by EKOS ultrasound microcatheter (EKOS Corporation, Bothell, Wash), or thrombus removal by using the Merci Retriever Device (Concentric Medical, Mountain View, Calif),¹ with or without adjunctive IA rtPA. New devices/paradigms may be added as new devices are tested outside the trial. The study is not designed or powered to determine which IA device or paradigm is best.

Arriving at this phase III pivotal trial has been a 20-year odyssey, beginning with National Institute for Neurologic Disorders and Stroke (NINDS) pilot trial in 1987–1989, followed by the NINDS rtPA Stroke Trial, the Emergency Management of Stroke Study (EMS) of 1994–2005, a post-EMS/Pre-IMS experience in Cincinnati from 1997–2000, the IMS I Trial of 2001, and IMS II of 2003–2006. This review will emphasize the important observations from these studies that have shaped the current treatment paradigm.

In the NINDS pilot trial, subjects were treated in a dose-escalation fashion, and several important observations were made.^{2,3} The revascularization response of occlusion to IV rtPA in the pilot trial was relatively poor. Of 55 subjects in Cincinnati, 38 underwent angiography within 2 days of stroke treatment. Eighteen subjects exhibited the hyperattenuated middle cerebral artery sign, and all had NIHSS score of ≥ 10 . Fourteen of these 18 subjects had cerebral angiography within 2 days of stroke, and all still exhibited middle cerebral artery occlusion, indicative of relatively poor recanalization, or recanalization with rethrombosis, of large-vessel occlusions after IV rtPA at the doses used. Of the 19 patients with an NIHSS score of < 10 , patients typically had normal findings on follow-up angiograms or distal or recanalizing emboli.⁴ In addition, subjects with an NIHSS score of < 10 typically had infarcts of smaller volume and enjoyed better outcomes than those with scores of ≥ 10 . Furthermore, the NINDS pilot trial suggested no optimal dose of rtPA, and the dose of 0.9 mg/kg was chosen for the phase III study because symptomatic intracerebral hemorrhage occurred only above that dose. The implications of the ability of rtPA to open smaller peripheral vessels and lead to generally good outcomes while failing to

open many larger vessel occlusions, typically associated with less complete recoveries, seemed quite clear.

Concurrently with analysis of the pilot data, Zeumer et al⁵ reported successful IA rtPA therapy, suggesting better recanalization rates with IA therapy, with acceptable clinical outcomes, at infusion rates of 10 mg/h or greater. It was tantalizing to hypothesize that combining IV with IA treatment might optimize thrombolytic outcomes and even to envision that devices might be used to fragment, displace, recanalize, or remove the clots.⁶ Target Therapeutics even prototyped a nitinol corkscrew clot fragmentation and retrieval wire designed specifically for this purpose.

To preliminarily study the safety of combination IV/IA rtPA therapy, the EMS Trial (T. Brott, principal investigator) randomized 35 subjects to reduced-dose IV rtPA (0.6 mg/kg, 10% bolus) or to IV placebo, followed by arteriography and IA treatment if a clot was present with up to 20 mg IA rtPA during 2 hours. No eligible arterial occlusions were demonstrated in 45% of subjects with NIHSS scores of < 10 ; 79% of subjects with ≥ 10 ; and 100% with > 14 , irrespective of prior IV rtPA or placebo, who exhibited treatable occlusions. The treatment paradigm seemed safe, with no excessive intracerebral hemorrhage. IA treatment was administered at an average of 4.2 hours. Globally, combined IV and IA therapy appeared to offer better thrombolysis than IA-only therapy. What is more important, good outcomes in 10 of 15 (66%) M1 and M2 occlusions treated with IA rtPA, irrespective of prior IV rtPA or placebo administration, raise the question whether IA treatment might even equal IV plus IA rtPA treatment in some patients when applied in a very timely fashion.⁷

At the time that EMS was ending, the NINDS rtPA trial was reported, confirming the benefit of IV rtPA.⁸ Notably, the odds ratio of excellent outcome ranged from approximately 1.4 for an NIHSS score of < 10 to 5.3 for an NIHSS score of > 20 with IV therapy. Unfortunately, excellent outcomes were uncommon (8%) in treated patients with NIHSS scores of > 20 and rare in controls (1.5%). Again, this focused the IMS study group on subjects with larger deficits, likely to have treatable occlusions, with potentially greater benefit with treatment. Subsequently, the Prolyse in Acute Cerebral Thromboembolism (PROACT II) Study was reported, offering further proof of the principle of IA therapy for subjects with NIHSS scores of ≥ 10 , even in a delayed fashion.⁹

A phase II study seemed indicated to begin to confirm safety and potential efficacy and to identify treatment subgroups, and we began designing and planning its submission. We wondered how to proceed, with some evidence of safety and potential efficacy, yet with an unproven therapy that might be applicable to a devastated population. We addressed this Scylla and Charybdis issue locally by counseling families and patients with large neurologic deficits that they could receive the standard therapy but that it may not be adequate, and we explained the potential suggested by the EMS trial, offering them combined IV/IA treatment in an off-label fashion.

Members of the Greater Cincinnati and Northern Kentucky Stroke Team treated 62 patients in this manner between 1979 and 2000 and continued our enthusiasm about its potential in selected patients with NIHSS scores of ≥ 10 .¹⁰ Of 54 younger patients less than 81 years of age, good modified Rankin scale 0–2 outcomes were achieved in 56%, compared with 37% in a histor-

Presented as the Luessenhop Lecture at the joint meeting American Society of Interventional & Therapeutic Neuroradiology/Society for Clinical Vascular Surgery, Orlando, Fla, February 20, 2006.

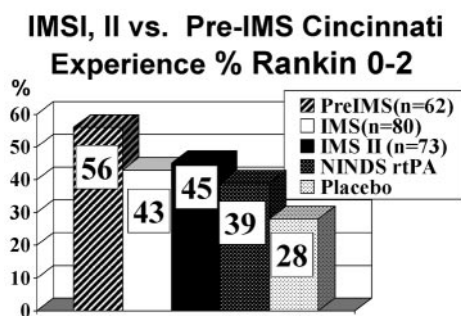


Fig 1. Modified Rankin scale 0–2 outcomes in pre-IMS, IMS I, and IMS II compared with historical control of NINDS study rtPA and placebo control groups. Time to IV treatment was significantly earlier in the NINDS rtPA trial (108 minutes) compared with that in the 3 IV/IA treatment groups (126, 139, 140 minutes).

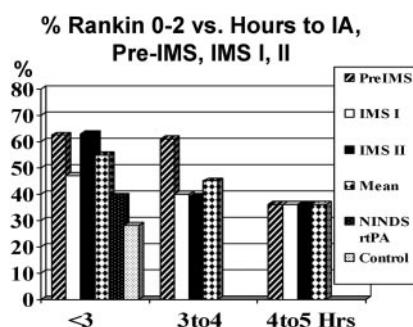


Fig 2. Percentage modified Rankin scale 0–2 compared with onset to IA rtPA bolus (following reduced-dose IV therapy). A trend toward better outcomes with earlier therapy is demonstrated. No difference of post-IV IA therapy begun at 4–5 hours, compared with IV therapy (NINDS rtPA), is also shown. In IMS I and II, IA therapy began within 5 hours.

Baseline NIHSS vs. % Rankin 0-2 NINDS vs. IV/IA

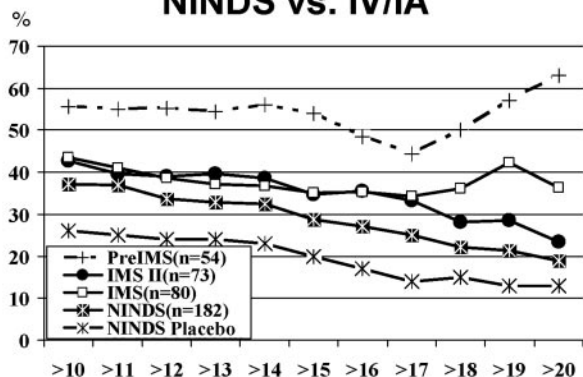


Fig 3. Percentage modified Rankin scale 0–2 versus baseline NIHSS score. Improved outcomes at higher NIHSS scores in pre-IMS and IMS I are achieved.

ical control of the treated group in the NINDS trial of similar age and NIHSS scores and with 28% in the NINDS control group (Fig. 1). This dramatic difference was achieved with a median time to IV treatment of 126 minutes (compared with the NINDS trial median of 108 minutes), in addition to a mean time to IA treatment of 3.5 hours. A strong trend for better outcomes with earlier treatment was obvious (Fig 2). In addition, the larger the neurologic deficit, the greater the benefit achieved (Fig 3). Death and intracerebral hemorrhage were more frequent in 8 patients older than 80 years of age, with only 1 good outcome.

Subsequently, 80 subjects were entered into the IMS I trial (J. Broderick, principal investigator), by using a similar IV/IA paradigm, between January and October 2001 in 13 centers in North America.¹¹ Clinical outcomes were again better, compared with historical control, but not as good as we had expected on the basis of our local registry data (Fig 1). Certainly less careful patient selection might have impacted IMS I results, but other factors may have contributed. Although time to IA therapy was near identical (210 versus 212 minutes), we had achieved earlier time to IV treatment in our pre-IMS series (126 versus 140 minutes). Were there other differences? None were immediately obvious.

IMS I was completed well ahead of schedule, but the budget had not yet been exhausted. So we looked around for some way to further our knowledge within the IV/IA paradigm, perhaps incorporating a device as we had earlier anticipated, while we applied for funding for a phase III trial randomizing to IV and IV/IA treatment. Only 1 device had successfully gone through a feasibility or pilot trial with apparent safety and promising clinical results, the EKOS MicroLysUS sonography catheter (Ekos Corporation).¹² With NIH and US Food and Drug Administration support and approval, we initiated IMS II in January 2003, with 73 subjects entered by April 2005 (J. Broderick, principal investigator).

As reported at the International Stroke Conference on February 17, 2006, IMS II achieved better outcomes than IMS I but still not as good as the pre-IMS expectations (Fig 1).¹³ Revascularization rates appeared to be better with the EKOS Microcatheter on the basis of a number of study measures, as well as on historical comparison with a dataset from IMS I. Retrospective analysis of temperature decreases at the catheter tip promised to predict identifiable cooling caused by the inflow of reperfusion. Symptomatic intracerebral hemorrhage, the Achilles heel of thrombolytic therapy, was nonsignificantly increased in IMS II compared with IMS I, 11% compared with 6.3%. Time to IV treatment was similar to that in IMS I, but median IA treatment was 28 minutes slower than that in IMS I.

The higher symptomatic intracerebral hemorrhage and parenchymal hematoma rate early in IMS II raised questions about safety issues regarding the study paradigm. Was there a Trojan horse effect, a danger lurking behind apparent success? It had been incidentally noted in IMS I that contrast extravasation into the brain and parenchymal hematoma¹⁴ seemed more common than we were accustomed to identifying in our pre-IMS experience. This raised the question of some hidden difference in technical performance factor that might contribute to contrast extravasation and intracerebral hemorrhage. It had also been noted on angiography review that microcatheter contrast injections were also more common in IMS I than we were accustomed to using in our pre-IMS experience. Could there be a link, then, between microcatheter contrast injections, contrast extravasation, and intracerebral hemorrhage? A case-by-case analysis of contrast extravasation and intracerebral hemorrhage in IMS I was then performed, confirming this relationship. Interventionists were notified about this observation during the ongoing IMS II study. Microcatheter contrast injections in IMS II decreased after this notification. An analysis by Khatri et al¹⁵ of IMS I and II cases further confirmed a relationship between microcatheter contrast injections, contrast extravasation, and intracerebral hemorrhage.

rhage. A relationship with symptomatic intracerebral hemorrhage was not confirmed, but the number of symptomatic intracerebral hemorrhages was relatively low.

Could the pattern of microcatheter contrast injection use also contribute to the difference in clinical outcomes we experienced between our pre-IMS data and IMS I-II? Khatri and I performed a retrospective review of local registry cases. We identified a total of 84 nonstudy patients for review and found that those included in the pre-IMS registry had less contrast extravasation, fewer intracerebral hemorrhages, and fewer microcatheter injections than the IMS I and II subjects. Furthermore, a strong relationship was found between microcatheter injections and contrast extravasation, as well as between both intracerebral hemorrhage and parenchymal hematoma. Microcatheter contrast injections seemed to cause more contrast extravasation in IV/IA cases than in IA-only cases. This laocoonic warning regarding the hidden risks of microcatheter contrast injections then seems substantiated for the IV/IA setting. Our number of IA-only cases was too small to make further definitive observations.

We also examined other technical factors that might contribute to poorer outcomes, in addition to slower IV therapy and more frequent microcatheter injections. Just as it had not been our practice to perform microcatheter contrast injections routinely, it was also not yet our practice to perform aggressive microcatheter/microguidewire manipulation for occlusions, including T occlusion, during that earlier pre-IMS time period. We examined the 25 internal carotid artery T occlusions from IMS I and II and could document at least a 15% incidence of new anterior cerebral artery emboli and a 32% incidence of anterior cerebral artery region infarction, following IA treatment (S. King, personal communication, 2006). Of interest, there was a difference ($P < .05$) in anterior cerebral artery emboli between subjects treated with EKOS sonography, in which no microcatheter or microguidewire manipulation was allowed, and standard microcatheter thrombolysis, in which clot manipulation was allowed every 15 minutes. This suggests the aggressive microcatheter guidewire manipulations with subsequent anterior cerebral artery emboli may have unexpected deleterious effects by causing anterior cerebral artery–distribution infarct or by decreasing important anterior cerebral artery collateral flow in patients who recanalize incompletely. The balance between an increased recanalization benefit and secondary harm may be delicate.

These latter observation regarding microcatheter injection, intracerebral hemorrhage risks, and procedural emboli should make interventionists question the predictability of their actions and device use. Haphazard random outcomes and results (eg, stray beads with arteriovenous malformation embolization) are unacceptable in the current interventional climate. Interventionists and industry have refined their tools and should expect action A to lead to result A, with departures primarily due to biologic heterogeneity and limitation, not device/maneuver result unpredictably. When no alternative to a potentially beneficial but unpredictable and perhaps harmful action exists in a “hopeless” situation, the action may be supportable. When an alternative to an action with predictable, albeit less-than-optimal, results exists, there must be evidence that the alternative action itself causes more good than harm, on balance. Otherwise, the alternative action becomes an experiment in itself and has no place in an interventional trial, such as IMS III or any similar trial.

Socrates advised, “gnotheis auton” or “Know thyself.” A corollary might be “Know when you don’t know,” when it comes to study subject care. I would like to carry it a bit further and suggest, “No, when you don’t know.” If you do not know the likelihood of your action to tip some delicate balance adversely, perhaps it should not be undertaken in a study setting or even in daily practice.

Will IMS III prove more a aggressive timely intervention that is better than standard therapy for selected patients? Time will tell. However, standard therapy itself may change, even within the time scope of this trial. Neuroprotectants may become available to be used in conjunction with IV rTPA, and consideration for some method of inclusion into the study will be mandatory.¹⁶ Transcranial sonography may become a standard adjunct to IV therapy as well. Drug-impregnated bubbles may amplify effects of digital transcranial Doppler sonography. New devices such as other removal devices, balloon catheters, and stents may also succeed in pilot trials, with the need to consider including them in the study. Irrespective of final outcome, I hope the IMS investigators group may become just the vehicle needed to maintain an active battle-ready group of investigators able to move more nimbly in the future in investigating new treatment paradigms.

References

- Smith W, Sung G, Starkman S, et al. Safety and efficacy of mechanical embolectomy in acute ischemic stroke: results of the MERCI trial. *Stroke* 2005;36:1432–40
- Haley EC, Levy DE, Brott TG, et al. Urgent therapy for stroke. Part II. Pilot study of tissue plasminogen activator administered 91–180 minutes from onset. *Stroke* 1992;23:641–45
- Brott TG, Haley EC, Levy DE, et al. Urgent therapy for stroke. Part I. Pilot study of tissue plasminogen activator administered within 90 minutes. *Stroke* 1992;23:632–40
- Tomsick T, Brott T, Barsan W, et al. Prognostic value of the hyperdense middle cerebral artery sign and stroke scale score before ultra-early thrombolytic therapy. *AJNR Am J Neuroradiol* 1996;17:79–85
- Zeumer H, Freitag HJ, Zanella F, et al. Local intra-arterial fibrinolytic therapy in patients with stroke: urokinase versus recombinant tissue plasminogen activator (r-TPA). *Neuroradiology* 1993;35:159–62
- Tomsick TA. Sensitivity and prognostic value of early CT in occlusion of the middle cerebral artery trunk. *AJNR Am J Neuroradiol* 1994;15:16–18
- Lewandowski C, Frankel M, Tomsick T, et al, and the EMS Bridging Trial Investigators. Combined intravenous and intra-arterial r-tPA versus intra-arterial therapy of acute ischemic stroke: Emergency Management of Stroke (EMS) Bridging Trial. *Stroke* 1999;30:2598–605
- The NINDS rt-PA Stroke Study Group. Tissue plasminogen activator for acute ischemic stroke. *N Engl J Med* 1995;333:1581–87
- Furlan A, Higashida R, Weschler L, et al. Intra-arterial prourokinase for acute ischemic stroke: The PROACT II Study—a randomized controlled trial, Prolyse in Acute Cerebral Thromboembolism. *JAMA* 1999;282:2003–11
- Flaherty ML, Woo D, Kissells B, et al. Combined IV and intra-arterial thrombolysis for acute ischemic stroke. *Neurology* 2005;64:386–88
- The IMS investigators. Combined intravenous and intraarterial recanalization for acute ischemic stroke: the interventional management of stroke study. *Stroke* 2004;35:904–12
- Mahon BR, Nesbit GM, Barnwell SL, et al. North American clinical experience with the EKOS MicroLysUS infusion catheter for the treatment of stroke. *AJNR Am J Neuroradiol* 2003;24:534–38
- IMS II investigators. Preliminary results of IMS II Trial [abstract]. *Stroke* 2006;37:708
- Berger C, Fiorelli M, Steiner T, et al. Hemorrhagic transformation of ischemic brain tissue: asymptomatic or symptomatic? *Stroke* 2001;32:1330–35
- Khatri P, Broderick JP, Khoury J, et al. Microcatheter contrast injections during intra-arterial thrombolysis increase intracranial hemorrhage risk [abstract]. *Stroke* 2006;37:622
- Lees KR, Zivin JA, Ashwood T, et al. NXY-059 for acute ischemic stroke. *N Engl J Med* 2006;354:588–600

Thomas A. Tomsick, MD, FACR.
University of Cincinnati
Cincinnati, Ohio